

Treatment of a symptomatic cervical cerebrospinal fluid fistula after full endoscopic cervical foraminotomy with CT-guided epidural fibrin patch

Stefan Motov, Bastian Stemmer, Philipp Emanuel Krauss, Christoph Maurer, Ehab Shiban

Angaben zur Veröffentlichung / Publication details:

Motov, Stefan, Bastian Stemmer, Philipp Emanuel Krauss, Christoph Maurer, and Ehab Shiban. 2024. "Treatment of a symptomatic cervical cerebrospinal fluid fistula after full endoscopic cervical foraminotomy with CT-guided epidural fibrin patch." *European Spine Journal* 33: 3124–28. <https://doi.org/10.1007/s00586-023-07973-1>.



Treatment of a symptomatic cervical cerebrospinal fluid fistula after full endoscopic cervical foraminotomy with CT-guided epidural fibrin patch

Stefan Motov^{1,2} · B. Stemmer² · P. Krauss² · C. Maurer³ · E. Shiban²

Received: 29 December 2022 / Revised: 6 September 2023 / Accepted: 24 September 2023 / Published online: 7 October 2023
© The Author(s) 2023

Abstract

Background There is only limited data on the management of cerebrospinal fluid (CSF) fistulas after cervical endoscopic spine surgery. We investigated the current literature for treatment options and present a case of a patient who was treated with CT-guided epidural fibrin patch.

Methods We present the case of a 47-year-old female patient with a suspected CSF fistula after endoscopic decompression for C7 foraminal stenosis. She was readmitted 8 days after surgery with dysesthesia in both upper extremities, orthostatic headache and neck pain, which worsened during mobilization. A CSF leak was suspected on spinal magnetic resonance imaging. A computer tomography (CT)-guided epidural blood patch was performed with short-term relief. A second CT-guided epidural fibrin patch was executed and the patient improved thereafter and was discharged at home without sensorimotor deficits or sequelae. We investigated the current literature for complications after endoscopic spine surgery and for treatment of postoperative CSF fistulas.

Results Although endoscopic and open revision surgery with dura repair were described in previous studies, dural tears in endoscopic surgery are frequently treated conservatively. In our case, the patient was severely impaired by a persistent CSF fistula. We opted for a less invasive treatment and performed a CT-guided fibrin patch which resulted in a complete resolution of patient's symptoms.

Discussion and conclusion CSF fistulas after cervical endoscopic spine procedures are rare complications. Conservative treatment or revision surgery are the standard of care. CT-guided epidural fibrin patch was an efficient and less invasive option in our case.

Keywords CSF fistula · Endoscopic spine surgery · Cervical foraminotomy · Intervention · CT-guided fibrin patch

Introduction

CSF fistulas after endoscopic spine surgery are rare complications, which can be difficult to treat and result in severe symptom burden, while there are little reports on occurrence

and standard of treatment [6]. In lumbar spinal endoscopic procedures, the incidence reported ranges from 1 to 4% [6, 7]. Dural sac injury in endoscopic interlaminar approaches might occur due to dural tear during insertion of the working tube, which mostly originates from small defects and can be successfully closed with sealants [7]. However, some authors recommend a conversion to open dural repair in extensive durotomies with prolapsing rootlets [3, 4]. There is scarce information about management of CSF fistulas and pseudomeningoceles after posterior endoscopic cervical foraminotomy. We present the case of a patient suffering from a CSF fistula after endoscopic foraminotomy and successful management with CT-guided epidural fibrin patch.

✉ Stefan Motov
stefanmotov@yahoo.de; stefan.motov@kssg.ch

¹ Klinik Für Neurochirurgie, Kantonsspital St. Gallen, Rorschacher Strasse 95, CH-9007 St. Gallen, Switzerland

² Present Address: Klinik Für Neurochirurgie, Universitaetsklinik Augsburg, Augsburg, Germany

³ Klinik Für Diagnostische Und Interventionelle Radiologie Und Neuroradiologie, Universitaetsklinik Augsburg, Augsburg, Germany

Case report

A 47-year-old female patient was presented in the outpatient clinic of the neurosurgical department at the university hospital of Augsburg after a previous cervical spine trauma 7 years prior to admission. Since then, she suffered of a numbness in the index and middle fingers of the left hand with an acute exacerbation of radiating pain in the left shoulder blade, the ventrolateral upper and medial forearm up extending to the wrist on the left side with a tingling paresthesia of the middle and ring fingers of the left hand corresponding to a C7 radiculopathy for several weeks. Conservative treatment including oral opioid and analgesic pain medication and facet joint infiltration could not deliver sufficient pain relief. Current MRI of the cervical spine (Fig. 1) revealed cervical spondylosis at the level of C6/C7 with left-sided paramedian disk herniation and consecutive foraminal stenosis.

After confirmation via a left-sided fluoroscopy-guided C7 periradicular injection, that rendered the patient 80% pain-free for 24 h, an endoscopic cervical foraminotomy was advised. The procedure lasted 68 min and was executed with a 6.9 mm CESSYS endoscope (Fig. 2) without any noticeable complications. The radicular pain symptoms resolved immediately completely after surgery. The patient stated only a mild left-sided C7 hypesthesia. We discharged her at home on the 1st postoperative day after an uneventful course of treatment. She presented on the 8th postoperative day to the emergency department with tingling dysesthesia in both upper extremities as well as orthostatic headache and neck pain, which started a few days after the procedure and accentuated and intensified with standing and walking, rendering her immobile. The wound was dry and with no signs of irritation, and there were no elevated inflammation blood markers. A cervical MRI was performed, which revealed a significant decompression of the left-sided C7 neuroforamen, and a liquid collection in the muscle fascia suspected to be a

Fig. 1 Cervical MRI on initial presentation with left-sided C7 foraminal stenosis

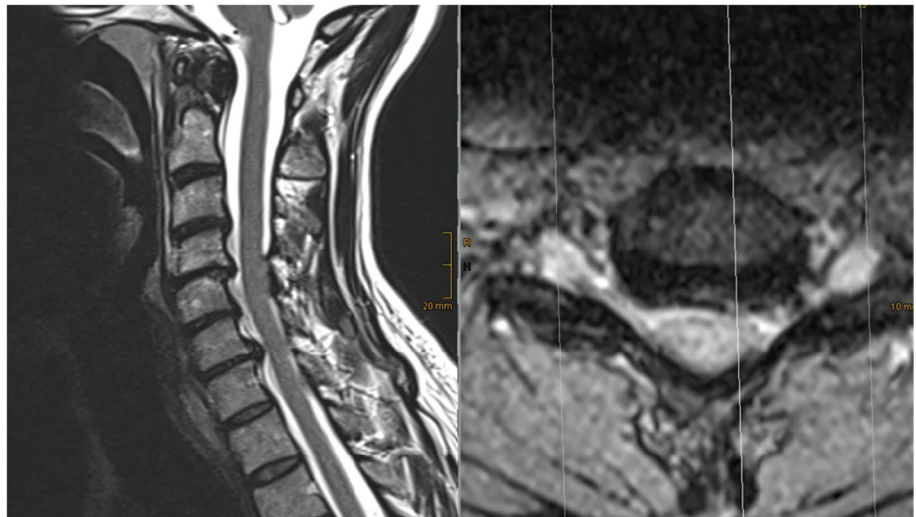

Fig. 2 Intraoperative endoscopic images displaying the foraminal nerve root decompression

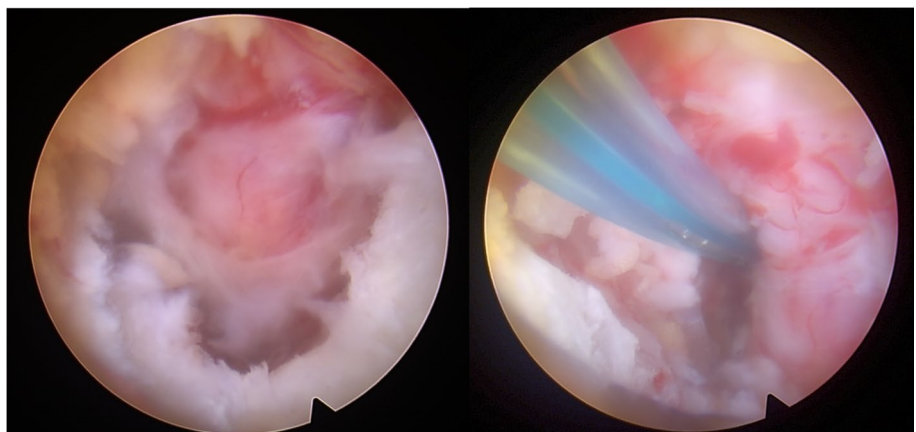


Fig. 3 Cervical MRI on emergency admission with liquid collection in the paravertebral muscles

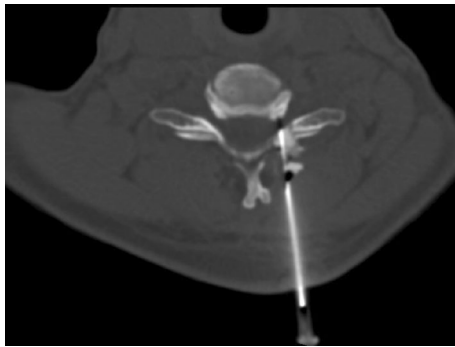
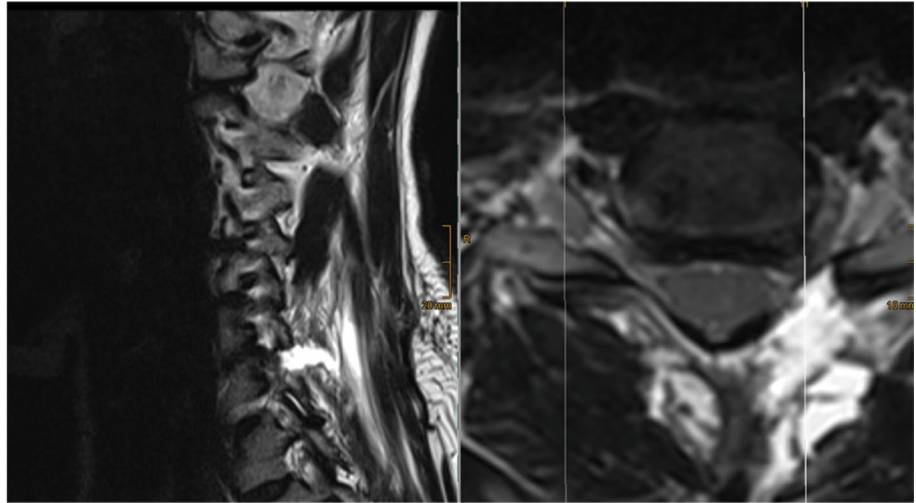


Fig. 4 CT-guided epidural blood patch

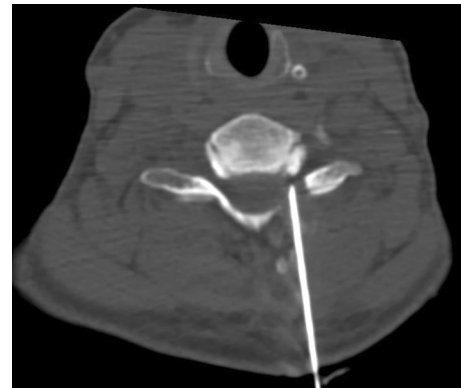


Fig. 5 CT-guided epidural fibrin patch

CSF fistula (Fig. 3). We hypothesized that the symptoms originated from a CSF leakage.

A CT-guided epidural blood patch was performed by an interventional radiologist (10 ml) (Fig. 4). Thereafter, the patient reported significant pain relief, which lasted only for 24 h. A second CT-guided epidural patch with fibrin (1 ml Thrombin/3 ml blood) was performed four days later. The 4 mL of fibrin sealant (Tisseel, Baxter) was applied into the cervical epidural space with an 18-gauge Quincke spinal needle placed at the C6/7 level. Once a satisfactory position was confirmed using image control with contrast agent application through the same needle with verification of the correct epidural placement, the fibrin mixture was injected (Fig. 5). The patient improved gradually and was discharged home two days later without any sensorimotor deficits or sequelae.

On follow-up examination, one month and three months after the initial surgery and the interventions, the patient was totally satisfied with the postoperative result. She was pain-free, mobile and without any sensorimotor deficits.

Discussion

An incidental durotomy is a rare but troublesome complication in endoscopic spine surgery, which might lead to prolonged hospital stay with immobilization, neurological worsening and development of persisting CSF leak [10]. Persistent CSF fistulas can result in chronic radicular or neck/back pain disorder and postural headaches [2]. A recent survey among spine surgeons on incidental durotomy revealed that 79.4% of all surgeons prefer application of sealant patch (TachoSil/Spongostan) with fibrin glue or a similar product, and 69.7% a single suture repair [1]. Oertel et al. demonstrated an endoscopic dural closure technique with an autologous muscle graft in combination with fibrin sealant patch which appears to be a safe alternative in patients with lumbar incidental durotomies [7]. While there is no guaranteed way to prevent dural tears, there are several steps that can be taken to reduce the risk of this complication. Overall, prevention of dural

tears during minimally invasive spine surgery requires a combination of proper patient selection, surgeon experience and training, careful surgical technique, and the use of appropriate tools and techniques to minimize the risk of complications. Full endoscopic dural repair with sutures has also been previously described [11]. However, due to a limited working corridor (maximum 1.6 mm tubes) in lumbar endoscopic surgery, the success of this technique depends on size and localization of the dural tear and is associated with a steep learning curve similar to other endoscopic techniques. Moreover, suitable instruments such as curved needle holders and knot pushers are usually not available on standard instrument sets. Conversion to minimally invasive tubular or open surgery can be performed in cases with extensive durotomies. However, previously described techniques with fibrin sealants might not only be used for augmentation of sutures but also as a sufficient inlay or onlay graft due to its strengthening properties [2, 10, 12]. Recent in vitro study on platelet-rich fibrin demonstrated good adhesive, mechanical and watertightness features and even promoted the dura-healing process. Unlike in lumbar surgery, there are only a few studies on cervical durotomies especially in degenerative spine procedures. In patients with cervical trauma and CSF leaks, fibrin glue was previously applied on the surgical site without perioperative insertion of a lumbar drain, and postoperative early removal of wound drains within the first 24 h and early rehabilitation were propagated [5]. A systematic review comparing full-endoscopic and microendoscopic approach for posterior cervical foraminotomy revealed that dural tears were uncommon in full endoscopic foraminotomies compared to more frequently transient nerve palsies [13]. Dural tears in this study even accompanied by CSF leaks were managed conservatively without further sequelae. In our case, the patient was severely impaired by a CSF fistula and unable to mobilize herself on daily basis. After discussion of all options with the patient, we aimed to avoid a second revision surgery. Therefore, an interventional blood patch was first performed and resulted in a short-term relief. Complete resolution of patient's symptoms, however, was achieved with a CT-guided fibrin patch. Injectable fibrin sealant has been shown in a several cases to relieve symptoms where blood patching has either failed or was not appropriate [8, 9]. The alternative endoscopic revision and exploration of the CSF corridor even with the possibility of conversion to open surgery might have had a quicker impact on the patient's recovery but probably would have caused more pronounced transient pain exacerbation. The advantage of a revision surgery could possibly be a better visualization of the dural tear and the possibility to directly close it permanently. However, another surgery would have been a more invasive therapy compared to a simple fibrin

injection. We therefore used the CT-guided fibrin patch as a more elaborate and less invasive alternative to deal with a postoperative CSF fistula after cervical endoscopic procedures. However, this technique appears to be limited to small dural defects without prolapsing rootlets, which eventually require a revision surgery with dural repair. The cons of this technique is the unclear target of epidural injection somewhere in the epidural space near the suspected defect, since small dural tears are sometimes not perfectly visible even in MRI and CT myelography. To our knowledge, this is the first report of a CSF fistula after endoscopic foraminotomy treated with this technique.

Conclusion

CSF fistulas after endoscopic spine procedures are a rare complication, which might severely affect and immobilize patients. A CT-guided interventional epidural fibrin patch might be a viable option in symptomatic patients with small dural defects.

Author contributions All authors contributed to the case report conception and design. Material preparation, data collection and analysis were performed by SM, BS and CM. The first draft of the manuscript was written by SM and PK and approved by ES. All authors commented on previous versions of the manuscript. All authors read and approved the final manuscript.

Funding Open Access funding enabled and organized by Projekt DEAL.

Declarations

Conflict of interest The authors have no competing interests to declare that are relevant to the content of this article. All authors certify that they have no affiliations with or involvement in any organization or entity with any financial interest or non-financial interest in the subject matter or materials discussed in this manuscript. The authors have no financial or proprietary interests in any material discussed in this article.

Informed consent Informed consent was obtained from the participant included in the study.

Open Access This article is licensed under a Creative Commons Attribution 4.0 International License, which permits use, sharing, adaptation, distribution and reproduction in any medium or format, as long as you give appropriate credit to the original author(s) and the source, provide a link to the Creative Commons licence, and indicate if changes were made. The images or other third party material in this article are included in the article's Creative Commons licence, unless indicated otherwise in a credit line to the material. If material is not included in the article's Creative Commons licence and your intended use is not permitted by statutory regulation or exceeds the permitted use, you will need to obtain permission directly from the copyright holder. To view a copy of this licence, visit <http://creativecommons.org/licenses/by/4.0/>.

References

1. Gautschi OP, Stienen MN, Smoll NR, Corniola MV, Tessitore E, Schaller K (2014) Incidental durotomy in lumbar spine surgery—a three-nation survey to evaluate its management. *Acta Neurochir (Wien)* 156:1813–1820. <https://doi.org/10.1007/s00701-014-2177-7>
2. Jankowitz BT, Atteberry DS, Gerszten PC, Karausky P, Cheng BC, Faught R, Welch WC (2009) Effect of fibrin glue on the prevention of persistent cerebral spinal fluid leakage after incidental durotomy during lumbar spinal surgery. *Eur Spine J* 18:1169–1174. <https://doi.org/10.1007/s00586-009-0928-6>
3. Kim HS, Raorane HD, Wu PH, Heo DH, Sharma SB, Jang IT (2020) Incidental durotomy during endoscopic stenosis lumbar decompression: incidence, classification, and proposed management strategies. *World Neurosurg* 139:e13–e22. <https://doi.org/10.1016/j.wneu.2020.01.242>
4. Komp M, Oezdemir S, Hahn P, Ruetten S (2018) Full-endoscopic posterior foraminotomy surgery for cervical disc herniations. *Oper Orthop Traumatol* 30:13–24. <https://doi.org/10.1007/s00064-017-0529-1>
5. Lee SE, Chung CK, Jahng TA, Kim CH (2014) Dural tear and resultant cerebrospinal fluid leaks after cervical spinal trauma. *Eur Spine J* 23:1772–1776. <https://doi.org/10.1007/s00586-014-3332-9>
6. Lewandrowski KU, Hellinger S, De Carvalho PST, Freitas Ramos MR, Soriano-SaNchez JA, Xifeng Z, Calderaro AL, Dos Santos TS, Ramirez Leon JF, de Lima ESMS, Dowling A, Data RG, Kim JS, Yeung A (2021) Dural tears during lumbar spinal endoscopy: surgeon skill, training, incidence, risk factors, and management. *Int J Spine Surg* 15:280–294. <https://doi.org/10.14444/8038>
7. Oertel JM, Burkhardt BW (2017) Full endoscopic treatment of dural tears in lumbar spine surgery. *Eur Spine J* 26:2496–2503. <https://doi.org/10.1007/s00586-017-5105-8>
8. Patel MR, Caruso PA, Yousuf N, Rachlin J (2000) CT-guided percutaneous fibrin glue therapy of cerebrospinal fluid leaks in the spine after surgery. *AJR Am J Roentgenol* 175:443–446. <https://doi.org/10.2214/ajr.175.2.1750443>
9. Roberts JM, Peterson VE, Heran MKS (2020) Percutaneous CT-guided epidural fibrin sealant injection for refractory pediatric post-dural puncture headache. *Pediatr Radiol* 50:1156–1158. <https://doi.org/10.1007/s00247-020-04691-4>
10. Shibayama M, Mizutani J, Takahashi I, Nagao S, Ohta H, Otsuka T (2008) Patch technique for repair of a dural tear in microendoscopic spinal surgery. *J Bone Joint Surg Br* 90:1066–1067. <https://doi.org/10.1302/0301-620X.90B8.20938>
11. Shin JK, Youn MS, Seong YJ, Goh TS, Lee JS (2018) Iatrogenic dural tear in endoscopic lumbar spinal surgery: full endoscopic dural suture repair (Youn’s technique). *Eur Spine J* 27:544–548. <https://doi.org/10.1007/s00586-018-5637-6>
12. Vasilikos I, Beck J, Ghanaati S, Grauvogel J, Nisyrios T, Grapatsas K, Hubbe U (2020) Integrity of dural closure after autologous platelet rich fibrin augmentation: an in vitro study. *Acta Neurochir (Wien)* 162:737–743. <https://doi.org/10.1007/s00701-020-04254-4>
13. Wu PF, Li YW, Wang B, Jiang B, Tu ZM, Lv GH (2019) Posterior cervical foraminotomy via full-endoscopic versus microendoscopic approach for radiculopathy: a systematic review and meta-analysis. *Pain Physician* 22:41–52

Publisher's Note Springer Nature remains neutral with regard to jurisdictional claims in published maps and institutional affiliations.