




CASE REPORT

Individualized targeted treatment in a case of a rare *TFG::ROS1* fusion positive inflammatory myofibroblastic tumor (IMT)

Sebastian Sommer¹  | Maximilian Schmutz¹  | Tina Schaller² | Patrick Mayr¹ | Sebastian Dintner² | Bruno Märkl² | Ralf Huss²  | M. Monika Golas^{1,3} | Michaela Kühlen^{4,5} | Frank Jordan¹ | Rainer Claus^{2,6} | Bernhard Heinrich⁷

¹Department of Hematology and Oncology, Faculty of Medicine, University of Augsburg, Augsburg, Germany

²General Pathology and Molecular Diagnostics, Faculty of Medicine, University of Augsburg, Augsburg, Germany

³Human Genetics, Faculty of Medicine, University of Augsburg, Augsburg, Germany

⁴Pediatrics and Adolescent Medicine, Faculty of Medicine, University of Augsburg, Augsburg, Germany

⁵Swabian Children's Cancer Center, University Medical Center Augsburg, Augsburg, Germany

⁶Comprehensive Cancer Center Augsburg (CCCA), Faculty of Medicine, University of Augsburg, Augsburg, Germany

⁷Heinrich/Bangerter, Hämatologie-Onkologie im Zentrum MVZ, Augsburg, Germany

Correspondence

Rainer Claus, Comprehensive Cancer Center Augsburg (CCCA), Faculty of Medicine, University of Augsburg, Stenglinstr. 2, 86156 Augsburg, Germany.

Email: rainer.claus@uk-augsburg.de

Abstract

Background: Inflammatory myofibroblastic tumor (IMTs) are rare mesenchymal neoplasms with slow growth. Resection is considered as therapeutic standard, with chemotherapy being insufficiently effective in advanced disease. *ALK* translocations are present in 50% of cases, *ROS1* fusions (*YWHAE::ROS1*, *TFG::ROS1*) are extremely rare. Here, we present a case with *TFG::ROS1* fusion and highlight the significance of molecular tumor boards (MTBs) in clinical precision oncology for post-last-line therapy.

Case Presentation: A 32-year-old woman presented with IMT diagnosed at age 27 for biopsy and treatment evaluation. Previous treatments included multiple resections and systemic therapy with vinblastine, cyclophosphamide, and methotrexate. A computed tomography scan showed extensive tumor infiltration of the psoas muscles and the posterior abdomen. Next generation sequencing revealed an actionable *ROS1* fusion (*TFG::ROS1*) with breakpoints at exon 4/35 including the kinase domain and activating the RAS-pathway. *TFG*, the *Trk*-fused gene, exerts functions such as intracellular trafficking and exhibits high sequence homology between species. Based on single reports about efficacy of *ROS1*-targeting in *ROS1* translocation positive IMTs the patient was started on crizotinib, an ATP-competitive small molecule c-MET, *ALK* and *ROS1*-inhibitor. With a follow-up of more than 9 months, the patient continues to show a profound response with major tumor regression, improved quality of life and no evidence for severe adverse events.

Conclusion: This case underscores the importance of the availability of modern molecular diagnostics and interdisciplinarity in precision oncology to identify rare, disease-defining genotypes that make an otherwise difficult-to-treat disease targetable.

KEYWORDS

crizotinib, inflammatory myofibroblastic tumor (IMT), personalized oncology, *ROS1* fusion, targeted therapy, TKI

Sebastian Sommer, Maximilian Schmutz, Rainer Claus, and Bernhard Heinrich have contributed equally.

This is an open access article under the terms of the [Creative Commons Attribution](https://creativecommons.org/licenses/by/4.0/) License, which permits use, distribution and reproduction in any medium, provided the original work is properly cited.

© 2023 The Authors. *Cancer Reports* published by Wiley Periodicals LLC.



1 | INTRODUCTION

Inflammatory myofibroblastic tumors (IMTs) are rare mesenchymal neoplasms, with approximately 150–200 new cases diagnosed each year in the United States.¹ They belong to the group of inflammatory pseudotumors and represent a distinct pathological entity. While they predominantly manifest in children at an average age of 9–10 years, in adolescents, cases have been reported across all age groups. IMTs often form in the retroperitoneum, pelvis, abdomen, and lungs, but can arise in any other anatomic location.²

Histopathologically, IMTs are defined by a variable proliferation of spindle cells on both myxoid or collagenous stroma with prominent infiltrates of plasma cells and lymphocytes.² Three major histological patterns have been defined: (1) areas with myxoid, vascular, and inflammatory features resembling nodular fasciitis; (2) infiltrates of inflammatory cells within compacted spindle cells with resemblance to fibrous histiocytoma; (3) plate-like patterns of collagen with resemblance to a desmoid scar.³

Molecular characterization of IMTs demonstrated that every second case harbors a translocation of the *ALK* gene.⁴ The 3' kinase region of *ALK* can be fused to several partners, among them are *TPM4*, *CLTC*, *CARS*, *ATIC*, *SEC31L1*, *PPFIBP1*, *DCTN1*, *EML4*, *PRKAR1A*, *LMNA*, *TFG*, *FN1*, *HNRNPA1*.^{5–13} *ALK* fusion negative cases are much rarer and include translocations of *ROS1*, *PDGFRB*, *NTRK3*, *RET*, and *IGF1R*.^{7,14,15}

Clinically, IMTs are characterized by slow, non-aggressive growth patterns. Constitutional symptoms are often the cause for primary presentation to a health care provider. The standard treatment approach for localized disease is complete resection and has high potential for cure. Although metastatic disease is extremely rare, 25% of patients with abdominopelvic tumors experience local recurrence.³ In patients with advanced or metastatic disease, therapeutic options include chemotherapy, tyrosine kinase inhibitors (TKI), and nonsteroidal anti-inflammatory drugs (NSAIDs). Retrospective studies demonstrate a high degree of efficacy with overall response rates (ORR) ranging from 48% to 64% for classical chemotherapy. Successfully applied regimens include adriamycin and ifosfamide, methotrexate, vinblastine, gemcitabine, docetaxel, and cyclophosphamide.^{16–18} The use of NSAIDs has also been reported, including combinations with methotrexate or methotrexate/cisplatin.^{19,20}

For *ALK* mutated IMTs, *ALK* inhibitors are currently the preferred treatment option. Based on case reports, a phase I/II study with crizotinib was initiated, which showed an overall response rate (ORR) of 50% (6 of 12 patients) and a disease control rate (DCR) of 100%.^{21,22} In a separate phase IB study, an ORR of 71% (5 of 7 patients) was reported.²³ Data for targeted therapies in *ALK*-negative patients remains scarce and represents a relevant clinical need.

2 | CASE DESCRIPTION

Here, we describe the case of a 32-year-old woman with no previous medical history who presented with recurrent retroperitoneal IMT in

May 2022. Prior exposure to radiation or toxins was not reported. The patient was originally diagnosed and treated in Ukraine. Retroperitoneal IMT was diagnosed in 2017 at the age of 27 years at the University Hospital in Kyiv. Treatment consisted of repeated resections in June and December 2017 as well as in August 2018. In 2018, metronomic chemotherapy was started with the NSAID celecoxib followed by vinblastine, cyclophosphamide and methotrexate. Best response was stable disease (SD). The therapy was continued until the patient fled from Ukraine in January 2022.

The patient presented to a cooperating oncology practice of the University Hospital Augsburg (UKA) with pain and functional impairment in the left gluteal region and edematous swelling of the left leg. Computed tomography (CT) scans of the abdomen showed an extensive tumorous mass infiltrating the psoas and iliopsoas muscles and subsequently infiltrating the posterior abdominal wall, lateral paravertebral muscles, and kidney (Figure 1A).

Because no tissue samples were available for additional molecular testing, a CT-guided biopsy was performed, and the case was referred to the Molecular Tumor Board (MTB) at UKA. Histologic examination confirmed the presence of IMT (Figure 2A,B). Using the AmpliSeq for Illumina Focus Panel, RNA Sequencing of the FFPE-Material identified a *TFG::ROS1* translocation (Figure 2C).

As next-line treatment, the kinase inhibitor crizotinib was recommended, consistent with an evidence level of m1C according to National Center for Tumor Diseases (NCT) guidelines.²⁴ The patient began treatment with crizotinib but rapidly developed relevant side effects. Due to edema, nausea, dizziness, and muscle cramps, the maximum tolerated dose was reduced to 250 mg daily, as opposed to the recommended dose of 250 mg twice daily. Concomitant medication consisted of dexamethasone, ondansetron, metoclopramide and metamizole.

Follow-up with CT 5 months after therapy onset showed an excellent response with significant regression of soft tissue formations in all affected muscles (Figure 1B). The abdominal wall metastasis also markedly regressed in terms of soft tissue involvement. Flake-like calcifications and visible volume decrease remained, but no pathological contrast uptake was detected. The imaging-based response was associated with a significant reduction in pain, decrease in swelling of the left leg, and functional improvement of the patient. The patient is still undergoing treatment 9 months after initiation.

2.1 | *TFG::ROS1*-fusion

ROS1 encodes a receptor tyrosine kinase whose physiological role in homo sapiens ultimately remains unelucidated.²⁵ The neural epidermal growth factor-like like 2 (NELL2) protein, has recently been shown to bind to the extracellular domain of mouse *ROS1*.²⁵ NELL2 is a lumicrine factor that is secreted by testicular germ cells and mediates lumicrine signaling, an essential pathway for male fertility.²⁵ Activated *ROS1* signaling autophosphorylates tyrosine residues in the intracellular domain. Phosphorylated sites are consecutively accessed by SH2

FIGURE 1 Computed tomography imaging showed inhomogeneous soft tissue formations in the psoas muscle, the iliopsoas and in the lateral paravertebral musculature (indicated by arrows) before initiation of crizotinib (A) and 5 months into therapy (B). The abdominal wall metastasis on the left paraumbilical side regressed considerably regarding soft tissue involvement. Grossly flaked calcifications and a decrease in volume, but no pathologic uptake of contrast remained in the affected muscular structures.

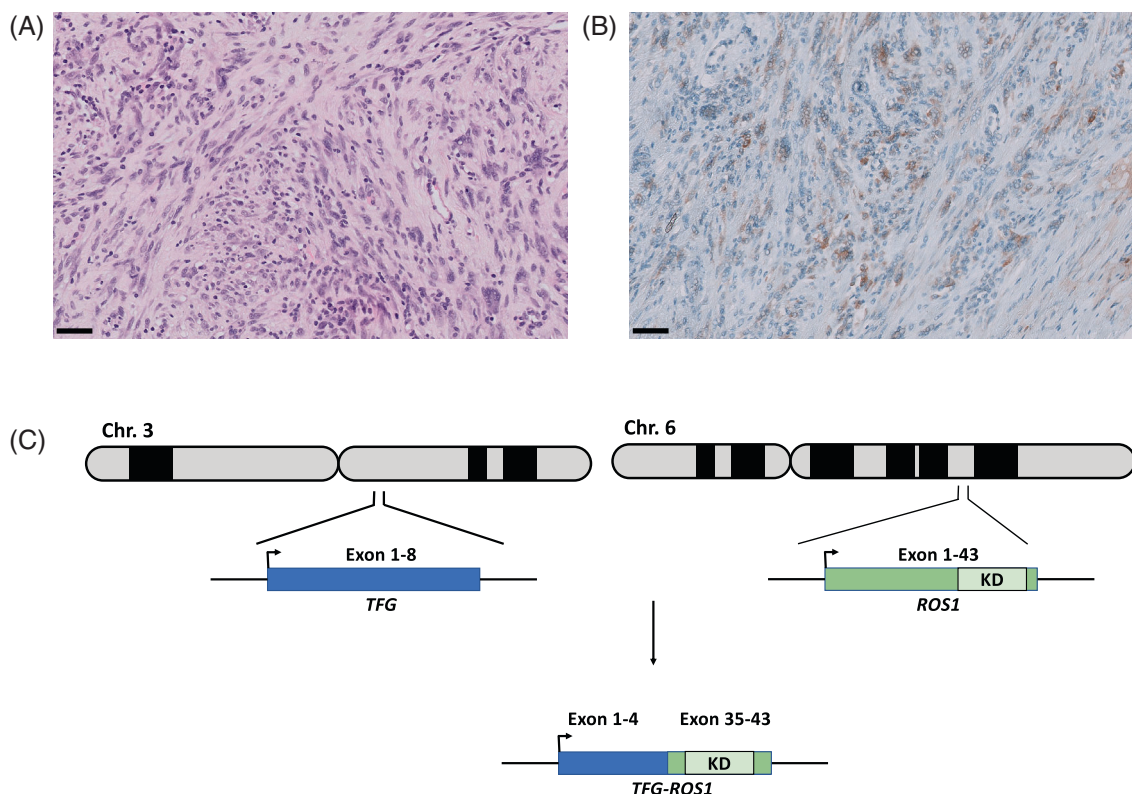
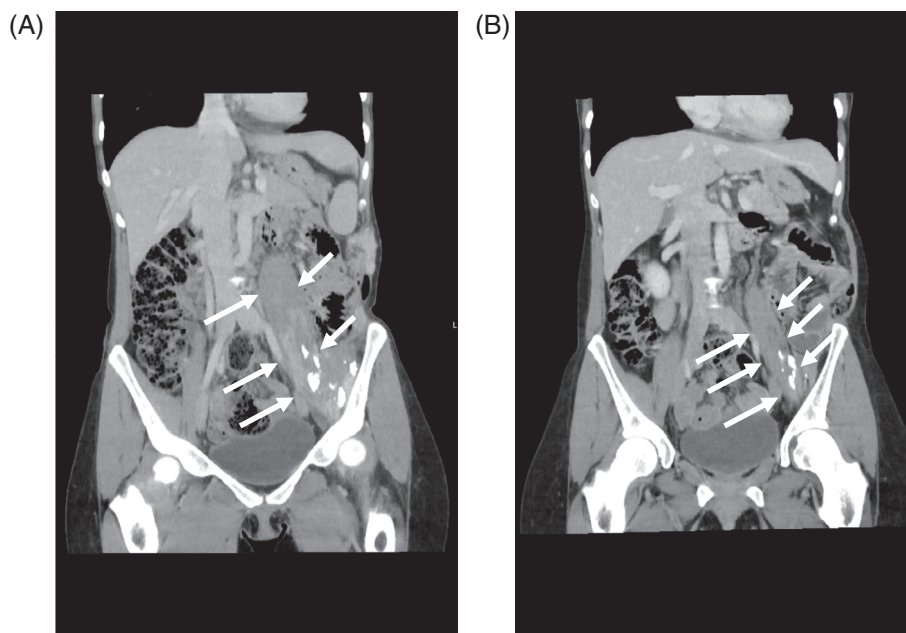


FIGURE 2 (A) Infiltration of muscle fibers by a spindle-like mesenchymal tumor (hematoxylin and eosin stain, $\times 20$), (B) ROS1-antibody staining shows subtle but distinct positivity for ROS1 ($\times 20$). Scale bar = 50 μm . (C) Schematic representation of the *TFG::ROS1* translocation. The *ROS1* gene is located on chromosome 6 (6q22.1). *TFG* is located on chromosome 3 (3q12.2). Exons 36–41 encode the kinase domain. The four major intronic breakpoints are within the introns 31, 33, 34, and 35. *TFG* exon 1–4 are fused in-frame to *ROS1*.

domain-containing or further canonical adaptors. These adaptor proteins then stimulate signaling via RAS-RAF-MEK-ERK, PI3K-AKT-mTOR and JAK-STAT3 pathways, which are mainly involved in the regulation of cell survival, growth and proliferation.²⁶

Up to 55 different 5'-gene partners have been described as fused to the 3' region of *ROS1*. This marked heterogeneity of *ROS1* partner genes has been observed between patients and especially between different cancer types. In IMTs, *YWHAE::ROS1* and *TFG::*

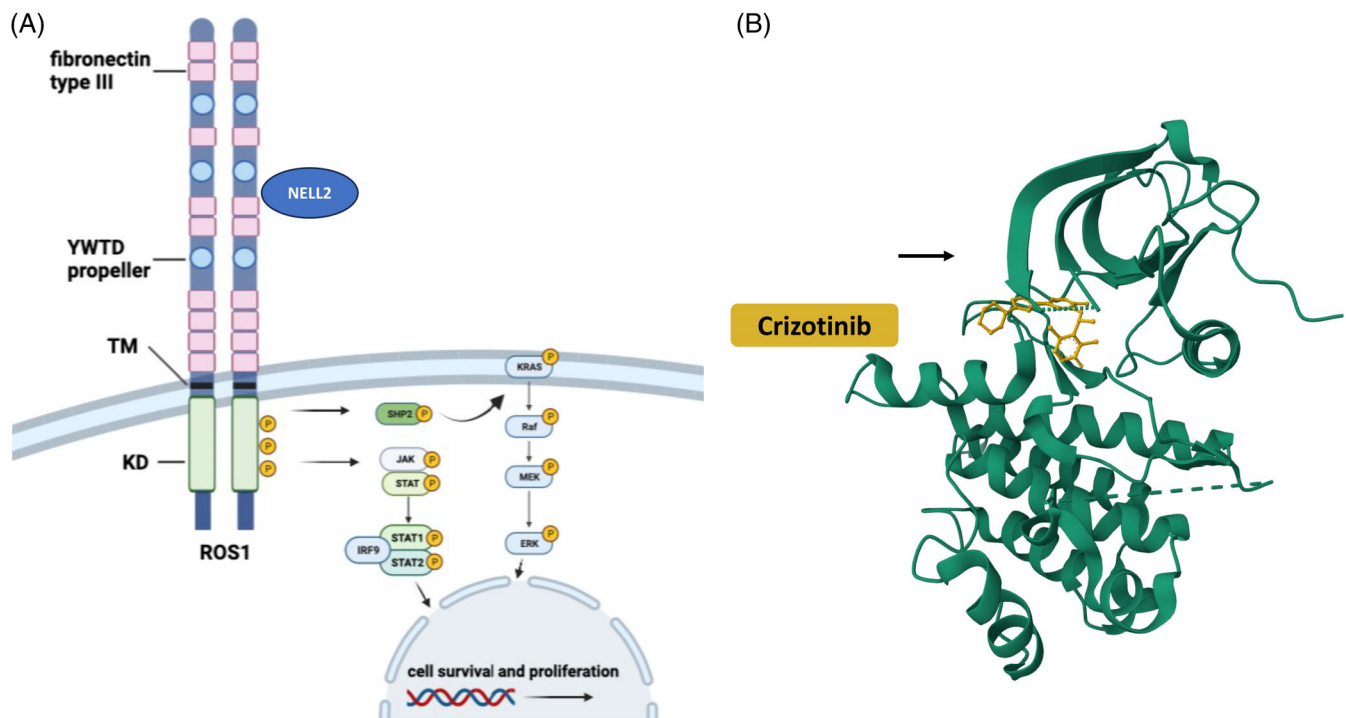


FIGURE 3 (A) ROS1 receptor domain comprises an intracellular kinase domain (KD), a transmembrane domain (TM), nine fibronectin motifs and three β -propeller domains. Interaction with NELL2 is supposed to mediate autophosphorylation and KD activation. Signal transduction is ultimately mediated via JAK/STAT and RAS–RAF–MEK–ERK pathways, respectively. (B) DFG-motif in type I conformation (DFG-in) with crizotinib shown in yellow (adapted from PDB 3ZBF).

ROS1 are the predominant translocations and make up 10% of all IMTs.^{7,27,28}

Both translocations result in a loss of the large extracellular domain as well as a fusion (in-frame) of the N-terminal portion of the fusion partner with the intracellular kinase domain. Tropomyosin-receptor kinase fused gene (*TFG*) is a common fusion partner of ROS1, *MET*, *ALK*, *NTRK1*, and *NTRK3*.²⁹ ROS1-fusions lead to constitutive activation of the kinase domain, which drives oncogenesis via the described signal transduction pathways.

The kinase domain of ROS1 shares 70% homology with the ALK kinase domain. The ROS1 kinase exhibits two main conformations: type I is the active form, while type II is the inactive form. Most TKIs (e.g., crizotinib, entrectinib, ceritinib, ensartinib, brigatinib, lorlatinib, repotrectinib, and talectrectinib) bind to the active type I kinase form, which contains the ATP-binding pocket of the ROS1 kinase, and thus inhibit its kinase activity.²⁶ The type I conformation provides access to the catalytic site of the kinase domain by geometrically enabling contact through folding/orientation of an aspartic acid-phenylalanine-glycine motif (DFG-motif or DFG-in). In type I configuration, phosphatases of ATP are optimally positioned to facilitate phosphate transfer and therefore exerting catalytic activity. Type I inhibitors compete with ATP binding. In contrast, the inactive, type II, “DFG-out” kinase domain conformation is characterized by blocked access to the catalytic site. Type II ROS1 inhibitors such as cabozantinib and foretinib preferentially bind to the type II conformation. Figure 3A,B gives an overview of the mechanism of action of

crizotinib and summarizes the pathways activated by ROS1 (adapted from²⁶).

3 | METHOD AND LIMITATIONS

Detection of the ROS1 fusion transcript was performed by next generation sequencing (NGS) and overexpression resulting from the fusion was confirmed by immunohistochemistry. From formalin-fixed and paraffin-embedded (FFPE) tumor tissue, an area of the tumor was microdissected under histomorphological control with a tumor purity of 70%. Libraries were prepared from RNA and DNA using the Ampli-Seq for Illumina Focus Panel amplicon based chemistry.³⁰ RNA sequencing was carried out with an average on-target aligned reads of 300 000. Data analysis was performed as previously described.³¹ In brief, the Illumina BaseSpace application was used for DNA/RNA amplicon analysis and comprehensive variant identification including SNVs, CNVs, indels and gene fusions. Non-synonymous and non-polymorphic variants were interpreted using Illumina's Variant Interpreter and cross-checked via the Integrated Genome Viewer to rule out sequence errors. The BaseSpace Knowledge Network was used for additional data analysis.

Limitations and challenges of amplicon-based panels include the limited scope of regions examined, as only certain sequence segments of the genome are covered. In particular, for the detection of larger structural variants and chromosomal translocations or gene fusions, as

TABLE 1 Published case reports of patients with ROS1-translocated inflammatory myofibroblastic tumors.

Report	Translocation	Primary lesion	Age	Sex	Drug	Duration of response	Response	Comment
Comandini et al. ³²	YWHAE1::ROS1	Left thigh	23	Male	Crizotinib	> 3 years ongoing	CR	
Lovly et al. ⁷	TFG::ROS1	Left lung	6	Male	Crizotinib	> 4 months	PR	
Srikanth Ambati et al. ³³	TFG::ROS1	Left lung	10	Female	Entrectinib	>13 cycles	PR	Patient chose active surveillance after very good PR
Carcamo et al. ³⁴	TFG::ROS1	Chest wall	16	Male	Crizotinib	8 months	PR	Near-complete response
					Ceritinib	No response		
					Lorlatinib	> 11 months	PR	
Ingly et al. ³⁵	TFG::ROS1	Right Lung	14	Female	Crizotinib	22 cycles	SD	PR brain metastasis
					Brigatinib	9 months	Rapid clinical response	
					Lorlatinib	1 year	PR	Complete surgical resection after 1 year Lorlatinib
Styczewska ³⁶	TFG::ROS1	Tongue	7	Female	Crizotinib	4 months	PR	Complete surgical resection after Treatment
Mai et al. ³⁷	TFG::ROS1	Right Lung	14	Male	Crizotinib	>8 months	PR	
Vassal g. et al. ³⁸	Not reported partner::ROS1	Na	Na	Na	Crizotinib	Na	PR	

in this case, amplicon-based panels have their limitations. Amplicon-based panels can only map known fusion breakpoints and are therefore generally virtually unsuitable for detecting new unknown fusion partners or fusions at unusual breakpoints not covered by amplicons. Because fusion transcripts can vary widely in expression, quantification using amplicon-based approaches can be inaccurate due to inherent amplification bias. However, the clinical relevance of fusions is often critically related to the extent of expression.

4 | DISCUSSION

Here, we describe a case in precision medicine where a direct link between a molecularly defined target and disease progression exists in a rare cancer entity that allows for a targeted therapy. Our case report is further evidence of effective targeted TKI-based therapy in IMTs. In addition, our case report highlights the value of a sophisticated diagnostic infrastructure and modern pipeline for individual therapy management in rare cancers. This is of particular importance in rare tumors such as IMTs, where identification of gene fusions is critical for highly effective personalized treatment with TKIs. Integrating advanced molecular diagnostics with an MTB that allows for thorough research and interdisciplinary evidence assessment based on available data is key to providing the most informed, evidence-based, and individualized approach to specific oncological cases.

We illustrate the relevance and effectiveness of this approach in a rare case of ROS1-translocated IMT. After several previous treatment approaches and lines of therapy, and most recently with progressive disease, the diagnosis of IMT was confirmed by core needle

biopsy and a TFG::ROS1 translocation was detected by NGS. The patient responded very well to crizotinib within a short period of time and showed a tolerable level of adverse events after dose adjustment. We identified 8 case reports with IMTs harboring a ROS1 translocation including one case with the translocation partner YWHAE1 (Table 1). All but one patient was started on crizotinib (entrectinib in one case). A single patient demonstrated a complete response (CR), whereas six of the eight patients showed a partial response (PR), with another patient exhibiting stable disease (SD). Subsequently, disease progression (PD) was observed in two patients during their treatment with crizotinib. One of the latter patients did not respond to subsequent therapy with ceritinib, but eventually the patient's tumor achieved a near CR with lorlatinib, a third-generation TKI. The second patient had a rapid clinical response to brigatinib for 9 months and was subsequently switched to lorlatinib, which led to a PR allowing for complete resection of the tumor after 1 year.

As drug resistance may develop, regular CT scans to assess tumor dimensions and subsequent molecular re-profiling in case of progression are crucial to detect resistance to the selective therapeutic pressure exerted by crizotinib. With brigatinib and lorlatinib, there are alternatives in case of progression. Unfortunately, all case reports cover only a short follow-up period. Longitudinal follow-up, including monitoring of ROS1 fusion transcripts and detection of potential resistance mutations in ROS1, is necessary to evaluate and select the best targeted treatment for patients with IMTs. A modern MTB infrastructure for tracking individual patient trajectories including clinical and molecular follow-up needs to be implemented, especially in the context of actionable targets.



5 | CONCLUSION

Despite their typically protracted and less aggressive course, IMTs remain challenging both in diagnosis and treatment. NGS-based identification of genomic alterations and predictive genetic biomarkers have become an integral part of diagnostic workup in precision oncology. This case once more highlights the importance of molecular diagnostics, the value of access to a multidisciplinary MTB with access to cutting-edge technology and the resulting individualized treatment.

AUTHOR CONTRIBUTIONS

Sebastian Sommer: Conceptualization (equal); data curation (lead); writing – original draft (lead); writing – review and editing (lead). **Maximilian Schmutz:** Conceptualization (equal); data curation (equal); writing – original draft (equal); writing – review and editing (equal). **Tina Schaller:** Data curation (supporting); investigation (supporting). **Michaela Kuhlen:** Investigation (supporting); resources (supporting). **Frank Jordan:** Data curation (supporting); resources (supporting). **Sebastian Dintner:** Data curation (supporting). **Patrick Mayr:** Data curation (supporting). **M. Monika Golas:** Resources (supporting). **Bruno Märkl:** Resources (equal). **Ralf Huss:** Resources (supporting). **Rainer Claus:** Conceptualization (equal); writing – review and editing (equal). **Bernhard Heinrich:** Conceptualization (lead); data curation (equal); writing – review and editing (equal).

ACKNOWLEDGMENT

This work was partially funded by intramural funding of the Faculty of Medicine, University of Augsburg. The authors would like to thank all patients and colleagues supporting the interdisciplinary precision oncology program at the the Faculty of Medicine, University of Augsburg. Open Access funding enabled and organized by Projekt DEAL.

CONFLICT OF INTEREST STATEMENT

The authors hereby confirm that there are no conflicts of interest in connection with this article.

DATA AVAILABILITY STATEMENT

The data on which the results and conclusions of this study are based are available on personal request from the corresponding author.

ETHICS STATEMENT

The patient provided her written informed consent for publishing the case report. According to the regional law Bayerisches Krankenhausgesetz (BayKrG) in the version of 28 March 2007 (GVBl. S. 288, BayRS 2126-8-G Art. 27 Abs4), an ethical statement for retrospective analysis of the data is not necessary.

ORCID

Sebastian Sommer <https://orcid.org/0000-0002-7446-7629>

Maximilian Schmutz <https://orcid.org/0000-0002-7453-7260>

Ralf Huss <https://orcid.org/0000-0002-6447-9300>

REFERENCES

- Tothova Z, Wagner AJ. Anaplastic lymphoma kinase-directed therapy in inflammatory myofibroblastic tumors. *Curr Opin Oncol.* 2012;24:409-413. doi:[10.1097/CCO.0b013e328354c155](https://doi.org/10.1097/CCO.0b013e328354c155)
- Gleason BC, Hornick JL. Inflammatory myofibroblastic tumours: where are we now? *J Clin Pathol.* 2008;61:428-437. doi:[10.1136/jcp.2007.049387](https://doi.org/10.1136/jcp.2007.049387)
- Coffin CM, Watterson J, Priest JR, Dehner LP. Extrapulmonary inflammatory myofibroblastic tumor (inflammatory pseudotumor). A clinicopathologic and immunohistochemical study of 84 cases. *Am J Surg Pathol.* 1995;19:859-872. doi:[10.1097/00000478-199508000-00001](https://doi.org/10.1097/00000478-199508000-00001)
- Coffin CM, Patel A, Perkins S, Elenitoba-Johnson KSJ, Perlman E, Griffin CA. ALK1 and p80 expression and chromosomal rearrangements involving 2p23 in inflammatory myofibroblastic tumor. *Mod Pathol.* 2001;14:569-576. doi:[10.1038/modpathol.3880352](https://doi.org/10.1038/modpathol.3880352)
- Bridge JA, Kanamori M, Ma Z, et al. Fusion of the ALK gene to the clathrin heavy chain gene, CLTC, in inflammatory myofibroblastic tumor. *Am J Pathol.* 2001;159:411-415. doi:[10.1016/S0002-9440\(10\)61711-7](https://doi.org/10.1016/S0002-9440(10)61711-7)
- Chen ST, Lee JC. An inflammatory myofibroblastic tumor in liver with ALK and RANBP2 gene rearrangement: combination of distinct morphologic, immunohistochemical, and genetic features. *Hum Pathol.* 2008;39:1854-1858. doi:[10.1016/j.humpath.2008.04.016](https://doi.org/10.1016/j.humpath.2008.04.016)
- Lovly CM, Gupta A, Lipson D, et al. Inflammatory myofibroblastic tumors harbor multiple potentially actionable kinase fusions. *Cancer Discov.* 2014;4:889-895. doi:[10.1158/2159-8290.CD-14-0377](https://doi.org/10.1158/2159-8290.CD-14-0377)
- Inamura K, Kobayashi M, Nagano H, et al. A novel fusion of HNRNPA1-ALK in inflammatory myofibroblastic tumor of urinary bladder. *Hum Pathol.* 2017;69:96-100. doi:[10.1016/j.humpath.2017.04.022](https://doi.org/10.1016/j.humpath.2017.04.022)
- Yamamoto H, Kohashi K, Oda Y, et al. Absence of human herpesvirus-8 and Epstein-Barr virus in inflammatory myofibroblastic tumor with anaplastic large cell lymphoma kinase fusion gene. *Pathol Int.* 2006;56:584-590. doi:[10.1111/j.1440-1827.2006.02012.x](https://doi.org/10.1111/j.1440-1827.2006.02012.x)
- Takeuchi K, Soda M, Togashi Y, et al. Pulmonary inflammatory myofibroblastic tumor expressing a novel fusion, PPFIBP1-ALK: reappraisal of anti-ALK immunohistochemistry as a tool for novel ALK fusion identification. *Clin Cancer Res.* 2011;17:3341-3348. doi:[10.1158/1078-0432.CCR-11-0063](https://doi.org/10.1158/1078-0432.CCR-11-0063)
- Lawrence B, Perez-Atayde A, Hibbard MK, et al. TPM3-ALK and TPM4-ALK oncogenes in inflammatory myofibroblastic tumors. *Am J Pathol.* 2000;157:377-384. doi:[10.1016/S0002-9440\(10\)64550-6](https://doi.org/10.1016/S0002-9440(10)64550-6)
- Griffin CA, Hawkins AL, Dvorak C, Henkle C, Ellingham T, Perlman EJ. Recurrent involvement of 2p23 in inflammatory myofibroblastic tumors. *Cancer Res.* 1999;59:2776-2780.
- Debelenko LV, Arthur DC, Pack SD, Helman LJ, Schrupp DS, Tsokos M. Identification of CARS-ALK fusion in primary and metastatic lesions of an inflammatory myofibroblastic tumor. *Lab Invest.* 2003;83:1255-1265. doi:[10.1097/01.lab.0000088856.49388.ea](https://doi.org/10.1097/01.lab.0000088856.49388.ea)
- Takahashi A, Kurosawa M, Uemura M, Kitazawa J, Hayashi Y. Anaplastic lymphoma kinase-negative uterine inflammatory myofibroblastic tumor containing the ETV6-NTRK3 fusion gene: a case report. *J Int Med Res.* 2018;46:3498-3503. doi:[10.1177/0300060518780873](https://doi.org/10.1177/0300060518780873)
- Antonescu CR, Suurmeijer AJH, Zhang L, et al. Molecular characterization of inflammatory myofibroblastic tumors with frequent ALK and ROS1 gene fusions and rare novel RET rearrangement. *Am J Surg Pathol.* 2015;39:957-967. doi:[10.1097/PAS.0000000000000404](https://doi.org/10.1097/PAS.0000000000000404)
- Baldi GG, Brahma M, Lo Vullo S, et al. The activity of chemotherapy in inflammatory Myofibroblastic tumors: a multicenter European retrospective case series analysis. *Oncologist.* 2020;25:e1777-e1784. doi:[10.1634/theoncologist.2020-0352](https://doi.org/10.1634/theoncologist.2020-0352)

17. Casanova M, Brennan B, Alaggio R, et al. Inflammatory myofibroblastic tumor: the experience of the European pediatric soft tissue sarcoma study group (EpSSG). *Eur J Cancer*. 2020;127:123-129. doi:10.1016/j.ejca.2019.12.021
18. Kube S, Vokuhl C, Dantonello T, et al. Inflammatory myofibroblastic tumors—a retrospective analysis of the Cooperative Weichteilsarkom Studiengruppe. *Pediatr Blood Cancer*. 2018;65:e27012. doi:10.1002/pbc.27012
19. Tao YL, Wang ZJ, Han JG, Wei P. Inflammatory myofibroblastic tumor successfully treated with chemotherapy and nonsteroidals: a case report. *World J Gastroenterol*. 2012;18:7100-7103. doi:10.3748/wjg.v18.i47.7100
20. Kusunoki-Nakamoto F, Matsukawa T, Tanaka M, et al. Successful treatment of an unresectable inflammatory myofibroblastic tumor of the frontal bone using a cyclooxygenase-2 inhibitor and methotrexate. *Intern Med*. 2013;52:623-628. doi:10.2169/internalmedicine.52.8785
21. Schoffski P, Sufliarsky J, Gelderblom H, et al. Crizotinib in patients with advanced, inoperable inflammatory myofibroblastic tumours with and without anaplastic lymphoma kinase gene alterations (European Organisation for Research and Treatment of Cancer 90101 CREATE): a multicentre, single-drug, prospective, non-randomised phase 2 trial. *Lancet Respir Med*. 2018;6:431-441. doi:10.1016/S2213-2600(18)30116-4
22. Butrynski JE, D'Adamo DR, Hornick JL, et al. Crizotinib in ALK-rearranged inflammatory myofibroblastic tumor. *N Engl J Med*. 2010;363:1727-1733. doi:10.1056/NEJMoa1007056
23. Administration, U. F. https://www.accessdata.fda.gov/drugsatfda_docs/label/2022/202570s033lbl.pdf
24. Horak P, Klink B, Heining C, et al. Precision oncology based on omics data: the NCT Heidelberg experience. *Int J Cancer*. 2017;141:877-886. doi:10.1002/ijc.30828
25. Kiyozumi D, Noda T, Yamaguchi R, et al. NELL2-mediated lumicrine signaling through OVCH2 is required for male fertility. *Science*. 2020;368:1132-1135. doi:10.1126/science.aay5134
26. Drilon A, Jenkins C, Iyer S, Schoenfeld A, Keddy C, Davare MA. ROS1-dependent cancers: biology, diagnostics and therapeutics. *Nat Rev Clin Oncol*. 2021;18:35-55. doi:10.1038/s41571-020-0408-9
27. Fujita H, Yoshida A, Taniguchi H, Katai H, Sekine S. Adult-onset inflammatory myofibroblastic tumour of the stomach with a TFG-ROS1 fusion. *Histopathology*. 2015;66:610-612. doi:10.1111/his.12575
28. Davies KD, Doebele RC. Molecular pathways: ROS1 fusion proteins in cancer. *Clin Cancer Res*. 2013;19:4040-4045. doi:10.1158/1078-0432.CCR-12-2851
29. Consortium, A. P. G. AACR project GENIE: powering precision medicine through an international consortium. *Cancer Discov*. 2017;7:818-831. doi:10.1158/2159-8290.CD-17-0151
30. Illumina. <https://emea.support.illumina.com/downloads/ampliseq-for-illumina-focus-panel-reference-guide-100000039456.html>
31. Reitsam NG, Märkl B, Dintner S, Waidhauser J, Vlasenko D, Grosser B. Concurrent loss of MLH1, PMS2 and MSH6 immunorexpression in digestive system cancers indicating a widespread dysregulation in DNA repair processes. *Front Oncol*. 2022;12:1019798. doi:10.3389/fonc.2022.1019798
32. Comandini D, Catalano F, Grassi M, et al. Outstanding response in a patient with ROS1-rearranged inflammatory myofibroblastic tumor of soft tissues treated with Crizotinib: case report. *Front Oncol*. 2021;11:658327. doi:10.3389/fonc.2021.658327
33. Ambati SR, Slotkin EK, Chow-Maneval E, Basu EM. Entrectinib in two pediatric patients with inflammatory myofibroblastic tumors harboring ROS1 or ALK gene fusions. *JCO Precis Oncol*. 2018;2:PO.18.00095. doi:10.1200/PO.18.00095
34. Carcamo B, Bista R, Wilson H, Reddy P, Pacheco J. Rapid response to lorlatinib in a patient with TFG-ROS1 fusion positive inflammatory myofibroblastic tumor of the chest wall metastatic to the brain and refractory to first and second generation ROS1 inhibitors. *J Pediatr Hematol Oncol*. 2021;43:e718-e722. doi:10.1097/MPH.0000000000002185
35. Ingley KM, Hughes D, Hubank M, et al. Durable response to serial tyrosine kinase inhibitors (TKIs) in an adolescent with metastatic TFG-ROS1 fusion positive inflammatory myofibroblastic tumor (IMT). *Lung Cancer*. 2021;158:151-155. doi:10.1016/j.lungcan.2021.05.024
36. Styczewska M, Patel A, Jaskulowska J, et al. Therapeutic options in inoperable ROS1-rearranged inflammatory myofibroblastic tumor of the tongue in a child: a case report and literature review. *Anticancer Drugs*. 2021;32:1111-1115. doi:10.1097/CAD.0000000000001099
37. Mai S, Xiong G, Diao D, Wang W, Zhou Y, Cai R. Case report: Crizotinib is effective in a patient with ROS1-rearranged pulmonary inflammatory myofibroblastic tumor. *Lung Cancer*. 2019;128:101-104. doi:10.1016/j.lungcan.2018.12.016
38. Vassal G, Faivre L, Geoerger B, et al. Crizotinib in children and adolescents with advanced ROS1, MET, or ALK-rearranged cancer: results of the AcSé phase II trial. *J Clin Oncol*. 2016;34:11509. doi:10.1200/JCO.2016.34.15_suppl.11509

How to cite this article: Sommer S, Schmutz M, Schaller T, et al. Individualized targeted treatment in a case of a rare TFG:: ROS1 fusion positive inflammatory myofibroblastic tumor (IMT). *Cancer Reports*. 2023;e1916. doi:10.1002/cnr2.1916