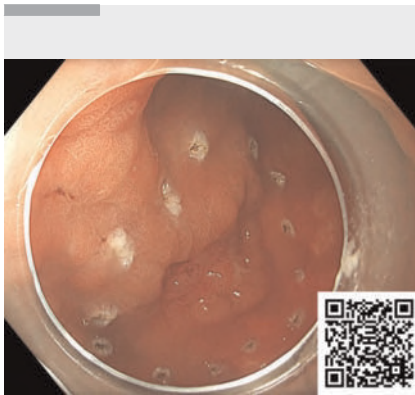


# Nonexposed endoscopic wall inversion surgery with sentinel node mapping for a high risk gastric lesion



**▶ Video 1** Nonexposed endoscopic wall inversion surgery in an elderly patient with a suspected T2 gastric cancer.

Endoscopic submucosal dissection (ESD) is the standard approach for the management of early gastric cancer (EGC) [1]. However, in some situations, such as in borderline lesions, a combined laparoscopic-endoscopic technique may be a valid option [2]. We report the case of an 85-year-old man with multiple comorbidities who presented to us for further management of an EGC in the gastric body.

Endoscopic and endosonographic assessment revealed an ulcerated lesion (Paris IIc) with a suspicion of at least deep submucosal invasion (T1b/T2 N0). Owing to his age and comorbidities, the patient refused a gastrectomy but agreed to an individualized approach. After multidisciplinary team discussion, we opted for nonexposed endoscopic wall inversion surgery (NEWS) with sentinel node mapping (▶ **Video 1**).

NEWS is a subcategory of laparoscopic-endoscopic combined surgery [2] whereby the laparoscopic surgeon performs an initial seromuscular incision around the lesion, inverts the entire lesion along

with a spacer intraluminally, and then places a seromuscular suture. Finally, the endoscopist performs a full-thickness resection of the lesion, while taking care to spare the seromuscular suture placed by the laparoscopist [3]. This nonexposed approach prevents possible peritoneal spillage and at the same time allows for full-thickness resection.

Compared with laparoscopic wedge resection, NEWS enables minimal tissue resection, especially in difficult positions [4]. Early data on NEWS and sentinel node mapping have demonstrated their safety and efficacy [4, 5]. Histopathology in our patient showed a moderately differentiated cancer (G2) with deep submucosal invasion of 600 µm. Three lymph nodes resected by sentinel node mapping were negative.

Endoscopy\_UCTN\_Code\_CPL\_1AJ\_2AD\_3AF

## Conflict of Interest

The authors declare that they have no conflict of interest.

## The authors

**Alanna Ebigbo<sup>1</sup>, Dmytro Vlasenko<sup>2</sup>, Markus W. Scheppach<sup>1</sup>, Sandra Nagl<sup>1</sup>, Matthias Anthuber<sup>2</sup>, Helmut Messmann<sup>1</sup>**

- 1 Department of Gastroenterology, University Hospital Augsburg, Augsburg, Germany
- 2 Department of Abdominal and Visceral Surgery, University Hospital Augsburg, Augsburg, Germany

## Corresponding author

**Alanna Ebigbo, MD**  
Department of Gastroenterology, University Hospital Augsburg, Stenglinstr. 2, 86156 Augsburg, Germany  
alanna.ebigbo@gmx.de

## References

- [1] Pimentel-Nunes P, Libânio D, Bastiaansen BAJ et al. Endoscopic submucosal dissection for superficial gastrointestinal lesions: European Society of Gastrointestinal Endoscopy (ESGE) Guideline – update 2022. *Endoscopy* 2022; 54: 591–622. doi:10.1055/a-1811-7025
- [2] Zhao PY, Ma ZF, Jiao YN et al. Laparoscopic and endoscopic cooperative surgery for early gastric cancer: perspective for actual practice. *Front Oncol* 2022; 12: 969628. doi:10.3389/fonc.2022.969628
- [3] Pasquer A, Poncet G, Rostain F et al. Successful non-exposed endoscopic wall-inversion surgery for gastric stromal tumor and gastric ESD for dysplastic lesion during a single procedure. *Endoscopy* 2021; 53: E452–E454
- [4] Crafa F, Vanella S, Morante A et al. Non-exposed endoscopic wall-inversion surgery with one-step nucleic acid amplification for early gastrointestinal tumors: Personal experience and literature review. *World J Gastroenterol* 2023; 29: 3883–3898
- [5] Kitagawa Y, Takeuchi H, Takagi Y et al. Sentinel node mapping for gastric cancer: a prospective multicenter trial in Japan. *J Clin Oncol* 2013; 31: 3704–3710. doi:10.1200/JCO.2013.50.3789

## Bibliography

*Endoscopy* 2024; 56: E527  
DOI 10.1055/a-2342-0221  
ISSN 0013-726X  
© 2024. The Author(s).

This is an open access article published by Thieme under the terms of the Creative Commons Attribution License, permitting unrestricted use, distribution, and reproduction so long as the original work is properly cited.

(<https://creativecommons.org/licenses/by/4.0/>)

Georg Thieme Verlag KG, Rüdigerstraße 14, 70469 Stuttgart, Germany

