

# Biomechanical Comparison of Anterograde and Retrograde Lesser Trochanter Avulsion Repair

Alexander Otto,<sup>\*†‡§</sup> MD, Joshua B. Baldino,<sup>†</sup> PharmD, Alyssa M. DiCosmo,<sup>†</sup> BS, Katherine Coyner,<sup>†</sup> MD, Jeremiah D. Johnson,<sup>†</sup> MD, Elifho Obopilwe,<sup>†</sup> MS, Mark P. Cote,<sup>†</sup> DPT, MSCTR, Lukas N. Muench,<sup>†‡</sup> MD, Knut Beitzel,<sup>†||</sup> MD, Bastian Scheiderer,<sup>‡</sup> MD, Andreas B. Imhoff,<sup>‡</sup> MD, Augustus D. Mazzocca,<sup>†</sup> MD, and Julian Mehl,<sup>†‡</sup> MD

*Investigation performed at the Department of Orthopaedic Surgery, UConn Musculoskeletal Institute, University of Connecticut, Farmington, Connecticut, USA*

**Background:** Lesser trochanter avulsions are rare injuries in adolescents. Severe cases with relevant fragment displacement can be treated surgically. However, no standard approach is available in the literature. Operative techniques are presently limited to anterograde fixations. A new retrograde approach to reduce operative difficulty and postoperative morbidity has been proposed. So far, no biomechanical comparison of these techniques is available.

**Hypothesis:** Retrograde repair of the lesser trochanter with a titanium cortical button will produce superior stability under load to failure and similar displacement under cyclic loading compared with anterograde fixation with titanium suture anchors.

**Study Design:** Controlled laboratory study.

**Methods:** Sixteen paired hemipelvic cadaveric specimens (mean age, 62.5 ± 10.7 years) were dissected to isolate the lesser trochanter and iliopsoas muscle. After repair of a simulated lesser trochanter avulsion, specimens were tested under cyclic loading between 10 and 125 N at 1 Hz for 1500 cycles before finally being loaded to failure at a rate of 120 mm/min in a material testing machine. Motion tracking was used to assess displacement at the superior and inferior aspects of the iliopsoas tendon under cyclic loading.

**Results:** Load to failure was significantly greater for the retrograde repair compared with the anterograde repair (1075.24 ± 179.39 vs 321.85 ± 62.45 N;  $P = .012$ ). Mean displacement at the superior repair aspect (retrograde vs anterograde: 3.29 ± 1.84 vs 4.39 ± 4.50 mm;  $P = .779$ ) and mean displacement at the inferior aspect (3.54 ± 2.13 vs 4.22 ± 4.48 mm;  $P = .779$ ) of the iliopsoas tendon did not significantly differ by the type of repair. Mode of failure was tendon tearing by the sutures for each retrograde repair and anchor pullout for each anterograde repair.

**Conclusion:** Surgical repair of lesser trochanter avulsion fractures with retrograde fixation using a titanium cortical button demonstrated superior load to failure and similar displacement under cyclic loading compared with anterograde fixation using suture anchors.

**Clinical Relevance:** The retrograde approach provides a biomechanically validated alternative to other surgical techniques for this injury.

**Keywords:** lesser trochanter avulsion; pelvis; hip; adolescent; apophyseal avulsion fracture; retrograde fixation technique

Apophyseal avulsion fractures are rare injuries of the pelvis and the hip that usually occur in young athletes between the ages of 14 and 25 years.<sup>12</sup> Ossification of the apophyses is not yet complete in the immature skeleton, increasing susceptibility of the growth plates to trauma.<sup>3,20</sup> Adolescents are particularly vulnerable to apophyseal avulsion injuries in sports involving abrupt, forceful muscular contractions.<sup>3,12</sup> The most common

mechanisms of injury are running or sprinting (39%) and kicking a ball (29%).<sup>21</sup>

Avulsion injuries of the lesser trochanter constitute less than 3% of pelvic and hip apophyseal avulsion fractures.<sup>3,20</sup> Ball sports are the most common setting for lesser trochanter avulsion fractures in adolescents.<sup>3</sup> Unfortunately, the literature on this injury and patient population is limited to only a few published case reports.<sup>8,9,13,15,17,25</sup> Regardless of the setting or mechanism of injury, lesser trochanter avulsion can produce significant morbidity. Severe pain, swelling, local tenderness to palpation, limited hip flexion, and disturbed gait and weightbearing are all symptoms of this

The Orthopaedic Journal of Sports Medicine, 8(1), 2325967119892281  
DOI: 10.1177/2325967119892281  
© The Author(s) 2020

This open-access article is published and distributed under the Creative Commons Attribution - NonCommercial - No Derivatives License (<https://creativecommons.org/licenses/by-nc-nd/4.0/>), which permits the noncommercial use, distribution, and reproduction of the article in any medium, provided the original author and source are credited. You may not alter, transform, or build upon this article without the permission of the Author(s). For article reuse guidelines, please visit SAGE's website at <http://www.sagepub.com/journals-permissions>.

injury and can inhibit daily function and return to competitive sports.<sup>8-10,12,13,15,17,20,25</sup> Treatment is almost always nonoperative; to our knowledge, only 1 study has reported on the long-term results of nonoperatively treated patients, and that study included 5 patients.<sup>20</sup>

While nonoperative treatment is preferred as the initial treatment option in most cases, McKinney et al<sup>12</sup> recommended surgical intervention for symptomatic nonunions and avulsions with a displacement greater than 2 cm. A recent meta-analysis of 596 patients with apophyseal avulsion fractures of the pelvis and hip reported better outcomes after surgical treatment in comparison with nonoperative treatment.<sup>3</sup> Furthermore, the study showed a higher return-to-sport rate and shorter interval before return to play after surgical treatment.<sup>3</sup> Khemka et al<sup>9</sup> reported a stable fixation and fast recovery with return to sports activities after surgical repair of the lesser trochanter in the adolescent. These results suggest that surgical repair for severe lesser trochanter avulsions may significantly improve patient outcomes and the ability to return to sport after injury. Despite a thorough review of the literature, we found no clinical randomized trial comparing surgical and nonsurgical treatment for lesser trochanter avulsions.

Unfortunately, no standard for surgical treatment of lesser trochanter avulsions has been established. Khemka et al<sup>9</sup> described an arthroscopic approach in a case series of 3 patients. Otto et al<sup>16</sup> recently developed a retrograde fixation technique with an adapted mini-open anterior approach that showed excellent clinical results in 2 representative cases. This adapted approach uses a modified Smith-Peterson exposure in combination with a lateral incision over the iliotibial tract to safely drill a transosseous canal through the avulsion fragment. The lesser trochanter fragment is reduced to its anatomic footprint and secured with a titanium cortical button against the lateral femoral cortex. Although the study by Otto et al was limited by a small sample size and short follow-up, results for this technique are promising.

The purpose of this study was to compare the biomechanical properties of anterograde fixation through use of titanium suture anchors with the novel retrograde fixation using a titanium cortical button in lesser trochanter avulsion repair. Hapa et al<sup>6</sup> showed higher load to failure and similar displacement for tibial eminence fracture fixations when comparing a metal button construct versus suture anchors. We expected comparable biomechanical effects for retrograde lesser trochanter fixation and hypothesized that

it will produce superior stability under load to failure as well as similar fragment displacement under cyclic loading compared with the anterograde technique.

## METHODS

Sixteen paired hemipelvic cadaveric specimens (Science Care) from 8 donors (age, 62.5 ± 10.7 years; 5 females, 3 males) were obtained. This study was reviewed via Human Research Determination Form by the institutional review board (IRB) of the University of Connecticut, and it was concluded that no IRB approval was required.

Specimens were placed supine, and the quadriceps, adductors, and hamstrings were reflected so that the lesser trochanter could be seen from the anteromedial aspect. The iliopsoas tendon was identified, and blunt dissection was performed to separate the musculotendinous unit from surrounding connective tissue. The iliopsoas muscle was followed superiorly past the inguinal ligament, where it was dissected from its vertebral and pelvic origins. The femur was then disarticulated from the acetabulum. All other soft tissue was carefully removed from the femur to isolate the insertion of the iliopsoas tendon into the lesser trochanter. The femur was cut 10 cm distal to the lesser trochanter with a handsaw and potted in 2-inch PVC with Bosworth Duz-All self-curing acrylic cement (Harry J. Bosworth Co). Dissected and potted specimens were stored in a freezer at -20°C. Specimens were thawed 24 hours in advance of biomechanical testing.

Bone mineral density at the lesser trochanter was evaluated through use of DEXAScan (XL Image Densitometer; GE/Lunar Expert) before biomechanical testing. Complete avulsion injuries were produced by osteotomy of the lesser trochanter at its base on the femur (Figure 1). Specimens were randomized in matched pairs to be fixed with either titanium suture anchors or Dog Bone cortical buttons (Arthrex).

### Suture Anchor Technique

The suture anchor technique was based on the technique published by Khemka et al.<sup>9</sup> Two 5.5 × 16.3-mm Corkscrew anchors preloaded with No. 2 FiberWire (Arthrex) sutures were placed at the upper and lower margins of the lesser trochanter bone bed at an angle of 120° to the femoral shaft axis (Figure 2A). Two 2-mm canals were drilled with K-wire of the corresponding size through the lesser trochanter

\*Address correspondence to Alexander Otto, MD, Department of Orthopaedic Surgery, UConn Musculoskeletal Institute, 263 Farmington Avenue, Farmington, CT 06030, USA (email: alexander.otto@tum.de).

†Department of Orthopaedic Surgery, UConn Musculoskeletal Institute, University of Connecticut, Farmington, Connecticut, USA.

‡Department of Orthopaedic Sports Medicine, Klinikum rechts der Isar, Technical University of Munich, Munich, Germany.

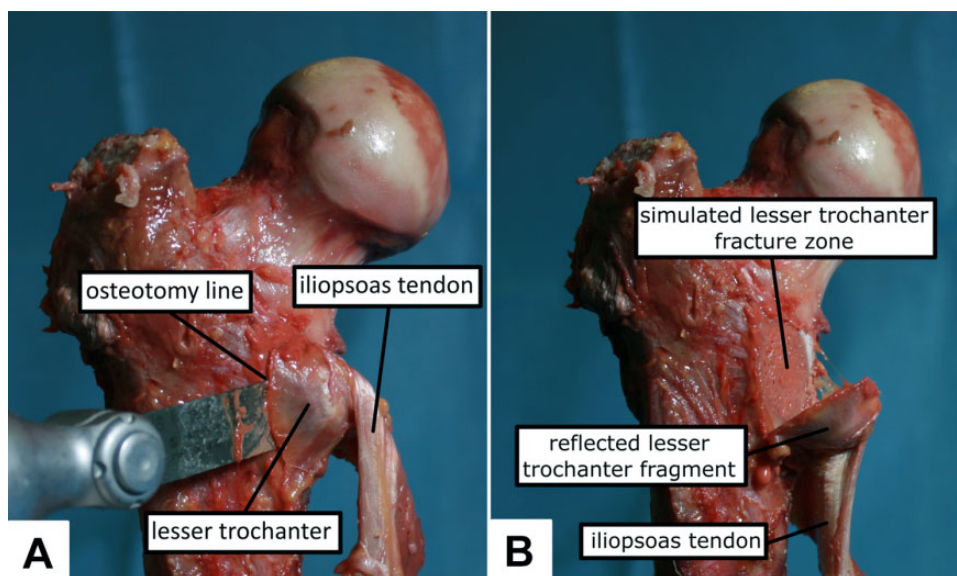
§Department of Trauma, Orthopaedic, Plastic and Hand Surgery, University Hospital of Augsburg, Augsburg, Germany.

||ATOS Orthoparc Klinik Köln, Cologne, Germany.

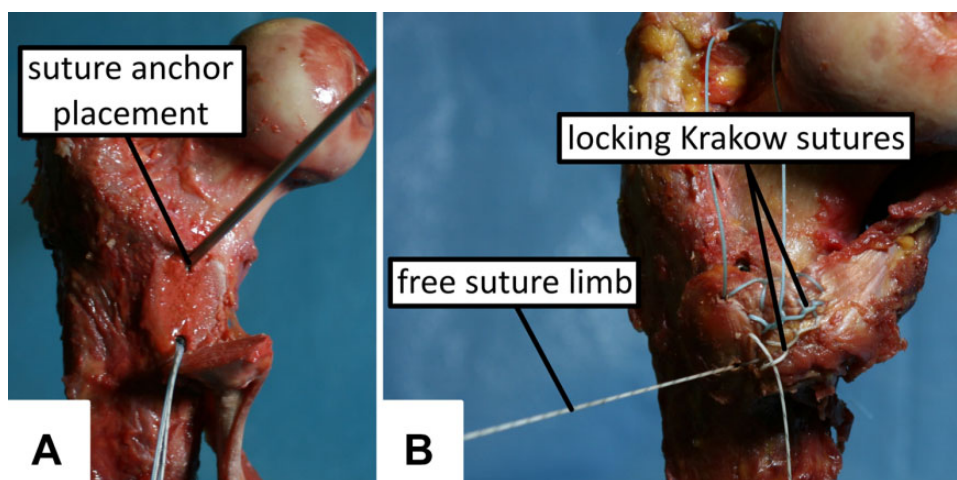
Final revision submitted October 15, 2019; accepted October 23, 2019.

One or more of the authors has declared the following potential conflict of interest or source of funding: The University of Connecticut Health Center/UConn Musculoskeletal Institute received direct funding and material support for this study from Arthrex. K.C. has received educational support from Arthrex and Pylant Medical, speaking fees from Arthrex, consulting fees from Johnson & Johnson, and hospitality payments from Biomet and Smith & Nephew. K.B. has received consulting fees from Arthrex. A.B.I. has received consulting fees from ArthroSurface, Arthrex, and Medi. A.D.M. has received grant support and consulting fees from Arthrex and honoraria from ArthroSurface. AOSSM checks author disclosures against the Open Payments Database (OPD). AOSSM has not conducted an independent investigation on the OPD and disclaims any liability or responsibility relating thereto.

Ethical approval for this study was waived by the University of Connecticut Institutional Review Board.



**Figure 1.** (A) Osteotomy at the base of the lesser trochanter. (B) Simulated complete lesser trochanter avulsion with preserved iliopsoas tendon.



**Figure 2.** (A) Anterograde repair with 2 titanium suture anchors. (B) The tendon was augmented with a locking Krakow suture pattern, allowing secure reduction of the lesser trochanter to its anatomic footprint.

fragment at the level of anchor placement. One suture end of each anchor was used to stitch a locking Krakow suture pattern 20 mm in length through the tendon of the iliopsoas (Figure 2B). The avulsion fragment was then reduced to its anatomic footprint by securely tying the stitching suture limb of each anchor to its corresponding free suture limb with 8 surgical knots.

#### Cortical Button Technique

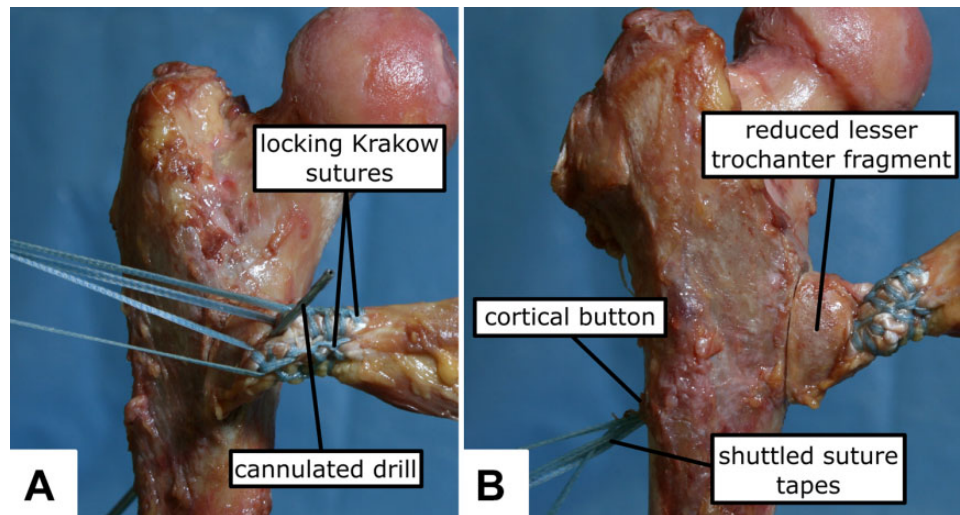
The cortical button technique was applied as described by Otto et al.<sup>16</sup> A transosseous canal was created from the lateral aspect of the femoral cortex with a 2.4-mm drill (Figure 3A). An aiming device was used to ensure an angle

of 120° to the longitudinal femoral axis while drilling and to ensure that the canal emerged from the center of the lesser trochanter. The tendon was stitched with 2 units of 2-mm FiberTape (Arthrex) in a locking Krakow suture pattern 20 mm in length. The tape ends were then shuttled through the transosseous canal to the lateral side of the femur (Figure 3B). The avulsion fragment was reduced to its anatomic footprint and securely fixed with a Dog Bone button serving as an abutment against the lateral femoral cortex.

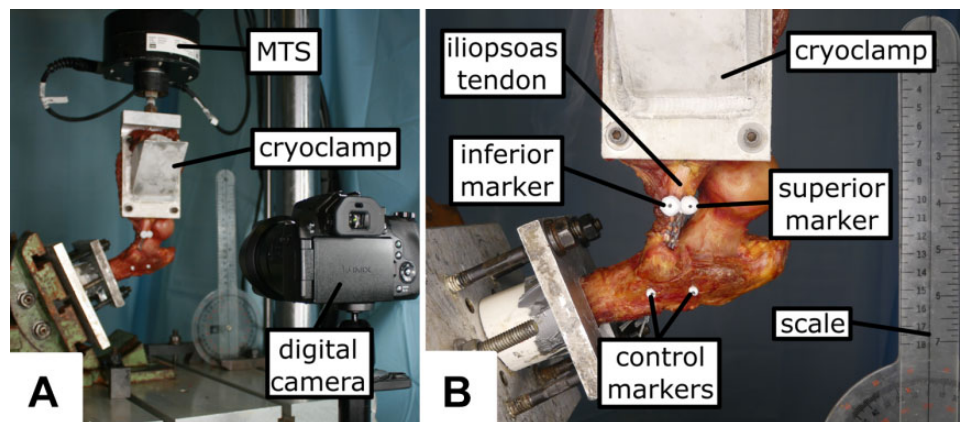
#### Biomechanical Testing

The biomechanical methods were adapted from the test setup published by Harvey et al.<sup>7</sup> Femurs were secured to





**Figure 3.** (A) Retrograde repair with a transosseous canal. (B) The tendon was stitched with a locking Krakow suture pattern, and the suture was secured with a cortical button as an abutment against the lateral femoral cortex.



**Figure 4.** (A) The iliopsoas tendon was securely connected with a cryoclamp to the material testing system (MTS) machine. (B) Optical tracking was performed with 4 markers.

the base of a material testing system machine (MTS 858 Mini-Bionix) with the iliopsoas tendon fibers in alignment (Figure 4A). The proximal psoas major muscle was secured at the myotendinous junction 3 cm from the end of the suture through use of a cryoclamp attached to a vertical loading actuator. Specimens were preloaded with 5 N and held for 5 seconds before being cyclically loaded from 10 N to 125 N at 1 Hz for 1500 cycles. Load to failure was performed after the last cycle at a constant rate of 120 mm/min. Displacement and force were measured at a resolution of 0.5 mm and 0.5 N. Mode of failure and peak load were recorded.

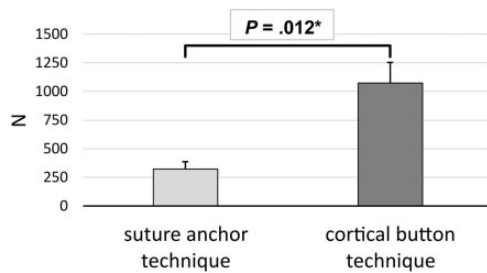
#### Motion Analysis

Repair construct displacement was measured by optical tracking with 4 markers as published by Harvey et al.<sup>7</sup> Two markers were placed superiorly and inferiorly along the breadth of the tendon 20 mm from the base of the lesser

trochanter and proximal to the end of the Krakow suture (Figure 4B). Control markers were placed on the femoral cortex in corresponding superior and inferior positions (Figure 4B). A Panasonic Lumix DMC-FZ300 digital camera with Leica DC Vario-Elmarit lens was used for video recording (Figure 4A). Specimen and scale were positioned at the same distance to the camera for each test run. Digital motion analysis was performed through use of Kinovea (Version 0.8.27; <http://www.kinovea.org>) to generate vertical position data from the cyclic loading recordings. Normalized displacements were determined for the superior and inferior markers by subtracting the displacement of the control markers from their corresponding tendon markers.

#### Statistical Analysis

Power analysis was performed by use of the outcome parameters published by Harvey et al.<sup>7</sup> A minimum sample size



**Figure 5.** Comparison of peak load at failure by repair technique. Data reported as means with SD (error bars). \*Statistically significant difference.

of 8 specimens per group was determined to provide 92.2% power to detect a 135-N difference in load to failure at an  $\alpha$  of .05. Biomechanical outcomes data were assessed for normality by evaluation of their distributions. Given continuous variables and skewed distributions, the nonparametric Wilcoxon signed-rank test was used to determine whether a statistically significant difference in outcomes between matched pairs existed. Correlation between continuous variables was assessed with Spearman rho. All statistical analyses were performed with SPSS 25 (IBM).

## RESULTS

Bone mineral density did not significantly differ between the specimens repaired with titanium suture anchors ( $1.11 \pm 0.30 \text{ g/cm}^2$ ) and specimens repaired with cortical button ( $1.00 \pm 0.22 \text{ g/cm}^2$ ;  $P = .263$ ).

After 1500 cycles, the mean displacement at the superior marker was  $4.39 \pm 4.50 \text{ mm}$  for the titanium suture anchor group and  $3.29 \pm 1.84 \text{ mm}$  for the cortical button group ( $P = .779$ ). The mean displacement of the inferior marker was  $4.22 \pm 4.48$  and  $3.54 \pm 2.13 \text{ mm}$  ( $P = .779$ ), respectively.

The mean peak load at failure was  $321.85 \pm 62.45 \text{ N}$  for the titanium suture anchor group and  $1075.24 \pm 179.39 \text{ N}$  for the cortical button group ( $P = .012$ ) (Figure 5). Mode of failure was tendon tearing by the sutures for the retrograde repair and anchor pullout for the anterograde repair.

The stiffness of the anterograde repair construct ( $69 \pm 23 \text{ N/mm}$ ) and the retrograde repair construct ( $59 \pm 10 \text{ N/mm}$ ) did not significantly differ ( $P = .161$ ).

Spearman rank correlation showed a significant negative association between bone mineral density and stiffness for the anterograde repair construct ( $\rho = -0.762$ ;  $P = .028$ ). No other significant pairwise correlations were found between bone mineral density, displacement, load to failure, or stiffness for either repair.

## DISCUSSION

The most important finding of this study was that retrograde repair of lesser trochanter avulsions with a titanium cortical button showed a significantly greater peak load at failure compared with anterograde suture anchor repair.

Furthermore, neither stiffness nor displacement significantly differed between cohorts, indicating that both repair constructs provided comparable resistance. These results show that the retrograde cortical button repair technique provides higher primary stability.

At present, no established threshold is available for displacement in lesser trochanter avulsion repairs that would indicate failure. Biomechanical studies of rotator cuff and distal biceps repairs have set the threshold for failure between 5 and 10 mm of displacement of the bone-tendon unit.<sup>2,18,24,26</sup> Although the different musculotendinous complexes and surgical methods may confound direct comparisons, the mean displacement values for both repair techniques in this study fall below the lower critical value for rotator cuff and distal biceps repairs. Both repairs showed displacements of the lesser trochanter fragment less than the 20-mm threshold indicating operative treatment.<sup>12</sup> These observations suggest that the retrograde and anterograde techniques provide adequate resistance to failure under cyclic loading conditions.

A correlation analysis showed a significant negative correlation between bone mineral density and stiffness for the anterograde repair construct. We interpret this correlation as rather unlikely, since this suggests that higher bone mineral density, which should enhance the engagement of the suture anchor and bone, leads to a reduced stiffness of the overall repair construct. Given that no other correlations between bone mineral density, displacement, load to failure, or stiffness for either repair were present, this negative correlation was regarded as not clinically relevant.

Otto et al<sup>16</sup> reported the clinical results of this technique in a case series including 2 young male patients. The first patient, evaluated 13 months after surgery, had a Harris Hip Score (HHS) of 96 and a Hip disability and Osteoarthritis Outcome Score (HOOS) of 99.4. The second patient, evaluated 6 months after surgery, had an HHS of 100 and HOOS of 95.0. No significant complications were reported for either patient. These findings were limited by a small sample size and short-term follow-up.

The majority of pelvic and hip apophyseal avulsion fractures are managed nonoperatively.<sup>3,4,10,12,14,20-23</sup> However, surgical management for apophyseal avulsion injuries may be indicated for fragments displaced more than 2 cm, painful nonunion, inability to return to sports, and exostosis formation.<sup>12,19,21,22</sup> Excellent results have been reported for surgical intervention of pelvic apophyseal avulsion fractures compared with nonoperative treatment.<sup>3,23</sup> Khemka et al<sup>9</sup> published the results of their case series using an arthroscopic technique with a medial portal. After a mean follow-up of 16 months, all 3 patients demonstrated radiographic evidence of recovery. Range of motion and level of activity returned to baseline, with transient medial numbness being reported for 1 patient. These results are encouraging, but this technique is very demanding given the proximity of critical neurovascular structures, which increases the risk of postoperative sequelae.

This is the first biomechanical study to compare different techniques for lesser trochanter avulsion repair. A validated biomechanical setup was adapted to measure the

properties of retrograde and anterograde repair techniques.<sup>7</sup> The Kinovea software that was used for motion tracking analysis has also been shown to be highly reliable.<sup>5</sup> However, several limitations should be kept in mind. The use of cadaveric specimens precludes any assessment of the biological effects of healing and the physiological effects of loading on the repair site. Nevertheless, specimens were pairwise randomized, and no significant difference was noted between bone mineral density between groups. Despite similar group features, the current results might be limited by the specimens' age and bone mineral density, as higher failure loads are assumed in adolescent patients because of expected higher bone mineral density. However, the bone mineral density of the specimens tested in the current study lies within the range of intertrochanteric bone mineral density (0.9-1.1 g/cm<sup>3</sup>) of adolescent males and females between the ages of 12 and 18 years.<sup>11</sup> Consequently, the biomechanical testing has been performed on representative specimens, and the difference between specimens' and patients' ages might be negligible. Biomechanical measurements may have been influenced by specimen slippage during testing, but this is unlikely given the experimental setup (eg, cryoclamps) and the use of optical motion analysis to normalize displacement values. Finally, although No. 2 FiberWire was used in the anterograde repair and 2-mm FiberTape was used in the retrograde repair, this difference is not likely to have influenced our results. An in vitro animal study by Bisson and Manohar<sup>1</sup> demonstrated no difference between No. 2 FiberWire suture and 2-mm FiberWire tape in elongation or stiffness. Despite these limitations, the current biomechanical results and the clinical results of Otto et al<sup>16</sup> suggest that retrograde fixation is a safe and biomechanically superior treatment for lesser trochanter avulsion. Further randomized clinical studies are needed to support these results.

## CONCLUSION

The surgical repair of lesser trochanter avulsion fractures with a retrograde fixation technique demonstrated superior load to failure compared with an anterograde fixation technique. The retrograde approach provides a biomechanically validated alternative to other surgical techniques for this injury.

## REFERENCES

- Bisson LJ, Manohar LM. A biomechanical comparison of the pullout strength of No. 2 FiberWire suture and 2-mm FiberWire tape in bovine rotator cuff tendons. *Arthroscopy*. 2010;26(11):1463-1468.
- Burkhart SS, Diaz Pagan JL, Wirth MA, Athanasiou KA. Cyclic loading of anchor-based rotator cuff repairs: confirmation of the tension overload phenomenon and comparison of suture anchor fixation with transosseous fixation. *Arthroscopy*. 1997;13(6):720-724.
- Eberbach H, Hohloch L, Feucht MJ, Konstantinidis L, Südkamp NP, Zwingmann J. Operative versus conservative treatment of apophyseal avulsion fractures of the pelvis in the adolescents: a systematical review with meta-analysis of clinical outcome and return to sports. *BMC Musculoskelet Disord*. 2017;18(1):162.
- Fernbach SK, Wilkinson RH. Avulsion injuries of the pelvis and proximal femur. *AJR Am J Roentgenol*. 1981;137(3):581-584.
- Grigg J, Haakonssen E, Rathbone E, Orr R, Keogh JWL. The validity and intra-tester reliability of markerless motion capture to analyse kinematics of the BMX Supercross gate start. *Sports Biomech*. 2018;17(3):383-401.
- Hapa O, Barber FA, Süner G, et al. Biomechanical comparison of tibial eminence fracture fixation with high-strength suture, EndoButton, and suture anchor. *Arthroscopy*. 2012;28(5):681-687.
- Harvey MA, Singh H, Obopilwe E, Charette R, Miller S. Proximal hamstring repair strength: a biomechanical analysis at 3 hip flexion angles. *Orthop J Sports Med*. 2015;3(4):2325967115576910.
- Homma Y, Baba T, Ishii S, Matsumoto M, Kaneko K. Avulsion fracture of the lesser trochanter in a skeletally immature freestyle footballer. *J Pediatr Orthop B*. 2015;24(4):304-307.
- Khemka A, Raz G, Bosley B, Ludger G, Al Muderis M. Arthroscopically assisted fixation of the lesser trochanter fracture: a case series. *J Hip Preserv Surg*. 2014;1(1):27-32.
- Kocher MS, Tucker R. Pediatric athlete hip disorders. *Clin Sports Med*. 2006;25(2):241-253.
- Lee S-H, Desai SS, Shetty G, et al. Bone mineral density of proximal femur and spine in Korean children between 2 and 18 years of age. *J Bone Miner Metab*. 2007;25(6):423-430.
- McKinney BI, Nelson C, Carrion W. Apophyseal avulsion fractures of the hip and pelvis. *Orthopedics*. 2009;32(1):42.
- McMillan T, Rehman H, Mitchell M. Lesser trochanter avulsion fracture in an adolescent after seizure. *J Emerg Med*. 2016;51(4):457-460.
- Moeller JL. Pelvic and hip apophyseal avulsion injuries in young athletes. *Curr Sports Med Rep*. 2003;2(2):110-115.
- Obi NJ, Allman C, Moore-Thompson E, Latimer MD. Sequential bilateral lesser trochanter avulsion fractures in an adolescent patient. *BMJ Case Rep*. 2014;2014:bcr2014207911.
- Otto A, Banke IJ, Mehl J, Beitzel K, Imhoff AB, Scheiderer B. Retrograde fixation of the lesser trochanter in the adolescent: new surgical technique and clinical results of two cases. *Arch Orthop Trauma Surg*. 2019;139(4):537-545.
- Papacostas NC, Bowe CT, Shaffer Strout TD. Lesser trochanter avulsion fracture. *J Emerg Med*. 2013;45(2):256-257.
- Pereira DS, Kvitne RS, Liang M, Giacobetti FB, Ebramzadeh E. Surgical repair of distal biceps tendon ruptures: a biomechanical comparison of two techniques. *Am J Sports Med*. 2002;30(3):432-436.
- Rajasekhar C, Kumar KS, Bhamra MS. Avulsion fractures of the anterior inferior iliac spine: the case for surgical intervention. *Int Orthop*. 2001;24(6):364-365.
- Ruffing T, Rückauer T, Bludau F, Hofmann A, Muhm M, Suda AJ. Avulsion fracture of the lesser trochanter in adolescents. *Injury*. 2018;49(7):1278-1281.
- Schuetz DJ, Bomar JD, Pennock AT. Pelvic apophyseal avulsion fractures: a retrospective review of 228 cases. *J Pediatr Orthop*. 2015;35(6):617-623.
- Serbest S, Tosun HB, Tiftikçi U, Oktas B, Kesgin E. Anterior inferior iliac spine avulsion fracture: a series of 5 cases. *Medicine (Baltimore)*. 2015;94(7):e562.
- Singer G, Eberl R, Wegmann H, Marterer R, Kraus T, Sorantin E. Diagnosis and treatment of apophyseal injuries of the pelvis in adolescents. *Semin Musculoskelet Radiol*. 2014;18(5):498-504.
- Spang JT, Weinhold PS, Karas SG. A biomechanical comparison of EndoButton versus suture anchor repair of distal biceps tendon injuries. *J Shoulder Elbow Surg*. 2006;15(4):509-514.
- Vazquez E, Kim TY, Young TP. Avulsion fracture of the lesser trochanter: an unusual cause of hip pain in an adolescent. *CJEM*. 2013;15(2):123-125.
- Waltrip RL, Zheng N, Dugas JR, Andrews JR. Rotator cuff repair: a biomechanical comparison of three techniques. *Am J Sports Med*. 2003;31(4):493-497.