

Ultrasound detection of vagus nerve atrophy in bulbar amyotrophic lateral sclerosis

Korbinian Holzapfel, Markus Naumann

Angaben zur Veröffentlichung / Publication details:

Holzapfel, Korbinian, and Markus Naumann. 2020. "Ultrasound detection of vagus nerve atrophy in bulbar amyotrophic lateral sclerosis." *Journal of Neuroimaging* 30 (6): 762–65.
<https://doi.org/10.1111/jon.12761>.

Ultrasound Detection of Vagus Nerve Atrophy in Bulbar Amyotrophic Lateral Sclerosis

Korbinian Holzapfel , Markus Naumann

Department of Neurology and Clinical Neurophysiology, University of Augsburg, Augsburg, Germany

ABSTRACT

BACKGROUND AND PURPOSE: Neuromuscular ultrasound in amyotrophic lateral sclerosis (ALS) is of increasing interest. As bulbar symptoms are commonly developed by most ALS patients during disease, the aim of our study was to find possible sonographic changes of vagus nerve size in bulbar affected ALS patients.

METHODS: We investigated 24 ALS patients and 19 controls without neuromuscular disorders. In ALS patients, bulbar affection was documented clinically (eg, dysarthria, dysphagia, and fasciculations) or subclinically using ultrasound and electromyography of bulbar muscles. Vagus nerve ultrasound was performed in all participants bilaterally at the level of the thyroid gland.

RESULTS: The cross-sectional area (CSA) of the vagus nerve in bulbar affected ALS patients (mean CSA right/left $1.9 \pm .7 \text{ mm}^2/1.8 \pm .6 \text{ mm}^2$) was significantly reduced on both sides compared to controls (mean CSA right/left $2.2 \pm .6 \text{ mm}^2/2.0 \pm .3 \text{ mm}^2$) – right: $P = .0387$, left: $P = .0386$. Receiver operating characteristic curve analysis of the vagus nerve CSA yielded a sensitivity of 66.7% and a specificity of 63.2% (cutoff value 1.85 mm^2). Vagus nerve CSA did not correlate significantly with age in controls (right: $P = .45$, left: $P = .66$). In controls and ALS patients, there was no significant difference of vagus nerve CSA between the right and left sides (controls: $P = .43$; patients: $P = .86$).

CONCLUSION: Our study demonstrates vagus nerve atrophy in bulbar affected ALS patients. Further studies are warranted investigating the relevance of our finding for monitoring disease progression in ALS.

Keywords: Amyotrophic lateral sclerosis, vagus nerve, neuromuscular ultrasound.

Acceptance: Received May 11, 2020, and in revised form June 18, 2020. Accepted for publication June 29, 2020.

Correspondence: Address correspondence to Dr. Korbinian Holzapfel, Department of Neurology and Clinical Neurophysiology, Universitätsklinikum Augsburg, Stenglinstr. 2, 86156 Augsburg, Germany. E-mail: korbinian.holzapfel@klinikum-augsburg.de.

Acknowledgment and Disclosure: The authors report no conflict of interests and have nothing to disclose. Open access funding enabled and organized by Projekt DEAL.

J Neuroimaging 2020;30:762–765.

DOI: 10.1111/jon.12761

Introduction

Amyotrophic lateral sclerosis (ALS) is a neuromuscular disorder affecting motor neurons of the spinal cord, lower brainstem, and cerebral cortex.

Involvement of bulbar muscles is commonly identified by needle electromyography (EMG) of several muscles, including the genioglossus, sternocleidomastoid, upper trapezius, and frontalis muscle.¹ Additionally, muscle ultrasound (MUS) has proved to be a useful tool for the detection of fasciculations, but the detection of bulbar involvement in ALS may still be difficult.^{2,3} Nerve ultrasound (NUS) has been useful in the distinction of ALS from multifocal motor neuropathy and in quantifying disease progression.^{4,5} Vagus nerve sonography could be a valuable tool in diagnosing bulbar ALS patients as it may reflect degeneration of motor fibers supplying pharyngeal and laryngeal muscles. As there is preliminary sonographic evidence from a case report that the vagus nerve is reduced in size in ALS patients with bulbar involvement, the aim of present study was to confirm possible changes in the vagus nerve size in a series of bulbar affected ALS patients.⁶ This study could be the basis for further research of vagus nerve changes in ALS patients as

a possible marker of disease progression as vagus NUS is easy to perform.

Methods

Participants

Between May 2017 and December 2019, 24 patients (mean age: 64 years) referred for evaluation of ALS to the Department of Neurology and Clinical Neurophysiology, University of Augsburg, Germany, were examined. Patients were classified by clinical, electrophysiological, and ultrasound examinations according to the Awaji criteria.⁷ Disease duration reached from 2 to 48 months. Ten patients already had clinical signs of bulbar involvement (such as bulbar dysarthria and dysphagia), 14 patients had no bulbar symptoms clinically but were affected based on pathologic MUS and EMG. Extensive clinical, laboratory, and imaging examinations were performed to exclude patients with other differential diagnoses. For detecting bulbar involvement, the patients underwent EMG studies (genioglossus and frontalis muscle), MUS of the floor of the mouth, and vagus NUS. A group of 19 subjects with other neurological

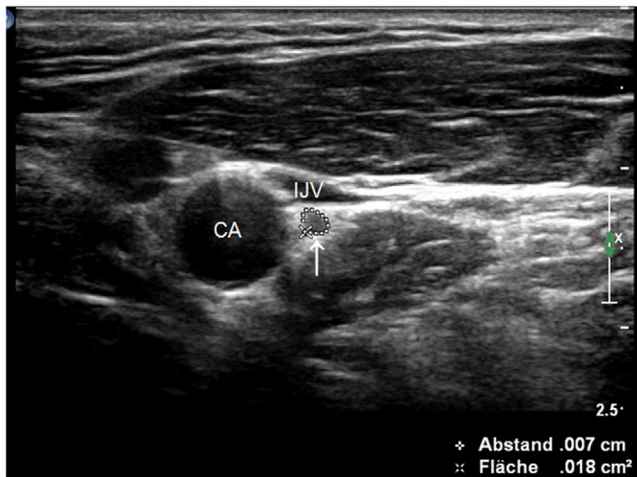


Fig 1. Axial scan of the vagus nerve. Axial scan of the vagus nerve laterally to the carotid artery and dorsally to the internal jugular vein within the carotid sheath. CSA = 1.8 mm². CA, carotid artery; IJV, internal jugular vein.

diseases (headache, epilepsy, and transitory ischemic attack) and without a history of neuromuscular disorders served as controls. Controls were selected age-matched as a correlation of vagus nerve size and age has been shown previously.⁸ Subjects with diagnosed diabetes mellitus or injuries of the neck were excluded. The study was approved by the ethics committee of the University of Augsburg. All participants provided written informed consent.

To evaluate the degree of functional impairment, the ALS Functional Rating Scale (ALSFRS-R, 0 = worst, 48 = best) was performed for each patient as well as the bulbar subscale of the ALSFRS-R assessing bulbar impairment (0 = worst, 12 = best).^{9,10}

EMG, Vagus Nerve Ultrasound, and Muscle Ultrasound

For EMG studies, we used a Schwarzer Topas EMG (Natus Europe, Planegg, Germany). An experienced electromyographer performed all EMG examinations with a concentric needle electrode using standard settings and bandpass of 20 Hz-10 kHz with an amplifier sensitivity of 100 μ V/division.¹

For evaluation of bulbar involvement, the frontalis muscle and the tongue were examined according to Pan et al.¹

Ultrasound examinations were performed by an experienced examiner using a Philips IU22 ultrasound machine with a 17-MHz linear-array transducer. Sonography of the floor of the mouth was performed visualizing in a transverse view the digastric muscle, mylohyoid muscle, geniohyoid, and genioglossus muscle, as well as the base of the tongue. The fasciculations on ultrasound were classified as involuntary twitching of small parts of the muscle lasting for .2-.5 seconds according to O'Gorman et al.³ Exploration time was 90 seconds. The presence of fasciculations was defined by the detection of more than two fasciculations during scantime.

Vagus NUS was performed using the same ultrasound device and a linear-array transducer (17 MHz) as in MUS. The cross-sectional area (CSA) of the right and left vagus nerves was measured at the level of the thyroid gland in the carotid sheath.⁸ As anatomic landmarks, the carotid artery and the

Table 1. Demographic and Clinical Data of the Participants

Parameter	Controls (n = 19)	Patients (n = 24)
Sex (male); n (%)	13 (68.4%)	16 (66.7%)
Age (years)	63.05 \pm 11.07	64.04 \pm 9.98
Disease duration (months)	NA	12.46 \pm 10.28
Bulbar symptoms; n (%)	NA	10 (41.7%)
ALSFRS-R	NA	41.63 \pm 5.03
ALSFRS-R bulbar	NA	10.46 \pm 2.43

Note: Age, disease duration, ALSFRS-R, and ALSFRS-R bulbar data are presented as mean \pm standard deviation, unless otherwise indicated. Sex and bulbar affection are presented as number (percentage). n, number of subjects; NA, not applicable.

Table 2. Vagus Nerve Cross-Sectional Area (mm²) in Controls and Patients

	Vagus nerve, right thyroid			Vagus nerve, left thyroid		
	Maximum	Minimum	Mean \pm SD	Maximum	Minimum	Mean \pm SD
Controls (n = 19)	3.5	1.5	2.2 \pm .6	2.6	1.5	2.0 \pm .3
ALS patients (n = 24)	4.0	.9	1.9 \pm .7	4.0	1.2	1.8 \pm .6
P	P = .0387 (s)			P = .0386 (s)		

Note: P-values \leq .05 for comparisons between controls and patients were considered statistically significant. SD, standard deviation; s, significant; n, number of subjects.

internal jugular vein were used (Fig 1). The nerves were scanned by the author in the supine position in axial planes. CSA was traced inside the (hyper)echogenic epineural rim of the nerve. At all sites, CSA was measured three times, and values were averaged.

Statistical Analysis

For statistical analysis, GraphPad Prism 4 software was used. Means and standard deviation of the vagus nerve CSA were determined. The Mann-Whitney U-test was performed to compare controls and patients and ALS patients with and without bulbar symptoms. Statistical significance was defined as $P \leq .05$.

Pearson correlation coefficient was calculated to correlate CSA measurements with the age of controls. P-values were calculated by Pearson correlation test and $P \leq .05$ was considered statistically significant.

To show the diagnostic accuracy of vagus NUS in differentiating controls and patients, a receiver operating characteristic (ROC) curve was used for the right vagus nerve.

Results

The study included 24 patients with bulbar ALS and 19 healthy volunteers. The degree of functional impairment reached from 24 to 49 in the ALSFRS-R (mean: 41.6), bulbar affection reached from 12 (only affected in EMG and MUS) to 2 (mean: 10.5) in the ALSFRS-R bulbar subscore. Table 1 shows some clinical and demographic data of patients and controls. In controls, vagus nerve CSA did not correlate significantly with age (right: $P = .45$, left: $P = .66$).

Table 2 shows the results of the CSA values of the vagus NUS. In both, controls and ALS patients, vagus nerve CSA was

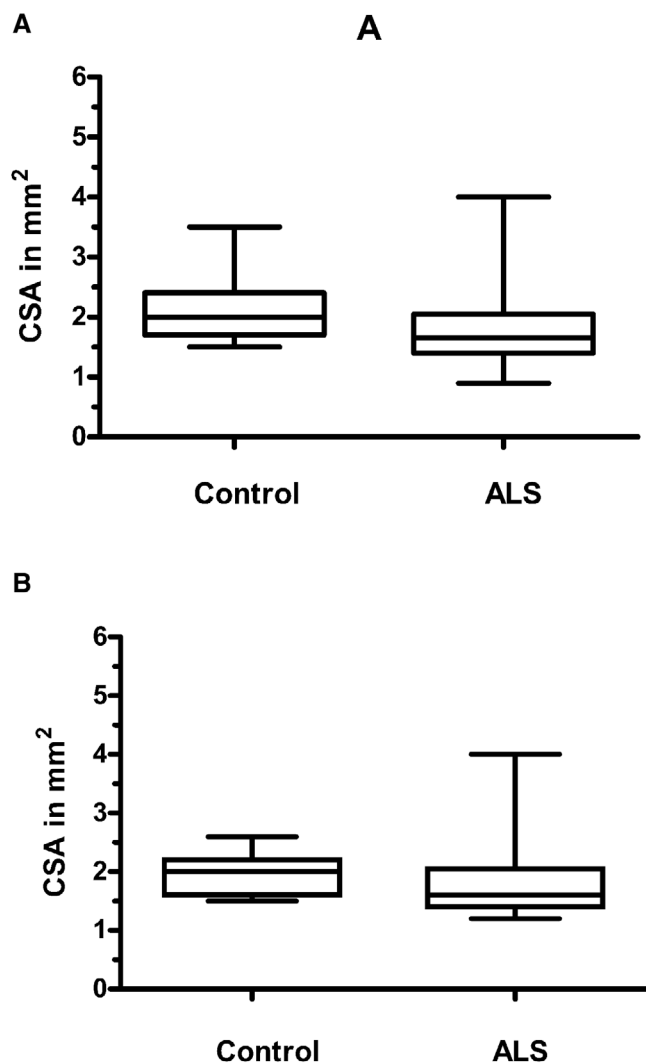


Fig 2. Box plots of the cross-sectional area of the vagus nerve at the level of the thyroid gland. A: right side; B: left side. The data show the CSA in controls and patients with amyotrophic lateral sclerosis (ALS) at the level of the right (A) and the left (B) thyroid gland. Median (line at the middle), 25th-75th percentiles (box), and range (error bars) are shown. *P*-value (*P* = .0387 on the right and *P* = .0386 on the left side) indicates significance level for the comparison of patients and controls. Significance was set at $P \leq .05$.

slightly but nonsignificantly larger on the right compared to the left side (controls: *P* = .43; patients: *P* = .86).

Figure 2 shows the box plots of the CSA of the vagus nerve at the level of the right (A) and the left (B) thyroid gland in patients and controls. The CSA of the right and left vagus nerves was significantly smaller in patients compared to controls (right side: *P* = .0387, left side: *P* = .0386).

There was no significant difference between ALS patients with and without bulbar symptoms in vagus nerve CSA on both sides (*P* = .0532 on the right, *P* = .2779 on the left).

ROC curve analysis of the vagus nerve CSA showed low diagnostic accuracy of vagus NUS (AUC = .69, Fig 3). A cutoff value of < 1.85 mm² resulted in a sensitivity of 66.7% and a specificity of 63.2%. A cutoff value of < 1.55 mm² showed a specificity of 94.7% (sensitivity: 37.5%).

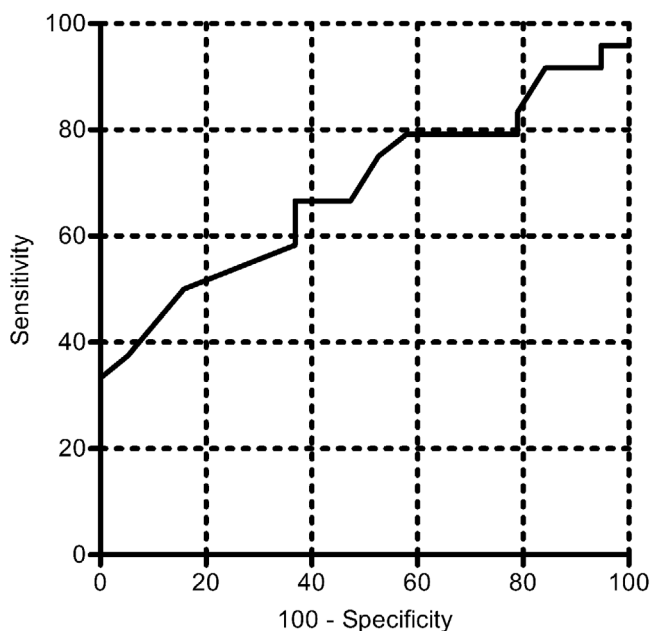


Fig 3. ROC curve for vagus nerve ultrasound. Area under the ROC curve: .69 (low accuracy), *P*-value .03769. A cutoff value for the vagus nerve CSA of 1.85 mm² yielded a sensitivity of 66.7% and a specificity of 63.2%. ROC, receiver-operator characteristic; CSA, cross-sectional area.

Discussion

In our study, we could show vagal atrophy in exclusively bulbar affected ALS patients. CSA of the vagus nerve was significantly reduced compared to controls at the level of the thyroid gland on both sides.

Bulbar involvement was detected by an elaborate protocol combining needle EMG and ultrasound for the detection of fasciculations as demonstrated by Kido et al also including the frontalis muscle to increase diagnostic accuracy, as patients are able to relax this muscle more easily than the tongue in EMG studies.^{1,11} Bulbar MUS has proved to be useful for the assessment of upper neuron involvement, and fasciculations became part of the diagnostic criteria of ALS in 2008.^{3,7,12}

To our knowledge, this is the first study of vagus NUS in a series of exclusively bulbar affected ALS patients confirming preliminary data from a single case report that showed a markedly reduced vagus nerve diameter in an exclusively bulbar-affected patient (CSA: 1 mm² on both sides).⁶ Grimm et al examined CSA in a group of 17 ALS patients and controls and reported a trend toward lower CSA values in ALS patients; however, no significant difference was found.⁴ As they did not provide specific information about bulbar involvement or disease severity, these data cannot be easily compared to our results.

In healthy subjects, vagus NUS was examined by Pelz et al and reference values were determined at the level of the thyroid gland. CSA values of our controls at the level of the thyroid gland were comparable to their healthy subjects older than 50 years (range: 50-76 years; our controls: range 42-87 years, mean age of 63 years).⁸ Higher values for vagus nerve CSA as reported by Cartwright et al may be explained by different study cohorts as discussed by Pelz et al.^{8,13}

There is no clear evidence whether vagus nerve size varies with age. We did not find a significant correlation between vagus nerve size and age in our controls (mean age: 63 years), which is in line with the study by Walter et al (mean age: 45 years) investigating vagal atrophy in Parkinson patients and healthy subjects.¹⁴ Although there was a trend to smaller nerve CSAs with increasing age, the difference was statistically not significant. In contrast, Pelz et al reported a significant and negative correlation between vagus nerve size and age (mean age: 49 years).⁸

A possible explanation of the vagal atrophy could be a degeneration of motor fibers originating in the brainstem (nucleus ambiguus) and supplying pharyngeal and laryngeal muscles in bulbar affected ALS patients. Brainstem degeneration has been described a pathognomonic feature in most motoneuron diseases as shown, for example, by MRI morphometric studies.¹⁵ As the autonomic nervous system does not show major involvement in ALS patients, atrophy of autonomic nerve fibers (as shown, eg, in diabetes patients) is unlikely the reason for vagal nerve atrophy.^{16,17}

ROC curve analysis of vagus NUS revealed low accuracy. A cutoff value of vagus nerve CSA of 1.85 mm² achieved a sensitivity of 66.7% and a specificity of 63.2%. Higher accuracy maybe achieved, including more severely affected patients revealing more vagal atrophy. In our study, we examined relatively mild affected patients as can be seen in the ALSFRS-R (mean 41.63) and ALSFRS-R bulbar subscale (mean 10.46). Additionally, disease duration was short (mean: 12.46 months). In order to avoid these limitations, further studies are warranted investigating a higher proportion of patients with lower scores, with longer disease duration and increasing the number of patients in general. In our study, there was also no significant difference in vagus nerve CSA between patients with and without clinical signs of bulbar involvement. Future studies will show whether more severely bulbar affected patients exhibit a more pronounced vagus nerve atrophy.

A limitation of our study could be that ultrasound was only performed by a single experienced sonographer. However, Pelz et al have shown in a previous study that vagus nerve measurement at the level of thyroid gland has high interrater reliability.⁸ Blinding to clinical findings or EMG was difficult as many of our patients had obvious signs of a motor neuron disorder, including weakness and muscle atrophy.

Another limitation of our study is that patients were only investigated at a time. In our study, marked vagal atrophy (< 1.55 mm²) was observed in some patients without bulbar symptoms. Observation over a longer period of time will be necessary to show if these patients reveal a faster disease progression.

In conclusion, bulbar ALS completes the spectrum of disorders associated with vagus nerve atrophy beyond Parkinson's disease and diabetes mellitus.^{14,17} In order to investigate a possible correlation between vagal nerve and brainstem atrophy, further studies combining NUS and MRI should be performed.

References

1. Pan H, Jian F, Lin J, et al. Needle electromyography of the frontalis muscle in patients with amyotrophic lateral sclerosis. *Muscle Nerve* 2016;54:1093-6.
2. Johansson MT, Ellegaard HR, Tankisi H, et al. Fasciculations in nerve and muscle disorders – a prospective study of muscle ultrasound compared to electromyography. *Clin Neurophysiol* 2017;128:2250-7.
3. O'Gorman CM, Weikamp JG, Baria M, et al. Detecting fasciculations in cranial nerve innervated muscles with ultrasound in amyotrophic lateral sclerosis. *Muscle Nerve* 2017;56:1072-6.
4. Grimm A, Decard BF, Athanasopoulou I, et al. Nerve ultrasound for differentiation between amyotrophic lateral sclerosis and multifocal motor neuropathy. *J Neurol* 2015;262:870-80.
5. Schreiber S, Dannhardt-Stieger V, Henkel D, et al. Quantifying disease progression in amyotrophic lateral sclerosis using peripheral nerve sonography. *Muscle Nerve* 2016;54:391-7.
6. Tawfik EA. Vagus nerve ultrasound in a patient with amyotrophic lateral sclerosis. *Muscle Nerve* 2016;54:978-9.
7. de Carvalho M, Dengler R, Eisen A, et al. Electrodiagnostic criteria for diagnosis of ALS. *Clin Neurophysiol* 2008;119:497-503.
8. Pelz JO, Belau E, Henn P, et al. Sonographic evaluation of the vagus nerves: protocol, reference values, and side-to-side differences. *Muscle Nerve* 2018;57:766-71.
9. Cedarbaum JM, Stambler N, Malta E, et al. The ALSFRS-R: a revised ALS functional rating scale that incorporates assessments of respiratory function. BDNF ALS Study Group (Phase III). *J Neurol Sci* 1999;169:13-21.
10. Smith RA, Macklin EA, Myers KJ, et al. Assessment of bulbar function in amyotrophic lateral sclerosis: validation of a self-report scale (Center for Neurologic Study Bulbar Function Scale). *Eur J Neurol* 2018;25:907-e66.
11. Kido M, Fujisaki N, Miyagi T, et al. Complimentary use of needle electromyography and ultrasonography of tongue is effective for early detection of abnormality in 20 patients with amyotrophic lateral sclerosis. *Rinsho Shinkeigaku* 2017;57:681-4.
12. Noto YI, Shibuya K, Shahrizaila N, et al. Detection of fasciculations in amyotrophic lateral sclerosis: the optimal ultrasound scan time. *Muscle Nerve* 2017;56:1068-71.
13. Cartwright MS, Passmore LV, Yoon J, et al. Cross-sectional area reference values for nerve ultrasonography. *Muscle Nerve* 2008;37:566-71.
14. Walter U, Tsiiberidou P, Kersten M, et al. Atrophy of the vagus nerve in Parkinson's disease revealed by high-resolution ultrasonography. *Front Neurol* 2018;9:805.
15. Bede P, Chipika RH, Finegan E, et al. Progressive brainstem pathology in motor neuron diseases: imaging data from amyotrophic lateral sclerosis and primary lateral sclerosis. *Data Brief* 2020;29:105229.
16. Oey PL, Vos PE, Wieneke GH, et al. Subtle involvement of the sympathetic nervous system in amyotrophic lateral sclerosis. *Muscle Nerve* 2002;25:402-8.
17. Tawfik EA, Walker FO, Cartwright MS, et al. Diagnostic ultrasound of the vagus nerve in patients with diabetes. *J Neuroimaging* 2017;27:589-93.