

Differential in situ expression of IL-17 in skin diseases

Mattias Fischer-Stabauer, Alexander Boehner, Stefanie Eyerich, Teresa Carbone, Claudia Traidl-Hoffmann, Carsten B. Schmidt-Weber, Andrea Cavani, Johannes Ring, Ruediger Hein, Kilian Eyerich

Angaben zur Veröffentlichung / Publication details:

Fischer-Stabauer, Mattias, Alexander Boehner, Stefanie Eyerich, Teresa Carbone, Claudia Traidl-Hoffmann, Carsten B. Schmidt-Weber, Andrea Cavani, Johannes Ring, Ruediger Hein, and Kilian Eyerich. 2012. "Differential in situ expression of IL-17 in skin diseases." *European Journal of Dermatology* 22 (6): 781–84. <https://doi.org/10.1684/ejd.2012.1854>.

Nutzungsbedingungen / Terms of use:

licgercopyright

Dieses Dokument wird unter folgenden Bedingungen zur Verfügung gestellt: / This document is made available under these conditions:

Deutsches Urheberrecht

Weitere Informationen finden Sie unter: / For more information see:

<https://www.uni-augsburg.de/de/organisation/bibliothek/publizieren-zitieren-archivieren/publiz/>



Mattias FISCHER-STABAUER^{1,a}
Alexander BOEHNER^{2,a}
Stefanie EYERICH²
Teresa CARBONE³
Claudia TRAUDL-HOFFMANN¹
Carsten B. SCHMIDT-WEBER²
Andrea CAVANI³
Johannes RING¹
Ruediger HEIN¹
Kilian EYERICH¹

¹ Department of Dermatology and Allergy,

² ZAUM, Center for Allergy and Environment,
Technische Universität und Helmholtz
Center Munich,
Biedersteiner Straße 29,
Munich, Germany

³ Laboratory of experimental immunology,
IDI-IRCCS,
Rome, Italy

^aBoth authors contributed equally to this work.

Differential *in situ* expression of IL-17 in skin diseases

Background: Interleukin (IL)-17 is a key molecule for epithelial immunity and inflammation. **Objectives:** To quantify IL-17 expression *in situ* in a large panel of cutaneous diseases. **Materials & Methods:** 289 samples of the 30 most common cutaneous infectious, autoimmune, inflammatory and tumor diseases were stained for IL-17 immunohistochemically. **Results:** IL-17 expression strongly varied between the diseases, but was conserved within each disease. The major cellular sources of IL-17 were T cells and granulocytes. Skin diseases caused by extracellular microbials were infiltrated by many IL-17+ cells, while intracellular infections were scarcely positive for IL-17. While autoimmune diseases were mostly accompanied by IL-17+ T cells, IL-17+ granulocytes were dominant in neutrophilic dermatoses. **Conclusion:** Cutaneous diseases show a characteristic pattern of IL-17+ cellular infiltrate. These patterns are relevant for the clinician, since therapeutic approaches targeting differentiation of Th17 cells as well as direct targeting of IL-17 are or will become available.

Key words: Interleukin (IL)-17, neutrophil granulocyte, Th17, T cell

Interleukin-17A/F belong to the class of “tissue-signaling cytokines” that are immune cell-derived cytokines with major impact on epithelial tissue [1]. Since its discovery in 1993 by Rouvier and colleagues [2], there is an enormous scientific interest in the source and functional impact of IL-17. Today, we know that IL-17A/F are produced mainly by Th17 cells, but also by other T helper cells such as IFN- γ producing Th1 or IL-4 producing Th2 cells as well as by innate immune cells like NK cells, follicular helper cells or neutrophil granulocytes [1, 3]. Concerning the function, IL-17 is a key cytokine for epithelial immunity [1, 4]. Loss of IL-17 results in selective chronic infections of the skin and mucosal membranes with fungi and/or bacteria [5]. An ineffective IL-17 signaling is also reported in atopic eczema due to counteracting Th2 cytokines [6]. In patients with co-existing psoriasis and atopic eczema, skin colonization with extracellular microbials is limited to the sites of eczema, where the Th2/IL-17 ratio is increased as compared to psoriasis [7]. Beyond innate immunity, IL-17 acts synergistically with IFN- γ to induce adhesion molecules such as ICAM-1 or MHC antigens on keratinocytes [8]. This results in an increased unspecific T cell mediated cytotoxicity that is a critical hallmark in many inflammatory skin diseases, but also in tumor homeostasis. However, in contrast to cellular sources and functional aspects of IL-17 *in vitro*, little is known about the *in situ* expression of IL-17 in cutaneous pathologies.

Materials and Methods

289 samples of the 30 most common inflammatory, infectious, auto-immune and tumor diseases in the skin were

stained for IL-17. Diagnoses were made in the routine histological department and sections were stained for IL-17 as published previously [8, 9]. Briefly, paraffin-embedded sections were incubated in a pH 6 epitope retrieval solution (Dako), and subsequently incubated with goat anti-human IL-17 (R&D systems), a biotinylated anti-goat secondary antibody (Vector), Streptavidin peroxidase, and the substrate 3-amino-9-ethyl-carbazole (Dako). Finally, slides were counterstained with hematoxylin. Infiltrating immune cells were counted manually in two visual fields for each sample in a blinded manner. Infiltrating cells were grouped morphologically into mononuclear and polymorphic nuclear cells, and the absolute and relative number of IL-17+ cells was determined.

Results

The relative and absolute number of IL-17+ cells was highly heterogeneous among different skin diseases, but a similar pattern was observed within each disease. Besides T cells, a second major population of IL-17+ cells displayed a polymorphic nucleus and consisted of both eosinophil and neutrophil granulocytes. Among infectious diseases, a few cells stained positive for IL-17 in viral diseases such as verruca vulgaris or condyloma acuminatum (*figure 1, table 1*). In contrast, bacterial and fungal infections such as abscesses and tinea, respectively, were highly positive for IL-17+ lymphocytes and granulocytes. Granulomatous and fibrotic autoimmune and infectious diseases such as acrodermatitis chronica atrophicans, morphea, lichen sclerosus et atrophicus, granuloma anulare and sarcoidosis were dominated by IL-17+ lymphocytes with few IL-17+ neutrophils. In contrast, in the bullous autoimmune diseases

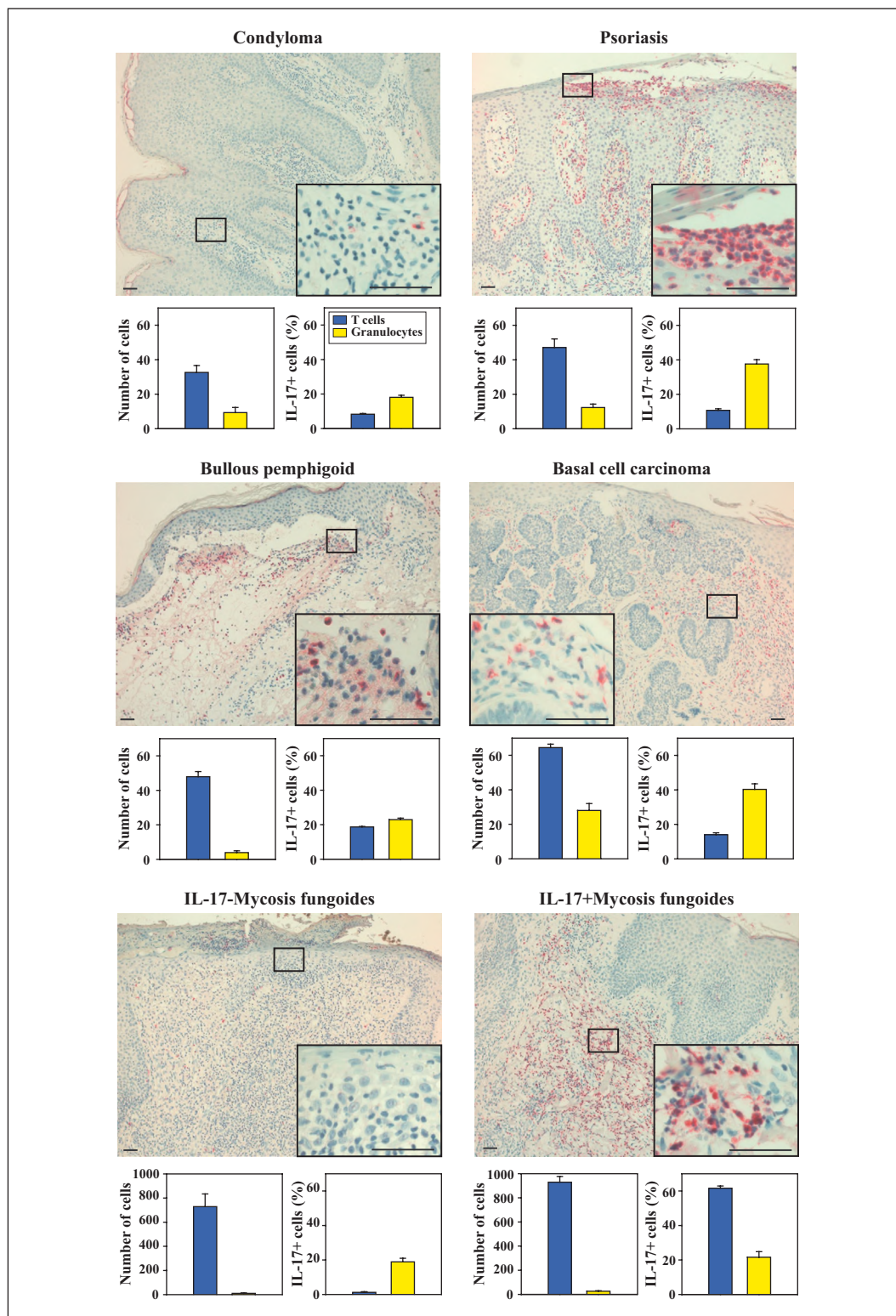


Figure 1. IL-17+ cells in skin diseases. Representative IL-17 immunohistochemical stainings of condyloma, psoriasis, basal cell carcinoma, bullous pemphigoid, and two cutaneous lymphomas (one derived from an IL-17-, the other from an IL-17+ clone). Bars indicate 20 μ m. The graphs below show the absolute number of lymphocytes (blue) and granulocytes (yellow) as well as the relative number of IL-17+ cells (right graphs) in all investigated samples of the corresponding disease (n = 6-10) \pm SEM.

Table 1. Absolut and relative number of IL-17+ cells in the 30 most common histologically defined cutaneous diseases (n=289).

Diagnosis	n	Total lymphocytes	IL-17+ lymphocytes	% IL-17+ lymphocytes	Total granulocytes	IL-17+ granulocytes	% IL-17+ granulocytes
Infectious diseases							
Acrodermatitis chronica atrophicans	8	28.5	4.2	14.7	1.2	0.1	5.3
Abscess	5	42.1	5.2	12.4	15.5	9.3	59.6
Condyloma acuminata	8	32.6	2.7	8.3	9.3	1.7	18.1
Verruca vulgaris	12	48.0	2.1	4.3	3.9	0.5	11.7
Tinea	6	42.2	5.4	12.8	8.6	5.6	65.0
Chronic inflammatory diseases							
Eczema	10	87.8	6.5	7.4	4.5	1.3	27.8
Lichen planus	11	88.6	3.4	4.1	10.5	1.2	11.3
Psoriasis	8	47.1	5.1	10.7	12.3	4.6	37.6
Neutrophilic dermatoses							
Drug exanthema	12	57.6	4.3	7.5	22.5	9.2	40.7
Vasculitis	14	33.2	2.6	7.7	17.8	10.9	60.9
Pyoderma gangraenosum	6	36.2	6.1	16.8	64.1	59.3	92.5
Sweet's syndrome	4	33.0	3.5	10.6	50.3	30.0	59.7
Granulomatous diseases							
Granuloma anulare	12	40.3	4.8	11.9	5.2	1.8	34.7
Rosacea	6	55.0	5.9	10.8	18.5	8.8	47.3
Sarcoidosis	7	43.4	4.1	9.5	2.1	0.2	10.0
Bullous autoimmune diseases							
Bullous pemphigoid	11	64.5	9.0	14.0	28.0	11.3	40.3
Pemphigus vulgaris	6	41.1	4.5	11.0	32.0	17.0	53.1
Collagenoses							
Morphea	10	40.5	6.2	15.2	1.4	0.1	3.7
Lichen sclerosus et atrophicus	6	23.9	2.9	12.1	1.7	0.6	35.3
Lupus erythematosus	9	103.8	7.9	7.6	7.4	2.3	30.8
Tumors							
Atypic fibroxanthoma	4	14.0	2.5	17.9	22.8	17.3	75.9
Actinic keratosis	6	34.3	2.6	7.7	13.5	1.6	12.0
Basal cell carcinoma, superficial	15	47.9	8.9	18.7	3.9	0.9	22.9
Basal cell carcinoma, sclerodermiform	12	44.0	7.8	17.7	6.5	1.6	25
Basal cell carcinoma, other	12	44.6	8.8	19.6	5.1	1.0	20.5
Dermatofibrosarcoma protuberans	9	37.2	5.4	14.6	2.8	0.2	8.0
Lentigo maligna	7	24.9	2.7	10.1	2.9	0.8	27.5
Malignant melanoma	11	26.3	3.1	12.0	3.9	1.4	36.0
Morbus Bowen	12	53.3	3.8	7.2	16.3	9.5	58.6
Spinocellular carcinoma	15	49.0	5.5	11.3	10.1	2.7	26.7
Mycosis fungoides	8	456.3	60.2	13.2	24.4	6.2	25.4
Lymphoma	7	729.0	8.6	1.2	10.2	1.9	18.9

pemphigus vulgaris and bullous pemphigoid, high numbers of IL-17+ granulocytes were detected. Inflammatory skin diseases showed a heterogeneous pattern: while IL-17+ cells were scarce in lichen planus, eczema was characterised by IL-17+ lymphocytes only and psoriasis by IL-17+ lymphocytes and granulocytes. Among tumors, basal cell carcinomas were infiltrated by a high number of IL-17+ lymphocytes, while fewer IL-17+ cells were detected in spinocellular carcinoma and melanoma. Cutaneous lymphomas were negative for IL-17 except for one sample caused by an IL-17+ T cell clone (*figure 1*). The highest percentage of IL-17+ cells was observed in neutrophil

dermatoses, such as cutaneous drug eruptions, Sweet's syndrome, leukocytoclastic vasculitis and pyoderma gangraenosum (*table 1*). In these cases, the source of IL-17 was predominantly granulocytes.

Discussion

In summary, the quantity of IL-17+ cells in cutaneous diseases is highly heterogeneous and disease-specific. These results are of clinical interest, since they give information

as to where biological agents interfering with IL-17 are promising (*table 1*). A good clinical outcome with anti-IL-12p40 antibodies (Ustekinumab, Briakinumab), that mostly target T cells, may be expected in diseases with a high number of IL-17+ lymphocytes, such as fibrotic and granulomatous diseases. Ustekinumab has also been reported to be efficient in two cases of pyoderma gangraenosum [10, 11]. However, the results reported here suggest that cutaneous diseases associated with many IL-17+ granulocytes could benefit even more from direct targeting of the IL-17 signaling with anti-IL-17 (AIN457, LY2439821).

Disclosure. *Financial support: K. Eyerich was supported by the Deutsche Forschungsgemeinschaft (DFG, EY97/2-1) and the Christine Kühne Center for Allergy Research and Education (CK-CARE). Conflict of interest: The authors declare no conflict of interest.*

References

1. Eyerich S, Eyerich K, Cavani A, *et al.* IL-17 and IL-22: siblings, not twins. *Trends Immunol* 2010; 31: 354-61.

2. Rouvier E, Luciani MF, Mattei MG, *et al.* CTLA-8, cloned from an activated T cell, bearing AU-rich messenger RNA instability sequences, and homologous to a herpesvirus saimiri gene. *J Immunol* 1993; 150: 5445-56.

3. Li L, Huang L, Vergis AL, *et al.* IL-17 produced by neutrophils regulates IFN-gamma-mediated neutrophil migration in mouse kidney ischemia-reperfusion injury. *J Clin Invest* 2009; 120: 331-42.

4. Korn T, Bettelli E, Oukka M, *et al.* IL-17 and Th17 Cells. *Annu Rev Immunol* 2009; 27: 485-517.

5. Eyerich K, Foerster S, Rombold S, *et al.* Patients with chronic mucocutaneous candidiasis exhibit reduced production of Th17-associated cytokines IL-17 and IL-22. *J Invest Dermatol* 2008; 128: 2640-5.

6. Eyerich K, Pennino D, Scarponi C *et al.* IL-17 in atopic eczema: linking allergen-specific adaptive and microbial-triggered innate immune response. *J Allergy Clin Immunol* 2009; 123: 59-66 e4.

7. Eyerich S, Onken AT, Weidinger S *et al.* Mutual antagonism of T cells causing psoriasis and atopic eczema. *N Engl J Med* 365; 231-8.

8. Pennino D, Eyerich K, Scarponi C, *et al.* IL-17 amplifies human contact hypersensitivity by licensing hapten nonspecific Th1 cells to kill autologous keratinocytes. *J Immunol* 2010; 184: 4880-8.

9. Eyerich S, Eyerich K, Pennino D, *et al.* Th22 cells represent a distinct human T cell subset involved in epidermal immunity and remodeling. *J Clin Invest* 2009; 119: 3573-85.

10. Guenova E, Teske A, Fehrenbacher B, *et al.* Interleukin 23 expression in pyoderma gangrenosum and targeted therapy with ustekinumab. *Arch Dermatol* 2011; 147: 1203-5.

11. Fahmy M, Ramamoorthy S, Hata T, *et al.* Ustekinumab for peristomal pyoderma gangrenosum. *Am J Gastroenterol* 2012; 107: 794-5.