

Effect of repeated laser microsurgical operations on laryngeal cancer prognosis

Alexander D. Karatzanis, Frank Waldfahrer, Georgios Psychogios, Joachim Hornung, Johannes Zenk, George A. Velegarakis, Heinrich Iro

Angaben zur Veröffentlichung / Publication details:

Karatzanis, Alexander D., Frank Waldfahrer, Georgios Psychogios, Joachim Hornung, Johannes Zenk, George A. Velegarakis, and Heinrich Iro. 2009. "Effect of repeated laser microsurgical operations on laryngeal cancer prognosis." *Head and Neck* 32 (7): 921-28. <https://doi.org/10.1002/hed.21272>.

Nutzungsbedingungen / Terms of use:

licgercopyright

Dieses Dokument wird unter folgenden Bedingungen zur Verfügung gestellt: / This document is made available under the following conditions:

Deutsches Urheberrecht

Weitere Informationen finden Sie unter: / For more information see:

<https://www.uni-augsburg.de/de/organisation/bibliothek/publizieren-zitieren-archivieren/publizieren/>



EFFECT OF REPEATED LASER MICROSURGICAL OPERATIONS ON LARYNGEAL CANCER PROGNOSIS

Alexander D. Karatzanis, MD, PhD,^{1,2} Frank Waldfaher, MD, PhD,¹ Georgios Psychogios, MD, PhD,¹ Joachim Hornung, MD, PhD,¹ Johannes Zenk, PhD,¹ George A. Velegrakis, PhD,² Heinrich Iro, PhD¹

¹Department of Otorhinolaryngology, Head and Neck Surgery, University of Erlangen - Nuremberg Medical School, Erlangen, Germany. E-mail: heinrich.iro@uk-erlangen.de

²Department of Otorhinolaryngology, Head and Neck Surgery, University of Crete Medical School, Heraklion, Crete, Greece

Abstract: *Background.* The aim of this study was to evaluate whether repeated sessions of transoral CO₂ laser microsurgery (TLM) aiming to achieve clear histologic margins carry a negative effect on the prognosis of laryngeal cancer.

Methods. This was a retrospective evaluation of 763 cases that underwent primary TLM treatment for laryngeal cancer. Cases were compared for overall survival and local control rates with respect to status of surgical margins and number of procedures necessary to achieve these margins.

Results. No significant differences were noted among cases with negative surgical margins regardless of the number of procedures necessary to achieve these margins. On the other hand, positive margins at the end of surgical treatment carried significant negative prognostic effect.

Conclusion. The prognostic effect of negative surgical margins in TLM for laryngeal cancer is significant regardless of the number of procedures required to obtain such margins. © 2009 Wiley Periodicals, Inc. *Head Neck* 32: 921–928, 2010

Keywords: laryngeal cancer; laser microsurgery; resection margins; revision surgery; prognosis

Multiple options are available for the treatment of laryngeal cancer today.^{1–4} Certain features, such as tumor exact location, the presence of cartilage invasion, and patient and physician choice influence the treatment decision.^{2,5} During recent years, a great focus toward improved functional outcome has been given by most physicians treating patients with laryngeal cancer.⁶ Consequently, a wide array of organ-preservation surgeries for laryngeal cancer exists today. New technology and instrumentation have opened the way for endoscopic minimally invasive strategies, whereas a renewed interest has also been witnessed regarding open preservation surgical techniques.⁶

Transoral CO₂ laser microsurgery (TLM) has evolved as an optimal therapy of early and moderately advanced laryngeal carcinomas.⁷ TLM represents a minimally invasive surgical approach which allows tumors to be removed with minimal sacrifice of healthy tissue and with retention of acceptable voice quality.⁸ Other advantages of TLM include low morbidity

and mortality, avoidance of tracheostomy, shorter periods of hospitalization, and low costs.^{9,10} In addition, TLM has repeatedly demonstrated cure rates for early laryngeal cancer comparable to those of open surgery or primary radiotherapy.^{10,11}

In every surgical procedure for the treatment of cancer, the significance of tumor-free surgical margins cannot be overemphasized.^{12,13} It has been widely accepted that complete excision of a tumor at the primary site is essential to ensure local control.^{14–16} Patients with positive resection margins have significantly higher rates of local recurrence and often exhibit decreased survival.^{12–16} Therefore, the aim of any tumor surgery with therapeutic intent should be histologically confirmed disease-free margins.¹² The application of TLM for the treatment of laryngeal cancer offers significant advantages with regard to margin control, as it allows for easy, repeated, and direct access to the tumor site.^{5,12,17,18} With the use of TLM, no need exists to re-raise the surgical flaps as the surgical wound always remains open.⁵ This technique is, therefore, ideal for additional sessions and re-resection whenever surgical margins are found postoperatively to be compromised. This study aimed to evaluate whether multiple sessions of TLM aiming to achieve clear histologic margins carry a negative effect on the prognosis of laryngeal cancer.

MATERIALS AND METHODS

A retrospective study was conducted at an academic tertiary referral center (Department of Otorhinolaryngology, Head and Neck Surgery, University of Erlangen – Nuremberg Medical School, Erlangen, Germany). Relevant approval from the institutional review board of the hospital was obtained. The files of all patients who underwent primary TLM treatment for laryngeal cancer between 1978 and 2003 were reviewed. Patients with insufficient data, systemic disease at the time of diagnosis, histology other than squamous cell carcinoma, and patients with second primary tumors at the time of diagnosis were excluded. Consequently, a total of 763 subjects formed the final cohort of this study.

Patients were divided into the following 3 groups: group 1 included cases in which negative histologic margins (R0) were obtained with

a single procedure, whereas group 2 included cases in which more than 1 operation had been necessary to achieve R0 status. Group 3 included subjects where negative histologic margins could not be achieved and, therefore, had positive margins at the end of surgical treatment (R+). Subjects in each group were further subdivided according to T and N classification of disease. Early local disease subgroups included T_{is}, T₁, and T₂ tumors, whereas advanced local disease subgroups included T₃ and T₄ tumors. The N classification subgroups were formed according to presence or not of regional metastases, (pN₊ and N₀/pN₀, respectively). Staging was conducted according to the 2002 American Joint Committee on Cancer (AJCC) and Union Internationale Contre le Cancer (UICC) classification.¹⁹ The terms T and N indicate primary tumor and lymph node classification, respectively.

All pathology reports were reviewed and surgical margins characterized by the presence of invasive carcinoma at the edge of resection on permanent section pathology defined as positive. Accordingly, surgical margins not characterized by the presence of invasive carcinoma at the end of resection were defined as negative. Groups were compared for overall survival rates and local disease control rates. Overall survival representing the total mortality rate of patients was calculated as the percentage of patients alive for more than 5 years divided by the total number of patients. Local disease control reflecting the analysis of tumor recurrence in the primary site was calculated from the date of surgery to the date of local recurrence diagnosis or date of last follow-up. Additional data that were collected and placed in the database included concurrent treatment of the neck and postoperative radiotherapy. Statistical analysis was performed using the Kaplan–Meier method with 95% intervals. The software SPSS Version 16 (SPSS, Chicago, IL) for Microsoft Windows was used for the analysis. A *p* value of less than .05 was considered significant.

RESULTS

Among the 763 patients that were finally included in the study, 715 were men (93.7%) and 48 were women (6.3%). The male-to-female ratio was approximately 15:1. Mean age in the whole study group was 62 years, ranging from

Table 1. Epidemiologic and disease specific characteristics of patients from all 3 groups.

	Group 1	Group 2	Group 3
No. of patients	580	133	50
Age, mean, y	62.1	59.7	66.2
Male (%)	542 (93.4%)	127 (95.5%)	46 (92%)
Early T classification (%)	513 (88.4%)	117 (88.0%)	29 (58%)
Advanced T classification (%)	67 (11.6%)	16 (12.1%)	21 (42%)
N ₀ classification (%)	502 (86.6%)	120 (90.2%)	33 (66%)
N ₊ classification (%)	78 (13.4%)	13 (9.8%)	17 (34%)

Note. Group 1: cases in which negative histological margins (R0) were obtained with a single procedure. Group 2: cases in which more than 1 operation had been necessary in order to achieve R0 status. Group 3: subjects with positive margins at the end of surgical treatment. Early T classification: T_{is}, T₁, and T₂ tumors. Advanced T classification: T₃ and T₄ tumors. N₀ classification: N₀ and/or pN₀ tumors. N₊ classification: N₁, N₂, and N₃ tumors.

15 to 91 years. Mean follow-up period was 88.6 months and ranged from 1 to 349.5 months. Group 1, where free margins had been achieved with a single operation, comprised of 580 patients (76%). Group 2, where more than 1 operation was necessary to achieve tumor-free margins, included 133 patients (17.4%). Two operations had been sufficient for the vast majority of subjects in this group (126 patients), whereas up to 4 sessions were necessary in 7 cases. Finally, group 3, which included patients with positive margins at the end of surgical treatment, contained 50 patients (6.6%). Epidemiologic and disease-specific characteristics of patients from all 3 groups are presented in Table 1. Detailed distribution of cases from each group according to local stage of disease and adjuvant treatment is presented in Table 2.

Survival rates and local control rates for each of the 3 groups are shown in Table 3. No significant differences were noted between groups 1 and 2 with regard to survival ($p = .434$) and local control ($p = .898$) rates. On the other hand, group 1 showed significantly better

survival and local control rates compared with group 3 ($p < .0001$). Group 2 also showed significantly better survival and local control rates compared with group 3 ($p < .0001$). Figure 1 shows Kaplan–Meier analysis of overall survival from all 3 groups.

Survival and local control rates among patients with early disease, according to T and N classification from each group, are presented in Table 4. Rates regarding overall survival ($p = .932$) and local control ($p = .668$) were again comparable between groups 1 and 2. Early T and/or N classification cases from group 1, on the other hand, showed significantly better survival ($p = .005$ and $p < .0001$, respectively) and local control ($p = .024$ and $p < .0001$, respectively) rates compared with group 3. Similarly, early T and/or N classification cases from group 2 had significantly superior survival ($p = .025$ and $p < .0001$, respectively) and local control ($p = .0075$ and $p < .0001$, respectively) rates compared with group 3 (Table 4). Kaplan–Meier analysis of overall survival and local control of patients with early T classification disease from each group is shown in Figure 2. Cases with locally and/or regionally advanced tumors were not compared separately as the number of patients was not sufficient in every group for statistical evaluation.

In total, 146 patients underwent neck dissection in our series. In 47 cases, dissection was

Table 2. Detailed distribution of cases from each group according to local stage of disease and adjuvant treatment.

	No. of cases (%)		
	Group 1	Group 2	Group 3
T classification			
T _{is}	19 (3.3)	4 (3.0)	0 (0)
1	277 (47.7)	69 (51.9)	13 (26.0)
2	217 (37.5)	44 (33.1)	16 (32.0)
3	23 (3.9)	7 (5.3)	11 (22.0)
4	44 (7.6)	9 (6.7)	10 (20.0)
Adjuvant treatment	92 (15.8)	14 (10.5)	30 (60.0)

Note. Group 1: cases in which negative histological margins (R0) were obtained with a single procedure. Group 2: cases in which more than 1 operation had been necessary in order to achieve R0 status. Group 3: subjects with positive margins at the end of surgical treatment. Adjuvant treatment: radiotherapy with or without chemotherapy.

Table 3. Overall survival and local disease control rates for each of the 3 groups separately.

	Group 1	Group 2	Group 3
5-year survival rates, %	71.3	74.2	40.2
Local control rates, %	66.0	69.6	40.4

Note. Group 1: cases in which negative histological margins (R0) were obtained with a single procedure. Group 2: cases in which more than 1 operation had been necessary in order to achieve R0 status. Group 3: subjects with positive margins at the end of surgical treatment.

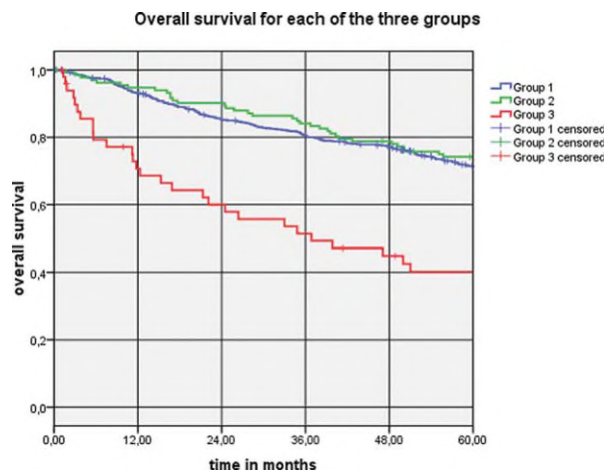


FIGURE 1. Kaplan–Meier analysis of overall survival for each of the 3 groups. Group 1: cases in which negative histologic margins (R0) were obtained with a single procedure. Group 2: cases in which more than 1 operation had been necessary to achieve R0 status. Group 3: subjects with positive margins at the end of surgical treatment. [Color figure can be viewed in the online issue, which is available at www.interscience.wiley.com.]

performed bilaterally. Almost half of group 3 cases underwent some form of neck dissection, whereas the rest of the procedures were almost evenly distributed among groups 1 and 2. Indications for neck dissection mainly included pre-surgical positive status of lymph nodes, advanced T classification, and anatomic location of the primary tumor other than the glottis. In cases of N₀ necks, a lateral selective neck dissection was performed, whereas cases with clinically positive lymph nodes underwent modified radical neck dissection. Postoperative radiotherapy, either alone or combined with chemotherapy, was performed in 136 patients. Thirty of these cases belonged to group 3, whereas the rest were almost evenly distributed among groups 1 and 2. Indications for radiotherapy generally included advanced local and/or regional disease, extracapsular tumor spread, and infiltration of lymph vessels or nerves on permanent histology. None of the early T classification cases from groups 1 or 2 received postoperative

radiotherapy. Group 3 patients were postoperatively managed by either radiotherapy, sometimes combined with chemotherapy, or close follow-up, leaving further treatment for later, if indicated. Survival and disease control rates of group 3 patients according to the type of postoperative management are shown in Table 5.

DISCUSSION

The histologically confirmed presence of tumor at the resection margin of a surgical specimen is described in the literature as a positive tumor margin.^{15,19} Nevertheless, the size of an oncologically safe resection margin is an issue under debate and seems to depend on the anatomic site.^{13,15} With regard to the head and neck region, oral cavity and pharyngeal tumors have shown an increased propensity for submucosal spread warranting perhaps a wide resection margin.^{13,20} On the other hand, wide surgical margins seem to be of minor importance in the larynx as these have not been associated with better local control rates.^{13,20} Moreover, wide margins could have a negative effect on functional outcome when organ preservation surgery is performed. Consequently, in this series, surgical margins have been considered as positive whenever invasive carcinoma was present at the border of resection on permanent histology sections.

It has been previously established that patients with head and neck cancer exhibiting positive resection margins have significantly higher rates of local recurrence and even show decreased survival.^{12,14,15} Postoperative treatment, including radiotherapy, is not able to even out the negative prognostic impact of compromised surgical margins.^{4,15,16} In a previous study, Jackel et al¹² have shown that the prognostic value of negative resection margins is not lost even when a second laser procedure is necessary to achieve such margins. In the same

Table 4. Overall survival and local disease control rates for cases with early disease from each of the 3 groups.

	Group 1		Group 2		Group 3	
	Early T classification	N ₀	Early T classification	N ₀	Early T classification	N ₀
5-year survival rates, %	75.4	75.0	72.3	75.6	49.7	38.3
Local control rates, %	70	69.6	69.7	70.5	49.7	38.3

Note. Group 1: cases in which negative histological margins (R0) were obtained with a single procedure. Group 2: cases in which more than 1 operation had been necessary in order to achieve R0 status. Group 3: subjects with positive margins at the end of surgical treatment. Early T classification: T_{1b}, T₁, and T₂ tumors. N₀ classification: N₀ and/or pN₀ tumors.

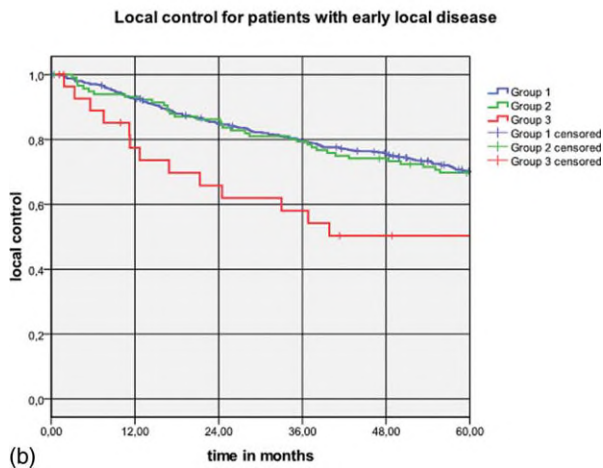
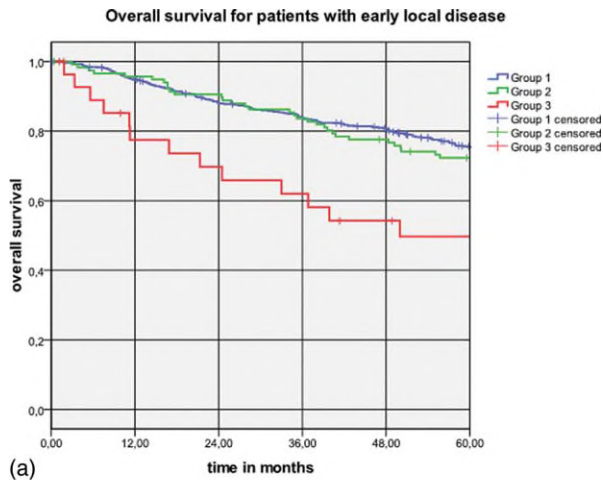


FIGURE 2. Kaplan–Meier analysis of (a) overall survival, and (b) local control, for patients with early local disease (T_{is} , T_1 , and T_2 classification tumors) from each of the 3 groups. Group 1: cases where negative histologic margins (R0) were obtained with a single procedure. Group 2: cases where more than 1 operation had been necessary to achieve R0 status. Group 3: subjects with positive margins at the end of surgical treatment. [Color figure can be viewed in the online issue, which is available at www.interscience.wiley.com.]

study, patients in whom re-resection margins were positive for tumor showed increased risk of locoregional failure. Nevertheless, a diverse

group of patients with carcinomas of the whole upper aerodigestive tract were presented in that study. Knowledge regarding the prognostic effects of positive surgical margins specifically for patients with laryngeal cancer remains limited.¹³ Moreover, the prognostic effect of multiple laser microsurgical operations specifically for laryngeal cancer has not been previously assessed.

In the present study, no statistically significant differences were noted with regard to survival and local control rates when comparing patients with negative resection margins after 1 (group 1) or multiple surgical procedures (group 2, Table 3). On the other hand, patients with negative histologic margins at the end of surgical treatment (groups 1 and 2), showed significantly better survival and local control rates compared with patients with positive resection margins (group 3, Table 3, Figure 1). It should be noted here that group 3 contained a significantly larger percentage of patients with advanced disease, as shown in Table 1. To even out this discrepancy, cases with early local (T_{is} , T_1 , T_2) and/or regional (N_0) disease from each group were separately evaluated (Table 4). These were selected because they represented the majority of cases in which TLM was applied, showing sufficient numbers for statistical evaluation in every group. Again, survival and local control rates were comparable between groups 1 and 2, and significantly better when comparing either 1 with group 3 (Table 4, Figure 2). Unfortunately, a stage-by-stage comparison among the 3 groups was not feasible in this study because the respective number of cases in each group were not always sufficient for statistical evaluation. The only exception was stage II where all groups contained a sufficient amount of cases. There, oncologic results still remained comparable between groups 1 and 2, and significantly better when comparing either 1 with group 3.

Table 5. Overall survival and local disease control rates of subjects with positive margins at the end of surgical treatment (group 3), according to type of postoperative management.

	Radiotherapy (+/- chemotherapy)			Follow-up		
	Early T classification	N_0	Total	Early T classification	N_0	Total
No. of patients	13	19	30	16	14	20
5-year survival, %	44.9	40.9	35.9	54.5	33.8	48.2
Local control, %	44.9	40.9	35.9	54.5	33.8	48.2

Note. Cases with early local and/or regional disease from this group are separately evaluated. Early T classification: T_{is} , T_1 , and T_2 tumors. N_0 classification: N_0 and/or pN_0 tumors.

It becomes clear that the prognostic effect of negative surgical margins is quite significant regardless of the number of procedures required to obtain such margins. Therefore, it should be highly recommended to admit patients for revision surgery whenever residual disease is found on the resection borders of permanent histology sections. The use of laser in these situations is ideal, as previously mentioned, because it offers easy and direct access to the tumor site within the larynx. Consequently, re-resection with the use of laser should be unproblematic.^{5,12} Moreover, in the majority of patients with positive surgical margins after 1 procedure, tumor-free margins should be feasible with subsequent procedures. In our series, of 183 patients with positive margins at the end of the first procedure, negative margins were finally obtained in 133 patients (72.6%). Two operations were usually sufficient in these cases, but up to 4 procedures had been rarely necessary. Jackel et al¹² presented cases in which a maximum of 2 procedures were performed and patients with residual disease after re-resection were admitted for adjuvant radiotherapy or follow-up. The authors suggested, however, that additional sessions for further excision should be undertaken whenever revision specimens are positive. This is especially true in cases in which no other treatment is planned.¹² Results in our series tend to agree with this suggestion, although the number of cases in which more than 2 procedures were performed is not sufficient to be statistically evaluated.

We have utilized a standard piecemeal technique for laser excision in our institution. This technique allows narrow margin control with maximum preservation of function. Frozen section control is necessary with this method as an indicator for further resection. Nevertheless, frozen sections do not always correlate with permanent pathology.²¹ In our practice, we typically perform frozen section histology at the end of the excision and if results are positive further resection is undertaken. The newly excised tissue is then sent for permanent pathology examination. Whenever the margins of these specimens contain residual disease, an additional operation is immediately planned. The low morbidity and mortality of TLM greatly facilitate this decision.⁵ It should be noted here that TLM may pose increased difficulties in order for pathologists to reliably assess the status of tumor resection margins.^{7,8,12} Reasons for

this discrepancy are related to the nature of the CO₂ laser itself and include tissue contraction and evaporation, heat artifacts, or even small size of samples.¹² Such difficulties often result in surgical margins falsely assessed as positive or undetermined on permanent histology.^{8,12} Therefore, a high rate of tumor-free specimens on laser revision surgery should be expected.¹²

In our series, negative margins were accomplished with a single operation in 580 (76%) of 763 cases. In 133 cases (17.4%), more than 1 session (2 sessions in the vast majority) were necessary to obtain free surgical margins. The total number of cases with negative margins attained at the end of surgical treatment was 713 (93.4%), suggesting that negative tumor margins represent a very realistic goal of laryngeal cancer treatment with the application of TLM. Finally, in 50 patients (6.6%), free margins were not achieved by surgical treatment. These patients either refused to undergo further surgery or were considered unsuited candidates due to other reasons, such as general health status.

Factors that could probably be linked to an increased incidence of positive surgical margins, including specific anatomic location or local extent of disease, were not further assessed in this study. Nevertheless, previous reports have shown that certain anatomic sites, such as the anterior commissure, might be correlated with difficulties in obtaining clear margins leading to increased recurrence rates. Interestingly, recurrence rates remain increased even in anterior commissure cases with negative surgical margins on permanent histology.^{10,22} A higher necessity for repeated operations in this group of patients has, therefore, been noted and even conduction of a routine second-look procedure has been proposed.¹⁰ The issue of tumor size seems to be even more complex. According to common sense, one would expect a higher incidence of positive surgical margins when managing locally extended carcinomas. Results from our series are in agreement with this assumption, as the proportion of advanced T classification tumors in group 3 was greater compared to groups 1 and 2. On the other hand, it has been previously suggested that even small tumors could be characterized by increased incidence of compromised margins.¹² This may be due to the fact that surgeons are particularly concerned with a highly satisfactory functional outcome

when operating on patients with early local disease. For this reason, they tend to sacrifice as little macroscopically healthy tissue as possible, especially when treating tumors confined in the glottic area. The fact that a subsequent re-operation, if dictated by permanent histology, will not carry a negative effect on local disease control and survival, as has been shown in this study, provides a positive argument for this approach.

Postoperative management of patients with positive surgical margins is a controversial issue.^{12,13} Radiation therapy is a well established mode of treatment for laryngeal cancer.^{5,23} It has been therefore suggested that whenever surgical margins are compromised, postoperative radiotherapy may protect patients from local and/or regional recurrences.¹² On the other hand, it has also been suggested that close follow-up might represent the best treatment option for these cases because radiation therapy has been known to compromise functional recovery and also prevent early detection of recurrences.¹³ In our series, subjects with positive margins at the end of surgical treatment (group 3), were either treated by postoperative radiotherapy, sometimes combined with chemotherapy, or received no adjuvant treatment and were placed on close follow-up, leaving further treatment for later if necessary. The decision on the type of management was based on various factors including patient choice, reliability for close clinical surveillance, general health status, and effect of adjuvant treatment on functional outcome. No significant differences were noted between the 2 subgroups with regard to survival and local disease control rates. Results remained comparable even when cases with early disease from group 3 were separately evaluated (Table 5). These results suggest that close follow-up and treatment of patients later, if necessary, is the most valid option for cases with positive surgical margins if additional surgery cannot be undertaken.

In conclusion, the prognostic effect of negative surgical margins in TLM is quite significant regardless of the number of procedures required to obtain such margins. It is, therefore, highly recommended to admit patients for revision laser surgery whenever residual disease is found on the resection borders of permanent histology sections. If additional surgery cannot be undertaken, close follow-up, rather than radio-

therapy, seems to be the most valid management option.

REFERENCES

1. Chu EA, Kim YJ. Laryngeal cancer: diagnosis and pre-operative work-up. *Otolaryngol Clin North Am* 2008;41:673–695.
2. Davis GE, Schwartz SR, Veenstra DL, Yueh B. Cost comparison of surgery vs organ preservation for laryngeal cancer. *Arch Otolaryngol Head Neck Surg* 2005;131:21–26.
3. Starmer HM, Tippet DC, Webster KT. Effects of laryngeal cancer on voice and swallowing. *Otolaryngol Clin North Am* 2008;41:793–818.
4. Sessions DG, Lenox J, Spector GJ. Supraglottic laryngeal cancer: analysis of treatment results. *Laryngoscope* 2005;115:1402–1410.
5. Agrawal N, Ha PK. Management of early-stage laryngeal cancer. *Otolaryngol Clin North Am* 2008;41:757–769.
6. Tufano RP, Stafford EM. Organ preservation surgery for laryngeal cancer. *Otolaryngol Clin North Am* 2008;41:741–755.
7. Steiner W, Ambrosch P. Endoscopic microsurgical laser treatment of malignant diseases of the upper aerodigestive tract. In: Steiner W, Ambrosch P, eds. *Endoscopic laser surgery of the upper aerodigestive tract*. Stuttgart, Germany: Georg Thieme Verlag; 2000. pp 33–115.
8. Sigston E, de Mones E, Babin E, et al. Early-stage glottic cancer: oncological results and margins in laser cordectomy. *Arch Otolaryngol Head Neck Surg* 2006;132:147–152.
9. Grant DG, Salassa JR, Hinni ML, Pearson BW, Hayden RE, Perry WC. Transoral laser microsurgery for recurrent laryngeal and pharyngeal cancer. *Otolaryngol Head Neck Surg* 2008;138:606–613.
10. Roh JL, Kim DH, Park CI. The utility of second-look operation after laser microresection of glottic carcinoma involving the anterior commissure. *Laryngoscope* 2008;118:1400–1404.
11. Ambrosch P. The role of laser microsurgery in the treatment of laryngeal cancer. *Curr Opin Otolaryngol Head Neck Surg* 2007;15:82–88.
12. Jäckel M, Ambrosch P, Martin A, Steiner W. Impact for re-resection for inadequate margins on the prognosis of upper aerodigestive tract cancer treated by laser microsurgery. *Laryngoscope* 2007;117:350–356.
13. Gallo A, Manciooco V, Tropiano ML, et al. Prognostic value of resection margins in supracricoid laryngectomy. *Laryngoscope* 2004;114:616–621.
14. Batsakis JG. Surgical margins in squamous cell carcinomas. *Ann Otol Rhinol Laryngol* 1988;97(2 Pt 1):213–214.
15. Iro H, Waldfahrer F, Altendorf-Hofmann A, Weidenbecher M, Sauer R, Steiner W. Transoral laser surgery of supraglottic cancer: follow-up of 141 patients. *Arch Otolaryngol Head Neck Surg* 1998;124:1245–1250.
16. Pfreundner L, Willner J, Marx A, Hoppe F, Beckmann G, Flentje M. The influence of the radicality of resection and dose of postoperative radiation therapy on local control and survival in carcinomas of the upper aerodigestive tract. *Int J Radiat Oncol Biol Phys* 2000;47:1287–1297.

17. Grant DG, Salassa JR, Hinni ML, Pearson BW, Hayden RE, Perry WC. Transoral laser microsurgery for untreated glottic carcinoma. *Otolaryngol Head Neck Surg* 2007;137:482–486.
18. Ansarin M, Planicka M, Rotundo S, et al. Endoscopic carbon dioxide laser surgery for glottic cancer recurrence after radiotherapy: oncological results. *Arch Otolaryngol Head Neck Surg* 2007;133:1193–1197.
19. American Joint Committee on Cancer (AJCC). *Manual for staging of cancer*, 6th ed. New York, NY: Springer-Verlag; 2002. pp 47–57.
20. Yilmaz T, Turan E, Gürsel B, Onerci M, Kaya S. Positive surgical margins in cancer of the larynx. *Eur Arch Otolaryngol* 2001;258:188–191.
21. Crespo AN, Chone CT, Gripp FM, Spina AL, Altemani A. Role of margin status in recurrence after CO2 laser endoscopic resection of early glottic cancer. *Acta Otolaryngol* 2006;126:306–310.
22. Chone CT, Yonehara E, Martins JEF, Altemani A, Crespo AN. Importance of anterior commissure in recurrence of early glottic cancer after laser endoscopic resection. *Arch Otolaryngol Head Neck Surg* 2007;133:882–887.
23. Spector GJ, Sessions DG, Lenox J, Newland D, Simpson J, Haughey BH. Management of stage IV glottic carcinoma: therapeutic outcomes. *Laryngoscope* 2004;114:1438–1446.