



A novel technique to quantify aortic valve annulus deformation: A pilot study

Theresa Holst MD^{1,2}  | Johannes Petersen MD¹  | Gerhard Adam MD³ |
Hermann Reichenspurner MD, PhD¹ | Evaldas Girdauskas MD, PhD^{1,2} |
Enver Tahir MD³

¹Department of Cardiovascular Surgery, University Heart and Vascular Center UKE Hamburg, Hamburg, Germany

²Department of Cardiothoracic Surgery, Augsburg University Hospital, Augsburg, Germany

³Department of Diagnostic and Interventional Radiology and Nuclear Medicine, University Hospital Hamburg Eppendorf, Hamburg, Germany

Correspondence

Theresa Holst and Prof. Dr. Evaldas Girdauskas, Department of Cardiothoracic Surgery, Augsburg University Hospital, Stenglinstraße 2, 86156 Augsburg, Germany. Email: evaldas.girdauskas@uk-augsburg.de and theresa.holst@uk-augsburg.de

Abstract

Objectives: We evaluated the potential of cardiac magnetic resonance (CMR)-derived strain to assess aortic valve (AV) annulus deformation during the cardiac cycle in regurgitant and well-functioning AVs.

Methods: Four patients with severe aortic regurgitation and seven healthy controls underwent CMR. Assessment of longitudinal strain was performed by hypothesizing the AV annulus would be the left ventricle in long-axis orientation. Longitudinal strain of the segments belonging to the muscular and fibrous AV annulus was weighted and averaged to obtain regional values (RLS).

Results: Comparison of RLS between regurgitant and well-functioning AVs showed a considerably different deformation of the muscular AV annulus (i.e., median RLS: 4.18 % [patients] vs. -10.41 % [controls], $p = .024$). The fibrous AV annulus demonstrated comparable deformational changes in both groups.

Conclusion: CMR-derived strain allows for quantification of AV annulus deformation during the cardiac cycle and shows an altered RLS in the muscular AV annulus in patients with severe aortic regurgitation.

KEYWORDS

aortic regurgitation, aortic valve repair, cardiac magnetic resonance imaging, feature-tracking strain analysis

1 | INTRODUCTION

In the absence of associated aortopathy, aortic regurgitation (AR) in tricuspid aortic valves (AV) is mostly caused by cusp prolapse,¹ particularly of the right coronary cusp.² However, it still remains unclear what factors contribute to this isolated cusp prolapse which occurs more frequently compared to the other two AV cusps.¹

Our previous computed tomography (CT)-based analyses revealed a marked diastolic annulus deformation in well-functioning tricuspid AVs which was significantly deteriorated in AR patients.³ Furthermore, we found a significant difference in the relation of muscular to fibrous AV annulus components between well-functioning and regurgitant AVs.⁴ Based thereon, we hypothesized that reduced diastolic AV annulus deformation is potentially induced

Evaldas Girdauskas and Enver Tahir contributed equally to this study.

This is an open access article under the terms of the Creative Commons Attribution-NonCommercial-NoDerivs License, which permits use and distribution in any medium, provided the original work is properly cited, the use is non-commercial and no modifications or adaptations are made.

© 2022 The Authors. *Journal of Cardiac Surgery* published by Wiley Periodicals LLC.

by dysfunction of the muscular component of AV annulus (i.e., region of the right-coronary sinus and left-right commissural area up to the left fibrous trigone),⁴ which leads to continuously increased diastolic stress on the right coronary cusp. This increased diastolic stress on the right coronary cusp may promote cusp degeneration and result in cusp prolapse and severe eccentric AR, consequently. However, the quantification of movement of the muscular component of AV annulus is not possible on regular CT-based analysis.

Cardiac magnetic resonance (CMR) strain analysis measures the extent of myocardial deformation during the cardiac cycle and has been previously implemented to facilitate early detection and quantification of myocardial dysfunction in AR patients.⁵ However, no study has yet evaluated the potential of CMR-derived strain to quantify AV annulus motion.

Our pilot study aims to examine the feasibility of using feature-tracking CMR strain analysis to assess AV annulus motion during the cardiac cycle and to quantify the movement of the muscular part of AV annulus in regurgitant AVs.

2 | MATERIALS AND METHODS

This study was approved by the ethics committee of the General Medical Council for Hamburg, Germany. Written informed consent was obtained from all subjects. Four patients with severe isolated AR scheduled for elective AV repair underwent preoperative CMR. Additionally, seven healthy controls with well-functioning AVs were recruited (eligibility criteria: no CMR contraindications, no cardiovascular/systemic disease as well as no cardioactive/vasoactive medication) and underwent CMR using the same protocol.

CMR was performed on a 3.0 T scanner (Ingenia, Philips Medical Systems). A coronal ECG-gated balanced turbo field echo (BTFE) sequence of the thorax was used to depict the aortic root. The CMR protocol included a cine short-axis stack and long-axis 2-, 3- and 4-chamber views using a standard steady-state free-precession (SSFP) sequence. AV annulus plane (Figure 1A) was acquired using the coronal aortic root on the BTFE sequence and the CMR 3-chamber view with 30 phases per RR interval. Anatomic landmarks (Figure 1B) were determined by additional exploration of more proximal and more distal planes.

Global (GLS) and segmental peak annular longitudinal strain were quantified using a commercial feature-tracking software (Segment, Version 2.1.R.6108, Medviso) as previously described.⁶ As this software has been developed for atrial and ventricular strain analysis, AV annulus plane images (Figure 1A) were treated as if depicting the left ventricle in long-axis view at inferoseptal/anterolateral plane according to the cardiac segmentation model (Figure 1B).⁷ Longitudinal strain (i.e., the longitudinal left ventricular deformation from base to apex) now represented the circumferential deformation of the AV annulus along its perimeter. For quantification of strain, end-diastolic "endo- and epicardial" borders (i.e., the inner and outer borders of the

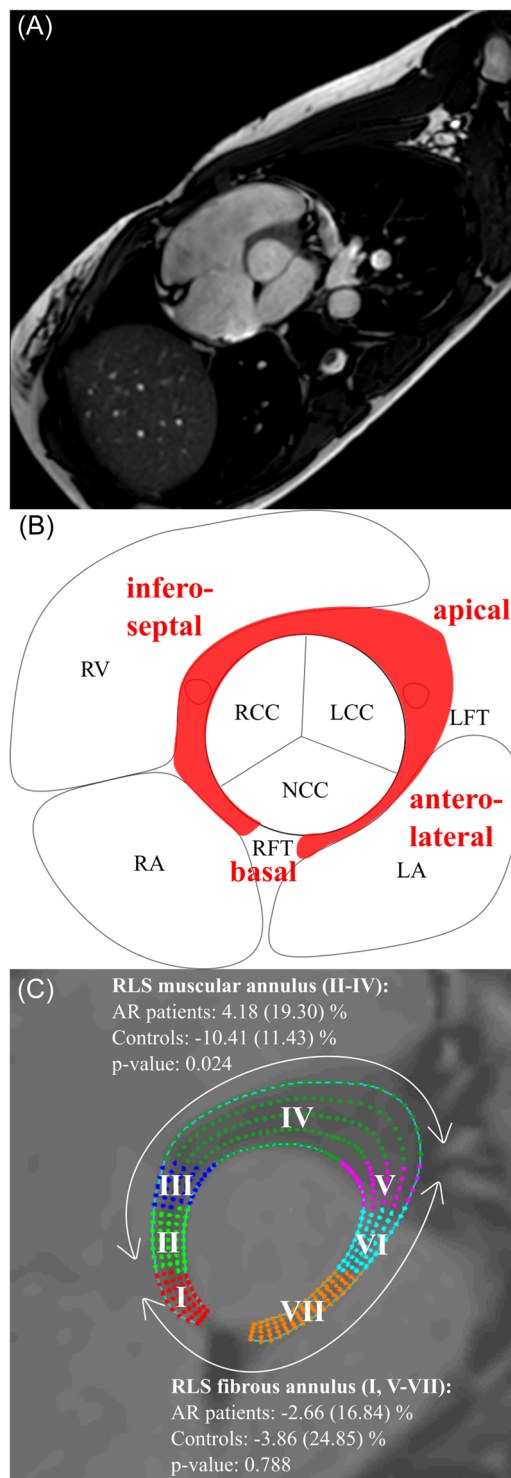


FIGURE 1 CMR aortic valve annulus plane (A) with schematic, annotated overlay of left ventricle (B). Preliminary results showing differences in regional longitudinal strain of the muscular aortic valve annulus in patients with aortic regurgitation ($n = 4$) versus controls ($n = 7$) (C). LA, left atrium; LCC, left-coronary cusp; LFT, left fibrous trigone; NCC, non-coronary cusp; RA, right atrium; RCC, right-coronary cusp; RFT, right fibrous trigone; RV, right ventricle

U-shaped structure in Figure 1C) were manually contoured and automatically propagated throughout the cardiac cycle.⁸ Segmentation was also performed automatically. Segmental longitudinal strain values of the segments belonging to the muscular (i.e., segments II–IV, Figure 1C) and fibrous (i.e., segments I, V–VII, Figure 1C) components of AV annulus were then manually weighted according to the number of strain points in each segment and averaged to obtain two regional values (RLS). Global, regional, and segmental longitudinal strain values are presented as median (IQR) throughout the article. A comparison of AR patients versus controls was made using the Mann–Whitney *U* Test (SPSS Statistics, IBM Corp.).

3 | RESULTS

Our preliminary results are summarized in Table 1 and Figure 1C. Systolic tissue shortening is expressed by negative and tissue lengthening by positive strain values.

On the segmental level, differences in median peak longitudinal strain were mainly pronounced in segment IV (i.e., “apical” segment, Figure 1C) (0.20 % in AR patients vs. –13.12 % in healthy controls, $p = .073$) and segment II (i.e., “mid inferoseptal” segment, Figure 1C) (17.94 % in AR patients vs. –10.86 % in healthy controls, $p = .042$) which both belong to the muscular component of AV annulus. In line with this, we also found a marked difference between both groups in the overall regional longitudinal strain (RLS) of the muscular part of AV annulus (i.e., segments II–IV combined) (median RLS: 4.18 % in patients with severe AR vs. –10.41 % in well-functioning AVs, $p = .024$). While the healthy controls showed a marked systolic shortening in this region of AV annulus (i.e., negative RLS value), AR patients rather displayed systolic lengthening as indicated by a positive RLS value. However, there was no significant difference between both groups in median RLS of the fibrous component of AV

annulus (–2.66 % in AR patients vs. –3.86 % in healthy controls, $p = .788$) implying similar deformation of this region of AV annulus during the cardiac cycle in AR patients and controls. There was also no significant difference in median global longitudinal strain (GLS) between both groups (1.69 % in patients with severe AR vs. –7.48 % in well-functioning AVs, $p = .230$).

4 | DISCUSSION

Preliminary results of this pilot study support our hypothesis that deformation of the muscular portion of AV annulus is different during the cardiac cycle in severely regurgitant versus well-functioning aortic valves. The fibrous component apparently undergoes similar deformational changes during the cardiac cycle in both groups.

These findings are in line with our previous clinical observation that the muscular part of the AV annulus is severely dilated in patients presenting with severe AR and prolapse of the right coronary cusp. In such patients, we routinely find a marked bulging of muscular AV annulus towards the right ventricular outflow tract during surgery, which is associated with a significant restriction of the prolapsing right-coronary cusp. This typical finding in AR patients brought us to the idea that the primary mechanism of aortic regurgitation is dysfunction of the muscular AV annulus in such patients, which leads to increased stress on the right coronary cusp and finally promotes the subsequent prolapsing. Deformational abnormalities of AV annulus in AR patients were already demonstrated by our previous CT-based analyses.^{3,4} However, more detailed tracking of AV annulus movement abnormalities in the muscular versus fibrous component was not possible on CT. Therefore, we aimed to explore the value of feature-tracking CMR strain analysis to address our clinical question.

Median peak longitudinal strain		AR patients (n = 4)	Controls (n = 7)	p value
GLS		1.69 (16.49)	–7.48 (18.54)	.230
RLS	II–IV: Muscular annulus	4.18 (19.30)	–10.41 (11.43)	.024
	I, V–VII: Fibrous annulus	–2.66 (16.84)	–3.86 (24.85)	.788
Segmental LS	I (“Basal inferoseptal”)	0.19 (56.55)	14.98 (28.22)	.648
	II (“Mid inferoseptal”)	17.94 (42.56)	–10.86 (35.09)	.042
	III (“Apical inferior/septal”)	–10.36 (41.47)	–15.84 (9.07)	.527
	IV (“Apical”)	0.20 (16.56)	–13.12 (12.09)	.073
	V (“Apical anterior/lateral”)	–1.95 (23.22)	18.71 (74.64)	.109
	VI (“Mid anterolateral”)	7.20 (47.91)	–12.19 (32.16)	.230
	VII (“Basal anterolateral”)	–6.65 (12.14)	–7.77 (23.66)	.788

TABLE 1 Global, regional, and segmental longitudinal strain values of AR patients versus controls

Note: Continuous variables are presented as median (IQR).

Abbreviations: AR, aortic regurgitation; GLS, global longitudinal strain; LS, longitudinal strain; RLS, regional longitudinal strain.

The scientific value of these findings, however, remains uncertain primarily due to our very restricted sample size. Furthermore, additional analyses using other CMR techniques (e.g., three-dimensional acquisition with a valve-/annulus-tracking approach or assessment of wall shear stress) are required to assess the impact of the through-plane motion of the aortic annulus on our findings and to further clarify whether the observed motion abnormalities of the muscular annulus are in fact associated with increased diastolic stress on the right coronary cusp leading to its prolapse and finally an eccentric AR. Hence, these preliminary findings should be further confirmed in larger systematic studies incorporating larger sample sizes and additional CMR measurements.

Moreover, the evaluation of AV annulus deformation by CMR-derived strain is currently still quite arbitrary, and dedicated software for this purpose is not yet available. Nevertheless, as demonstrated by our preliminary results, CMR-derived strain assessment certainly has the potential to gain deeper insight into AV function and might be the background for improving surgical valve repair techniques. Therefore, this pilot study should be considered the first step in the development of a dedicated software solution.

5 | CONCLUSION

In conclusion, our report describes the first application of feature-tracking CMR-derived strain to quantify AV annulus deformation during the cardiac cycle, leaving room for subsequent more in-depth analyses and underlining the need for the development of a dedicated software solution.

AUTHOR CONTRIBUTIONS

Theresa Holst: Data collection, data analysis/interpretation, and drafting article. Johannes Petersen: data collection, critical revision of the article, approval of article. Gerhard Adam: funding, critical revision of article, approval of article. Hermann Reichenspurner: funding, critical revision of article, approval of article. Evaldas Girdauskas: concept/design, data analysis/interpretation, critical revision of article, approval of article. Enver Tahir: concept/design, data analysis/interpretation, critical revision of article, approval of article.

ACKNOWLEDGMENT

No funding was received for this manuscript. Open Access funding enabled and organized by Projekt DEAL.

CONFLICT OF INTEREST

The authors declare no conflict of interest.

ETHICS STATEMENT

Institutional Review Board approval was obtained. Written informed consent was obtained from all subjects.

ORCID

Theresa Holst  <http://orcid.org/0000-0002-8057-9555>

Johannes Petersen  <http://orcid.org/0000-0002-3415-3385>

REFERENCES

1. Yang L-T, Michelena HI, Maleszewski JJ, Schaff HV, Pellikka PA. Contemporary etiologies, mechanisms, and surgical approaches in pure native aortic regurgitation. *Mayo Clin Proc.* 2019;94(7):1158-1170.
2. Boodhwani M, de Kerchove L, Watremez C, et al. Assessment and repair of aortic valve cusp prolapse: implications for valve-sparing procedures. *J Thorac Cardiovasc Surg.* 2011;141(4):917-925.
3. Petersen J, Voigtländer L, Schofer N, et al. Geometric changes in the aortic valve annulus during the cardiac cycle: impact on aortic valve repair. *Eur J Cardiothorac Surg.* 2018;54(3):441-445.
4. Neumann N, Petersen J, Sinning C, et al. Focus on the annuloplasty in aortic valve repair: implications from a quantitative multislice computed tomography analysis. *Quant Imaging Med Surg.* 2020;10(4):853-861.
5. Bax JJ, Delgado V. Advanced imaging in valvular heart disease. *Nat Rev Cardiol.* 2017;14(4):209-223.
6. Tahir E, Starekova J, Muellerleile K, et al. Impact of myocardial fibrosis on left ventricular function evaluated by Feature-Tracking myocardial strain cardiac magnetic resonance in competitive Male triathletes with normal ejection fraction. *Circ J.* 2019;83(7):1553-1562.
7. Cerqueira MD, Weissman NJ, Dilsizian V, et al. Standardized myocardial segmentation and nomenclature for tomographic imaging of the heart. A statement for healthcare professionals from the cardiac imaging committee of the council on clinical cardiology of the American Heart Association. *Circulation.* 2002;105(4):539-542.
8. Morais P, Marchi A, Bogaert JA, et al. Cardiovascular magnetic resonance myocardial feature tracking using a non-rigid, elastic image registration algorithm: assessment of variability in a real-life clinical setting. *J Cardiovasc Magn Reson.* 2017;19(1):24.

How to cite this article: Holst T, Petersen J, Adam G, Reichenspurner H, Girdauskas E, Tahir E. A novel technique to quantify aortic valve annulus deformation: a pilot study. *J Card Surg.* 2022;37:2734-2737. doi:10.1111/jocs.16683