

Incidence of anatomical variations according to the International Frontal Sinus Anatomy Classification (IFAC) and their coincidence with radiological signs of opacification

Fabian Sommer¹  · Thomas Karl Hoffmann¹ · Lena Harter¹ · Johannes Döscher¹ · Sebastian Kleiner² · Jörg Lindemann¹ · Andreas Leunig³

Abstract

Background The endonasal access to the frontal recess and sinus may be complicated by a variety of anatomical variations. Previous classifications of these variants were characterized by proper names or position information without anatomical reference. The IFAC is intended to simplify the classification of anatomical variations of the frontoethmoidal complex. The aim of this study was to analyse a representative number of sinus CT scans to assess the incidence of anatomical variations according to the IFAC and to compare the results with previous classifications. In addition, the coincidence of complex anatomical variations and radiological signs of opacification was investigated.

Methodology/principal Two hundred and forty-nine sinus CT scans were analysed in multiplanar reconstructions. Exclusion criteria were previous operations on the paranasal sinuses, malignant diseases, and an insufficient image quality. All anatomical variants were analysed according to the IFAC criteria. In addition, the coincidence of radiological signs of opacification and the presence of anatomical variations of the frontal recess and sinus were investigated.

Results The analysis revealed Agger nasi cells in 95% of the CT scans. Supra agger cells (SACs) were detected in 49% and Supra agger frontal cells (SAFCs) in 25% of the data sets. Suprabulla cells (SBCs) were detected in 89% and Supra bulla frontal cells (SBFCs) in 27% of the scans. Supraorbital ethmoid cells (SECs) were detectable in 9% and interfrontal septal cells in 28% of the scans. Despite a partially strong narrowing of the frontal recess, no increased occurrence of radiological signs of opacification could be detected ($p > 0.05$).

Conclusions Anatomical variations in the frontoethmoidal area are very common. According to the IFAC criteria, in 43% of the patients, cells could be detected with pneumatization to or into the frontal sinus. The IFAC is structured more clearly compared to previous classifications due to the anatomical aspect. It represents the most consistent classification regarding surgical planning. Further studies will demonstrate the scientific and clinical value of this classification.

✉ Fabian Sommer
fabian.sommer@uniklinik-ulm.de

¹ Department of Otorhinolaryngology, Head and Neck Surgery, University Hospital Ulm, Frauensteige 12, 89075 Ulm, Germany

² Department of Nuclear Medicine, University Hospital Rechts Der Isar, Munich, Ismaninger Straße 22, 81675 Munich, Germany

³ Rhinology Center, ENT-Clinic Bogenhausen, Dr. Gaertner GmbH, Munich, Germany

Introduction

The frontoethmoidal region is characterized by complex and narrow anatomic conditions with numerous anatomical variants. Multiple variations of ethmoidal cells can affect the drainage pathway and narrow the frontal recess [1, 2].

Surgery of the frontal recess and sinus is always a challenge. A common cause for revision surgery is the incomplete removal of cells in this area. Frequently, this results in a blockage of the drainage pathway with persistent inflammation and clinical symptoms [3]. In addition, there are important anatomical structures close to the sinuses, such

as the orbit, olfactory region, and cranium, which are in danger of being injured during surgical procedures. A precise and detailed knowledge of the anatomy is essential for any surgical procedure.

Numerous classifications for these anatomical variations have been described [1, 4–8]. Frequent use has been made of the classification by Bent and Kuhn [3, 6] in recent years. Here, the different frontoethmoidal cells are divided into four types. In addition, this classification includes agger nasi cells, cells of the interfrontal septum, the frontal bulla cell, suprabullar cells, and supraorbital ethmoidal cells [6].

Within the different classification, however, inconsistent nomenclatures and partially overlapping definitions prevail. To unify and clarify the multitude of proper names and the partly complicated classification, in 2016, the International Frontal Sinus Anatomy Classification (IFAC) [1] was published. The aim of the IFAC is a comprehensible and simple naming of the different anatomical variants based on topographical guiding structures replacing proper names.

The aim of this study was to determine the incidence of anatomical variants of the frontoethmoid complex using CT data sets according to the International Frontal Sinus Anatomy Classification (IFAC) which was published in 2016 [1]. In addition, the coincidence of radiologic signs of opacification and anatomical variations was determined. CT data sets of the paranasal sinuses of a defined period were analysed retrospectively. In addition, the presence of other anatomical variants, e.g., pneumatization of the crista galli, level differences of the olfactory fossa, variations and pneumatization of the uncinate process, and hypoplasia or aplasia of the frontal sinus were recorded. The paranasal sinuses, especially the frontal sinus, were also examined for mucosal pathology and to determine if certain anatomical variants of the frontoethmoid complex are associated with radiographic opacification of the frontal recess and sinus.

Materials and methods

Included were CT data sets from patients who were referred to our hospital with chronic sinusitic complaints such as recurrent rhinorrhea, sensation of pressure and/or headache, and nasal breathing disorder. All patients were referred to hospital by otolaryngologists and general practitioners. A total of 249 patient CT scans of the years 2015 and 2016 were analysed in the study. All scans of the paranasal sinuses were performed due to sinusitic complaints. Data from a longer period of time were deliberately evaluated to average seasonal fluctuations in the incidence of inflammatory sinus disease and the associated opacification in the CT scans over the selected period of time. Exclusion criteria were poor image quality, artefacts that preclude accurate evaluation, and previous sinus surgery. All CT scans were performed

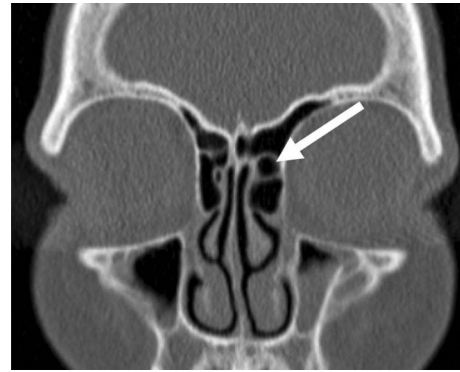


Fig. 1 Supra agger cell on the left side (coronal view)

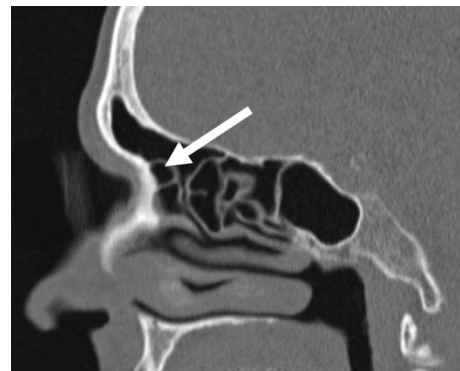

Fig. 2 Supra agger cell (sagittal view)

by a Brilliance 16 CT scanner (Phillips). The layer thickness of the primarily generated axial layers was 0.5 mm. Reconstructed coronary and sagittal images with layer thicknesses of 1 mm were obtained from the axial layers. The scans were performed in a low-dose protocol (120 kV, 15 mAs).

CT data sets were evaluated using the IMPAX EE R20 software (IMPAX EE R20 XVI SU3 v20170105_1424, Agfa HealthCare N.V., Mortsel, Belgium).

Anterior frontoethmoidal cells

Anterior frontoethmoid cells shift the drainage path of the frontal sinus medially, posterior or posteromedial. They include agger nasi cells (ANC), supra agger cells (SAC), and supra agger frontal cells (SAFC) [1] (Figs. 1, 2, 3).

Posterior frontoethmoidal cells

Posterior cells shift the frontal sinus drainage pathway towards anterior, and include supra bulla cell (SBC), the supra bulla frontal cell (SBFC), and the supraorbital ethmoid cell (SOEC) [1] (Figs. 4, 5, 6, 7, 8).

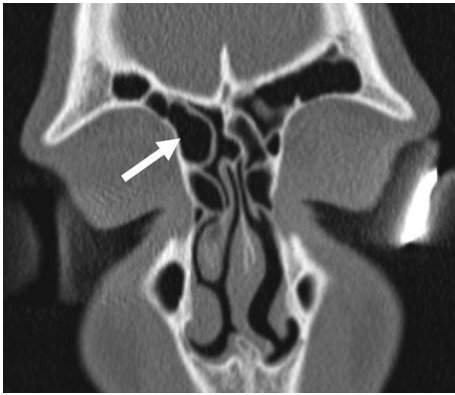


Fig. 3 Supra agger frontal cell (coronal view)

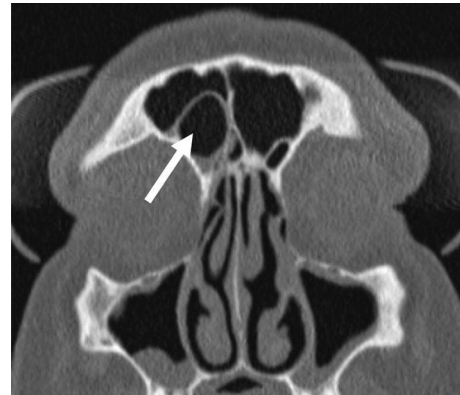


Fig. 6 Supra bulla frontal cell (coronal view)

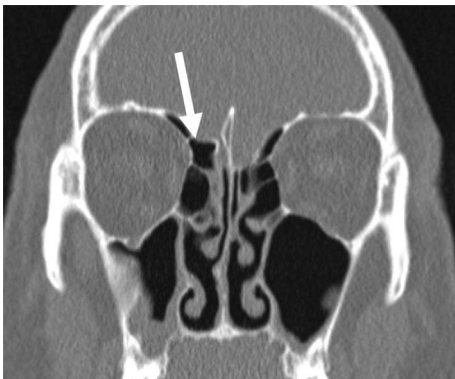

Fig. 4 Supra bulla cell (coronal view)

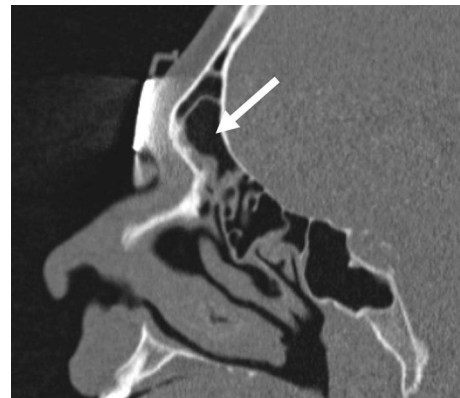


Fig. 7 Supra bulla frontal cell (sagittal view)

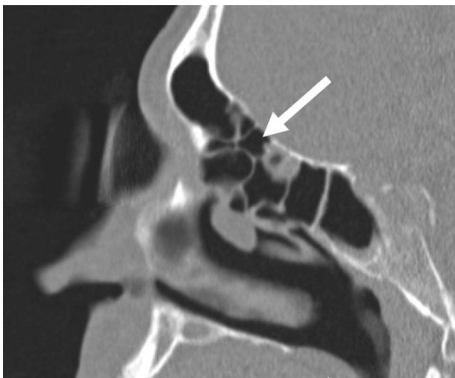

Fig. 5 Supra bulla cell (sagittal view)

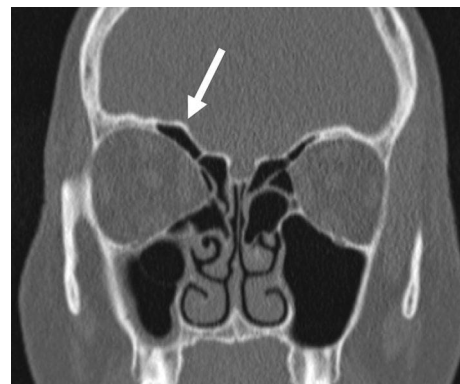


Fig. 8 Supraorbital ethmoid cell (coronal view)

Further cells/variety of the frontoethmoidal complex

Cells of the interfrontal septum (IFSC)

IFCs are medially located cells of the anterior ethmoid cell system, which are attached to the interfrontal septum

or localized within this septum. Since these are attached to the medial side of the drainage pathway of the frontal sinus, it is often lateralized or pushed towards posterior [1] (Figs. 9, 10).

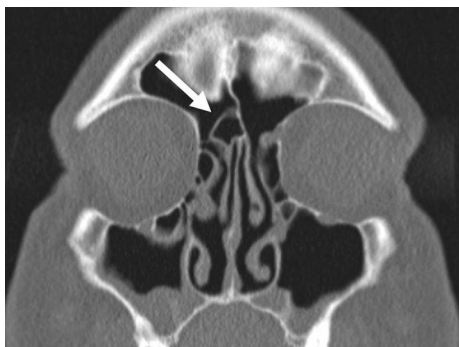

Fig. 9 Cell of the interfrontal septum (coronal view)

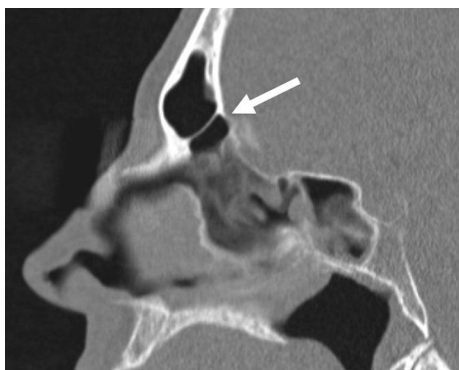

Fig. 10 Interfrontal septum cell (sagittal view)

Differences in depth of the olfactory fossa according to Keros

Level differences between the cranial ethmoid sinus and the lateral wall of the cribriform plate were classified according to Keros [9] (Table 1).

Assessment of mucosal pathologies of the paranasal sinuses

The evaluation of the opacification of the paranasal sinuses and the ostiomeatal complex is based on the staging system according to Lund and Mackay [10]. For each sinus cavity and for the ostiomeatal complex, points are awarded between 0–2:

- 0 = no signs of opacification.
- 1 = partial opacification.
- 2 = total opacification.

Table 1 Classification of level differences of the olfactory fossa according to Keros

Type I	1–3 mm (cranial ethmoid sinus at the same level of cribriform plate)
Type II	4–7 mm
Type III	8–16 mm (cranial ethmoid sinus significantly higher than cribriform plate: “dangerous ethmoid”)

Subsequently, the relationship of the two variables’ opacification and anatomical variation was shown in crosstabs and checked for statistical significance by Chi-square test and Fisher’s exact test.

Results

Age distribution

249 patients could be included in our study. Their age ranged between 14 and 95 years at the time of evaluation. The average age was 48.7 years (SD = 19.6). The age distribution is shown in Fig. 11. 48.2% (120) of the patients were female and 51.8% (129) were male.

Incidence of anatomical variants of the frontoethmoid region

Frontoethmoid cells

When presenting the frequencies of anatomical variants in the area of the frontoethmoid complex, a distinction must be made between a patient-related evaluation and an evaluation with respect to all examined frontoethmoid complexes. Theoretically, two agger nasi cells can be identified in one patient (one per side).

In the present analysis, however, the patient is considered to be “1” in $n = 249$ patients, even if the patient has a supra agger frontal cell on each side. The latter evaluation allows the statement: “In x patients, one or more supra-agger frontal cells could be detected.”

Incidence of anatomical variants

Table 2 describes in how many patients a particular cell type was detected, regardless of whether a cell occurred uni- or bilaterally.

Agger nasi cells were the most common variation. In 95.2% of the patients, this anatomical variant was detected uni- or bilaterally. Only 12 patients (4.8%) with no agger nasi cells at all were identified. Figure 12 depicts the incidence of the various frontoethmoidal cells.

Fig. 11 Age distribution of the patients

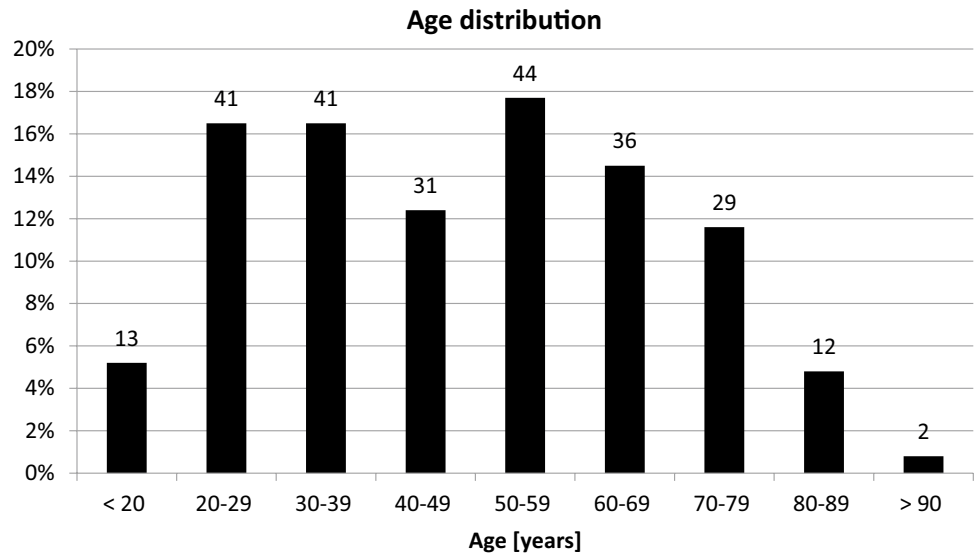


Table 2 Patient-related manifestation frontoethmoid cells

Frontoethmoidal cell	<i>n</i> = 249 Incidence (uni- or bilateral) <i>n</i> (%)
Agger nasi cell	237 (95.2%)
Supra agger cell	122 (49.0%)
Supra agger frontal cell	62 (24.9%)
Supra bulla cell	221 (88.8%)
Supra bulla frontal cell	66 (26.5%)
Supraorbital ethmoid cell	23 (9.2%)
Interfrontal septal cell	69 (27.7%)

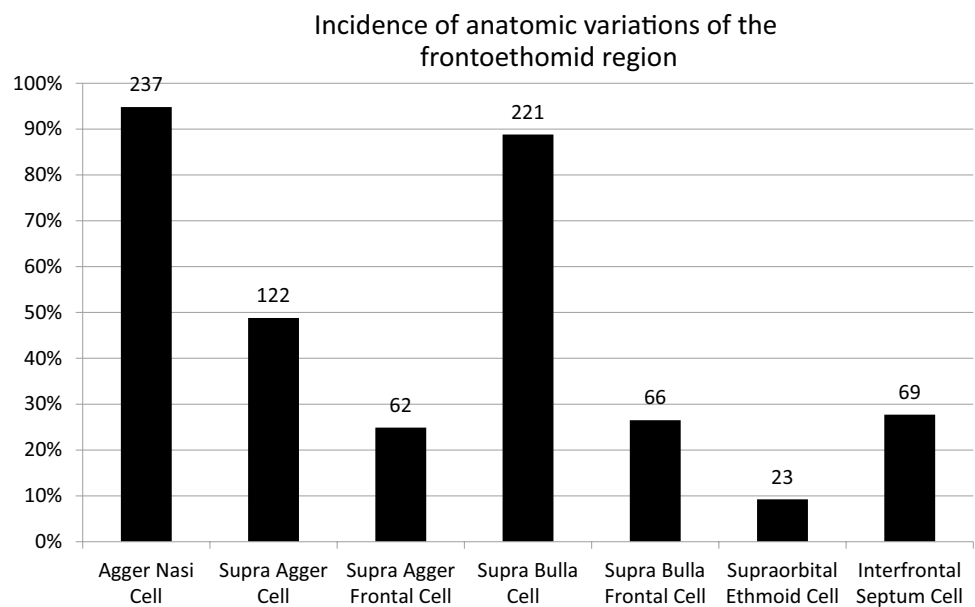
Incidence of frontoethmoid cells with pneumatization into the frontal sinus (SAFC, SBFC)

Single or bilateral occurrence of supra agger frontal cells was 24.9%. supra bulla frontal cells could be identified in 26.5% of the examined CT scans.

Incidence of pneumatized crista galli

The occurrence of a pneumatized crista galli was 41 of 249 (16.5%).

Fig. 12 Incidence of frontoethmoidal cells



Anatomical variants of the olfactory fossa

When determining the variants of the olfactory fossa, type 2 (82.3%) was the most common regarding the classification of Keros. A dangerous ethmoid configuration (Keros type 3) was found in 8.4% of all patients. Figure 13 shows the distribution of the three possible variants.

Coincidence of anatomical variants of the frontoethmoid complex and radiological signs of opacification

Forty five (18.1%) of 249 data sets had a uni- or bilateral opacification (partial or complete) of the frontal recess or sinus. 21 of these 45 data sets (47% out of 45 patients) simultaneously presented a supra agger nasi cell, 9 (20% out of 45 patients) exposed a supra agger frontal cell, and 9 (20% of 45 patients) a supra bulla frontal cell.

Figure 14 depicts the percentage distribution of the data sets, in which an opacification of the frontal recess and sinus was analysed. Figure 15 additionally shows the percentage of patients with opacification and simultaneous presence of an anatomical variation that affects the frontal sinus.

There was no statistically significant association between supra agger frontal cells and an ipsilateral opacification of the frontal sinus ($p=0.44$) regarding all included patients. The same result could be shown for supra bulla frontal cells and an ipsilateral opacification of the frontal sinus ($p=0.65$).

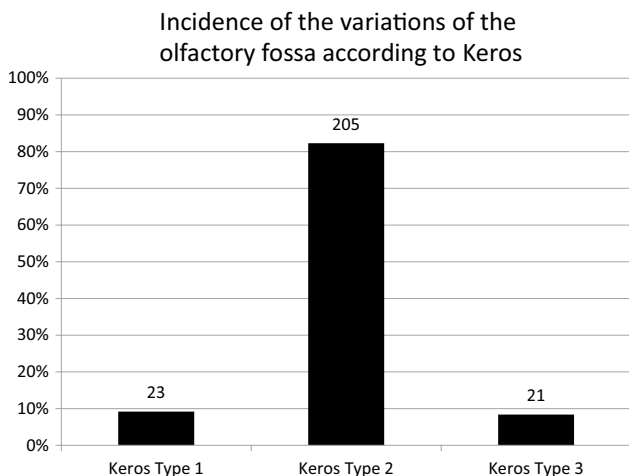


Fig. 13 Incidence of the variations of the olfactory fossa according to Keros

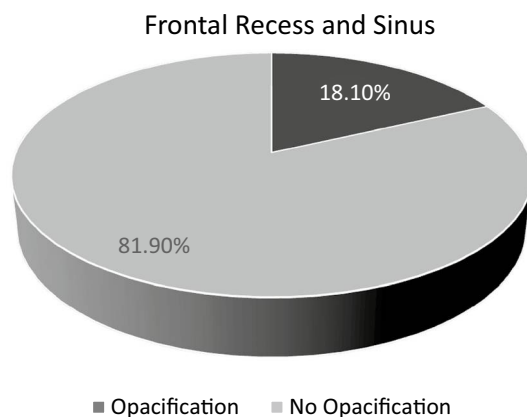


Fig. 14 Incidence of opacification regarding the frontal recess and sinus

Discussion

Regardless of the classifications used, grouping of anatomical variants remains partly subjective. For example, the difference of a supra agger cell to a supra agger frontal cell is determined by the pneumatization into the frontal sinus. The inferior border of the frontal sinus is the transition to the frontal recess which is defined as the narrowest AP diameter in the sagittal plane. Since this varies depending on the choice of the sagittal layer, it is examiner-dependent. There are a large number of studies using different methods to minimize inaccuracy in the evaluation [11–15], e.g.,

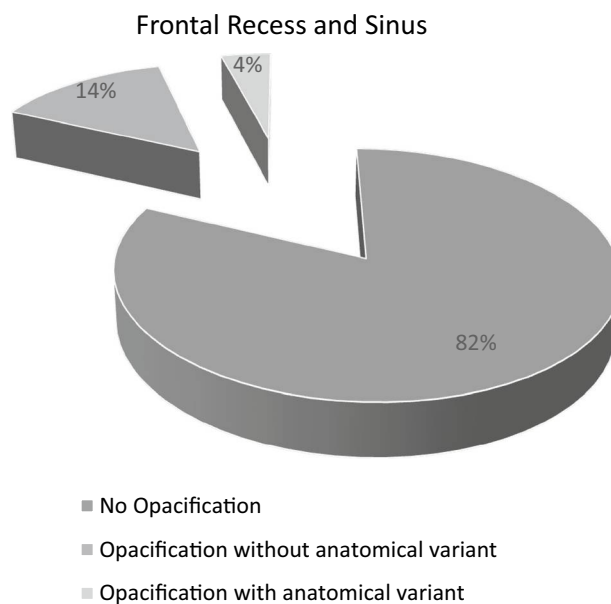


Fig. 15 Incidence of opacification of the frontal recess and sinus with (green) and without (orange) anatomical variation

multiple evaluation or different investigators. Nevertheless, in the present study, a high number of CT scans were analysed by two investigators and the easy applicable IFAC was used to get the most accurate results possible.

One limitation of the present study is patient selection. The available data are based on CT scans performed on patients with anamnestic chronic sinusitis. Therefore, the incidences cannot be considered representative for the general population. A cross-sectional study of this kind requires computed tomography to analyse the anatomical variants. This is not ethically justifiable, since even complaint-free individuals would have to be exposed to the radiation of a computed tomography. In this respect, from the authors' point of view, the present study design is the only possibility to analyse an approximate estimate of the incidence of anatomical variants in a large collective. The present results are, therefore, not to be considered to be representative for the normal population, but underline the statement that anatomical variants in the frontoethmoid complex are very common.

The IFAC is a new, simplified classification of anatomical variants of the frontoethmoid complex, which should be easy to learn and use. During the evaluation of the CT data sets of this study, which was performed by an experienced rhinologist and a PhD student, differences in the application concerning other classifications could be detected. The anatomical-reference-based nomenclature of the IFAC is easy applicable for users who are familiar with the anatomy of the paranasal sinuses, because no confusing proper or anatomically ambiguous names must be learned (e.g., frontoethmoidal cells according to Kuhn). In distinguishing between a supra agger frontal cell and a supra bulla frontal cell, this classification is much easier to learn, as the name already contains the anatomical difference between the two variations (pneumatization originating from the agger nasi region and pneumatization from the region of the ethmoid bulla). On the other hand, the distinction between a frontoethmoid cell type III (pneumatization to 50% of the height of the frontal sinus) and type IV (exceeding 50% of the height of the frontal sinus) of the conventional classification according to Bent and Kuhn was omitted [6].

For interventions on the frontal sinus, this difference is relevant, because frontoethmoidal cells, which do not pneumatize far into the frontal sinus, can be resected in a transnasal procedure, which is much more difficult for large cells filling almost the entire frontal sinus that may require an open access. However, in our opinion, this is only relevant in very few cases as the above-mentioned anatomical variation is very rare (0.1% of cases in a total of 641 CT data sets [16]).

Obviously, supra agger frontal cells and supra bulla frontal cells only have a negligible effect on the drainage of the frontal sinus. The presence of anatomical variation, according to the results of the present analysis, does not cause a

higher incidence of radiographic signs of sinusitis (partial or total opacification). This is consistent when comparing to results of previous studies using conventional classifications [16, 17]. In this respect, the frontal sinus should be treated carefully and only be surgically addressed in case of an anatomical variation, radiological signs of opacification, and simultaneously credible complaints of the patient.

To be able to determine the incidence of anatomical variants of the paranasal sinuses in the normal population, further investigations are necessary. Magnetic resonance imaging is conceivable, so that healthy volunteers can also be included, which could be the aim of future studies.

Compliance with ethical statement

Conflict of interest No one of the above-mentioned authors has a conflict of interest regarding this publication.

References

1. Wormald P-J, Hoseman W, Callejas C, Weber RK, Kennedy DW, Citardi MJ et al (2016) The International Frontal Sinus Anatomy Classification (IFAC) and Classification of the Extent of Endoscopic Frontal Sinus Surgery (EFSS). *Int Forum Allergy Rhinol* 6:677–696
2. Stammberger H, Hosemann W, Draf W (1997) Anatomische terminologie und nomenklatur für die nasennebenhöhlenchirurgie. *Laryngorhinootologie* 76:435–449
3. Wormald PJ, Chan SZX (2003) Surgical techniques for the removal of frontal recess cells obstructing the frontal ostium. *Am J Rhinol* 17(4):221–226
4. van Aleya O (1941) Frontal cells: an anatomic study of these cells with consideration of their clinical significance. *Arch Otolaryngol* 34:11–23
5. Lund VJ, Stammberger H, Fokkens WJ, Beale T, Bernal-Sprekelsen M, Eloy P et al (2014) European position paper on the anatomical terminology of the internal nose and paranasal sinuses. *Rhinol Suppl* 24:1–34
6. Kuhn FA (1996) Chronic frontal sinusitis: the endoscopic frontalrecess approach. *Oper Tech Otolaryngol Head Neck Surg* 7:222–229
7. Lee WT, Kuhn FA, Citardi MJ (2004) 3D computed tomographic analysis of frontal recess anatomy in patients without frontal sinusitis. *Otolaryngol Head Neck Surg* 131(3):164–173
8. Pianta L, Ferrari M, Schreiber A, Mattavelli D, Lancini D, Bottazzoli M et al (2016) Agger-bullar classification (ABC) of the frontal sinus drainage pathway: validation in a preclinical setting. *Int Forum Allergy Rhinol* 6:981–989
9. Keros P (1962) Über die praktische Bedeutung der Niveauunterschiede der Lamina cribrosa des Ethmoids. *Laryngol Rhinol Otol* 41:808–813
10. Lund V, Kennedy D (1997) Staging for rhinosinusitis. *Otolaryngol Head Neck Surg* 117(3):S35–S40
11. Lien CF, Weng HH, Chang YC, Lin YC, Wang WH (2010) Computed tomographic analysis of frontal recess anatomy and its effect on the development of frontal sinusitis. *Laryngoscope* 120(12):2521–2527
12. Park SS, Yoon BN, Cho KS, Roh HJ (2010) Pneumatization pattern of the frontal recess: relationship of the anterior-to-posterior

- length of frontal isthmus and/or frontal recess with the volume of agger nasi cell. *Clin Exp Otorhinolaryngol* 3(2):76–83
13. Kubota K, Takeno S, Hirakawa K (2015) Frontal recess anatomy in Japanese subjects and its effect on the development of frontal sinusitis: computed tomography analysis. *J Otolaryngol Head Neck Surg* 44(1):1–6
 14. Zhang L, Han D, Ge W, Tao J, Wang X, Li Y (2007) Computed tomographic and endoscopic analysis of supraorbital ethmoid cells. *Otolaryngol Head Neck Surg* 137:562–568
 15. Gu N (2017) Computed tomographic analysis : the effects of frontal recess morphology and the presence of anatomical variations on frontal sinus pneumatization. *J Craniofac Surg* 28(1):256–261
 16. Leunig A, Betz CS, Sommer B, Sommer F (2008) Anatomische varianten der nasennebenhöhlen; multiplanare CT-analyse an 641 patienten. *Laryngorhinootologie* 87(7):482–489
 17. Leunig A, Sommer B, Betz CS, Sommer F (2008) Surgical anatomy of the frontal recess—is there a benefit in multiplanar CT-reconstruction? *Rhinology* 46(3):188–194