

## ORIGINAL ARTICLE

# Dynamic optical coherence tomography of chronic venous ulcers

Jennifer Jahel Vélez González<sup>1</sup>  | Maximilian Berger MD<sup>1</sup>  | Stefan Schiele<sup>2</sup>  |  
 Anna Rubeck<sup>2</sup>  | Gernot Müller<sup>2</sup>  | Julia Welzel MD<sup>1</sup>  | Sandra Schuh MD, M.Sc.<sup>1</sup> 

<sup>1</sup>Department of Dermatology and Allergology, University Hospital Augsburg, Augsburg, Germany

<sup>2</sup>Institute of Mathematics, University of Augsburg, Augsburg, Germany

## Correspondence

Sandra Schuh, Department of Dermatology and Allergology, University Hospital Augsburg, Sauerbruchstr. 6, 86179 Augsburg, Germany.  
 Email: [sandra.schuh@uk-augsburg.de](mailto:sandra.schuh@uk-augsburg.de)

## Funding information

The project is part of the ADVANCE (Automatic Detection of Vascular Networks for Cancer Evaluation) project, which received funding from the European Union's ICT Policy Support Program as part of the Competitiveness and Innovation Framework Program, Grant/Award Number: Grant No.621015.

## Abstract

**Background:** Chronic ulcers, especially venous leg ulcers, are a major burden on the healthcare system. To date there are only few non-invasive established procedures for evaluation of blood perfusion in wounds. Dynamic optical coherence tomography (D-OCT) provides images of the skin's superficial vascularisation.

**Objectives:** This study aims to investigate if and how the D-OCT measurement of chronic wounds can provide new information about the vascularisation during the healing process.

**Methods:** We examined 16 venous ulcers over 16 weeks and evaluated the vessel morphology and density using D-OCT at the wound bed, borders, two centimetres adjacent to the wound and at non-ulcerated skin on the contralateral leg.

**Results:** In D-OCT scans *clumps* were unique and the most common vessel type in the wound area of venous ulcers, whereas *lines* and *serpiginous vessels* were the most common in non-ulcerated skin. At the wound border *mottle* and *cluster* patterns occurred more frequently. Healthy skin showed a significant increase of *mesh* pattern. Vessel density significantly increased at the wound area compared to non-ulcerated skin. During the healing process the wound border showed the most vascular changes while only an increase in *curves* was observed in the wound centre. Non-healing wounds had fewer *dots* and *blobs* at the borders, fewer *dots*, *coils*, *clumps*, *lines* and *serpiginous vessels* at the centre and fewer *dots* in adjacent skin. Temperature analysis showed higher temperatures in non-ulcerated skin, followed by the wound margin and centre. Non-healing wounds showed the lowest temperatures in the wound centre.

**Conclusions:** These results highlight the non-invasive use of D-OCT for the examination and monitoring of wound healing in chronic venous ulcers. D-OCT imaging of blood vessels may offer the potential to detect disorders of wound healing at an early stage, differentiate ulcers of different genesis and to tailor more individualized, patient-oriented therapy.

## INTRODUCTION

Venous ulcers of the lower extremity often imply a long, complicated and burdensome course.<sup>1</sup> The pain, impaired mobility, poor sleep, depression, restricted work capacity and social isolation result in a significantly diminished health-related quality of life for patients and their relatives.<sup>2</sup> Lower extremity ulcers belong with 64% to the most diagnosed

chronic wounds in Germany. The estimated prevalence of venous leg ulcers was 0.7% in Germany, whereas the prevalence of diabetic ulcers was 0.27%.<sup>3</sup>

Optical coherence tomography (OCT) is already well-established as a diagnostic device in non-melanoma skin cancer (NMSC).<sup>4</sup> This in vivo examination is non-invasive and painless.<sup>5,6</sup> The further development of OCT into dynamic optical coherence tomography (D-OCT) enabled the

This is an open access article under the terms of the [Creative Commons Attribution-NonCommercial-NoDerivs](https://creativecommons.org/licenses/by-nc-nd/4.0/) License, which permits use and distribution in any medium, provided the original work is properly cited, the use is non-commercial and no modifications or adaptations are made.

© 2023 The Authors. *Journal of the European Academy of Dermatology and Venereology* published by John Wiley & Sons Ltd on behalf of European Academy of Dermatology and Venereology.

imaging of small blood vessels in high resolution. D-OCT detects motion of blood of 0.1–1.0 mm/s. This allows the imaging of blood capillaries, but not from vessels with stationary blood or slowly flowing fluid, like in lymphatic vessels.<sup>7</sup> On these grounds D-OCT adds important information to the micro-morphology of the skin, which was feasible until now just by invasive skin biopsy. Although histological examination is still considered as gold-standard, a punch biopsy cannot be carried out twice at the same skin location and as a traumatic procedure it cannot be established as a standard for the monitoring of healing wounds.<sup>8,9</sup> This is why non-invasive devices like D-OCT are needed to examine the process of wound healing, for monitoring of chronic wounds like venous ulcers to collect important information which could support wound specialists to make effective therapeutic decisions.

## MATERIALS AND METHODS

### Patients and procedure

Twelve patients with 16 chronic lower extremity wounds were recruited for this study (eight women and four men with a median age of 73 years and range between 50 and 88 years). The study was carried out at the Department of Dermatology and Allergology of the University Hospital in Augsburg with the ethics committee approval of the Ludwig-Maximilians University (Project Number 755-16) as a prospective, observational, non-interventional, longitudinal study. This study was guided according to the principles of the Declaration of Helsinki and international guidelines concerning clinical studies.

We included patients  $\geq 18$  years with venous leg ulcers with a pre-existing duration from at least 3 months. They gave their written signed informed consent for performance of the study and publication of their case details. Bilateral ulcers were also included. Six patients suffered from Type 2 diabetes, one underwent topical therapy for psoriasis and one took an oral  $\beta$ -Blocker (propranolol). Six patients took anticoagulation.

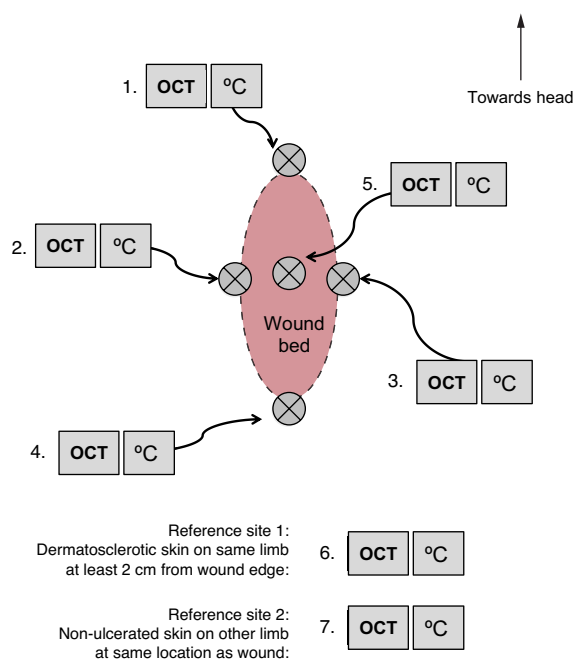
Patients were excluded with severe peripheral arterial occlusive disease, cancer, under treatment for cancer or waiting for interventions, decompensated cardiac failure, significant renal insufficiency, stroke, rheumatoid arthritis, scleroderma, Charcot foot, Raynaud's phenomena or pregnancy. Ulcers with superinfection were either excluded from this study or treated before beginning of the study.

Patients were scanned during the study at 4 weeks intervals, over a 16-week period, coinciding with their visits for dressing changes and clinical assessment in the standard course of care. All wounds were treated according to local treatment protocols. OCT measurements of the wound were made at baseline and at each subsequent patient visit with the D-OCT Vivosight Dx<sup>®</sup>. The wounds were photographed with a Canon Powershot A 1200 and at 15 cm distance from the wound. Skin temperature was measured with an

IR thermometer (Exergen Temporal Scanner TAT-2000). We documented wound healing based on the measurement of the ulcer dimensions (largest diameter, diameter in the orthogonal direction and the wound area) and of the calf circumference. Healing wounds were defined as such when they were 30% smaller by week 4, because then there is a chance to heal by week 12.<sup>10</sup> If they were not 30% smaller by week 4 or remained stable, they were named non-healing. The ankle brachial pressure index (ABPI) of all recruited patients was between  $\geq 0.5$  and  $< 1.2$  in the ulcerated leg. All patients received routine diagnostic with Duplex ultrasound prior to the study and other differential diagnosis were excluded prior to inclusion to the study due to results of taken punch biopsies. Venous insufficiency in the deep and/or superficial veins were found in all patients. The ulcers had a preexistence from 14 months to 15 years. Chronic wounds are those that have not healed after 12 weeks. These can be divided into healing and non-healing wounds. Non-healing wounds are wounds, where the patient's physical capacity does not allow the wound to heal or just to heal slower due to multiple causes, which makes them harder to treat.

To guarantee the replicability of OCT scans, the scans were done at standardized locations at the wound borders: at the upper, right, lower and left pole with patients' legs in supine position. One scan was done at the wound centre and the other two at comparative reference sites as internal controls:  $> 2$  cm adjacent from the ulcer in dermatosclerotic skin and at the same position as the ulcer on non-ulcerated skin of the contralateral limb (Figure 1).

The centre of the probe was positioned 2 mm from the clinical edge, and oriented in a way so that the scan



**FIGURE 1** Seven standardized scan locations of the wound for temperature and D-OCT measurement.

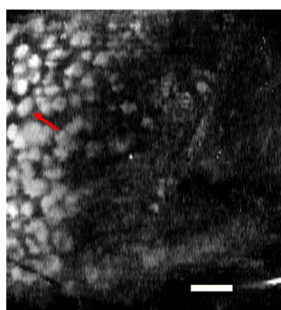
proceeds from the outside of the wound to the inside. The OCT probe was held with both hands ensuring that the probe tip touches the lesion only slightly to ensure that the pressure of the probe does not constrict the blood vessels.

## Dynamic OCT

The OCT device in this study is the ‘VivoSight Dx’ (Michelson Diagnostics Ltd) with a laser wavelength of 1305 nm.<sup>11</sup> It is CE-marked, and FDA 510(k) -approved. To avoid any risk of cross-contamination or infection, the probe was encased in a disposable transparent plastic sheath which was discarded after each patient. A new, pre-sterilized probe tip was provided for each patient at each visit.<sup>7</sup> The image resolution is <7.5 µm in the lateral and <5 µm in the axial direction.<sup>5</sup> The focal depth is 1–2 mm, but the D-OCT function is limited to a depth of 0.5 mm because of the speckle noise/signal ratio in the deeper parts of the skin.<sup>7,12</sup> A 3D image in a scanned field of view from 6 × 6 mm<sup>2</sup> takes 30 s. Through the colour camera, the position and monitoring of the lesion of interest is possible. No gel or oil is needed. D-OCT allows simultaneous visualisation of superficial blood vessels through detection of moving blood cells.<sup>5,12,13</sup> It permits imaging of capillaries (20 µm diameter) and enables to examine the perfusion of the mid/upper dermis, the vascular supply of the wounds.

## Analysis of OCT scans

For the vascular analysis of the D-OCT images at 300 µm in ‘en-face’ view the nomenclature from Ulrich et al. was used to assure replicability of the results.<sup>12</sup> We added a seventh vessel category, which we named ‘clump’. ‘Clumps’ appear as big, knot-like or glomerulum-like vessels (Figure 2). These were already described for the first time by our group in the already published analysis of week 0 of this study.<sup>7</sup> The present study focuses on the vessel analysis over 16 weeks. Each vessel morphology was visually estimated on a scale of 0–3, at which ‘0’ corresponded to absent, ‘1’ to a few, ‘2’ to



**FIGURE 2** Example of a D-OCT Scan at the wound border in the horizontal view at 300 µm. Image size 6 × 6 mm, *clumps* are shown like knot-like vessels (see red arrow). Scale bar equals 1 mm.

some and ‘3’ to many as described in previous studies. The blood vessel density was obtained in percent by the Image J® Tool “Measure” and the 3D plugin Volume Viewer.<sup>14–16</sup> This tool provides the average pixel intensity in the D-OCT dataset.<sup>7</sup> Statistical analyses included the vessel shapes (S-parameters), pattern and vessel density (D-parameters).<sup>12</sup> D-parameters included depth, density, diameter, direction and distribution of the vessels.

## Statistical analysis

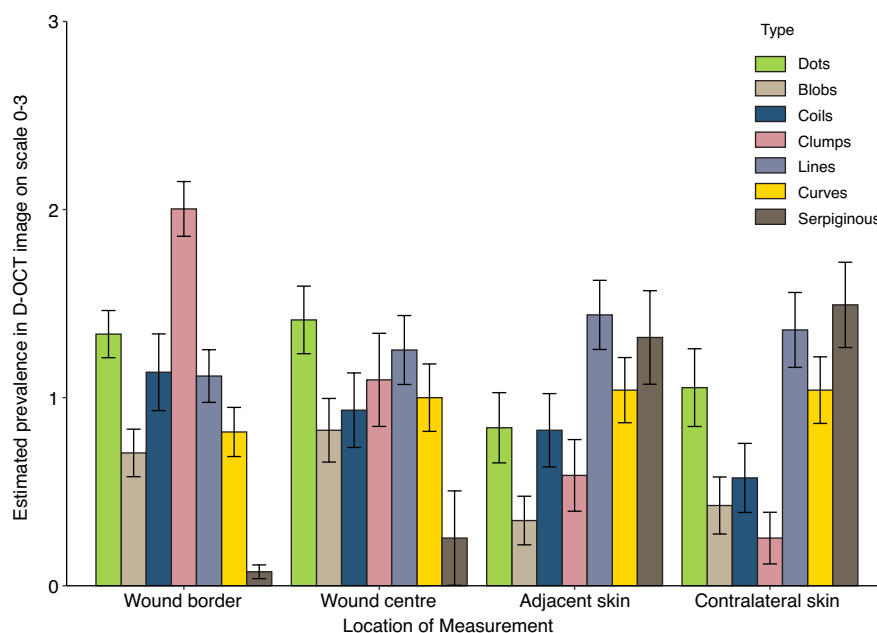
Data were collected with Microsoft® Excel® and Microsoft® PowerPoint® 2016 for Windows 10, and statistical analyses were performed with R Software Version 4.1.2 (R Core Team (2021). R: A language and environment for statistical computing. R Foundation for Statistical Computing, Vienna, Austria. URL <https://www.R-project.org/>). Statistical analysis comparing wound centre, wound border, adjacent and contralateral skin was performed using the Wilcoxon signed-rank test. A *p*-value less than 0.05 was considered statistically significant.

## RESULTS

Eleven of the sixteen venous ulcers healed, four did not heal and grew and one remained stable. Vessel morphology and density at the four wound borders were examined. Statistical analysis did not show significant differences between the four poles, so that the mean value was used subsequently as the ‘border’ score. A comparison of vessel morphology and density between dermatosclerotic adjacent skin and non-ulcerated skin at the contralateral limb was performed. Statistically significant differences were found for *coils* (*p* = 0.028) and *clumps* (*p* = 0.005).

## Vascular types depending on the measurement point location

In D-OCT scans, *clumps* were the most common vessel type observed at the wound border, while *serpiginous vessels* were the least common. In dermatosclerotic skin adjacent to the wound and non-ulcerated skin contralateral to the wound, *lines* and *serpiginous vessels* were the most common. The comparison between both non-ulcerated skin sites showed differences in vessel morphology with a more frequent occurrence of *coils* and *clumps* in skin adjacent to the wound (Figure 3). The highest differences between the measurement sites were found in the vessel forms *clumps*, *blobs* and *serpiginous vessels*. *Clumps* were seen more frequently at the wound border than in the centre and were more common at the wound area than in non-ulcerated skin. *Blobs* occurred more frequently at the wound area than in non-ulcerated skin, while it is the opposite for *serpiginous vessels* (Table 1).



**FIGURE 3** Overview of mean values of estimated vessel morphology of all five control appointments of the seven vessel shapes at the wound border, wound centre, in adjacent dermatosclerotic skin and in contralateral non-ulcerated skin. Scale ranges from 0 to 3, at which '0' corresponded to absent, '1' to a few, '2' to some and '3' to many vessels.

### Vascular arrangement depending on the measurement point location

Differences in vessel arrangement in all examined areas were seen. At the wound border, the *mottle* and *cluster* pattern were found more frequently. Non-ulcerated skin showed a significant increase in *mesh* pattern.

### Vascular types, arrangement and density over the course of time

During the healing process, the most striking changes were observed at the wound border during the 16 weeks. *Blobs* and *coils* were more common in week 0 than in week 16, while *curves* were less common (all  $p < 0.05$ ). In the wound centre, there were only significant differences for *curves*, which were higher in week 16 (1.14 vs. 0.25 at week 0;  $p = 0.021$ ). As expected, the non-ulcerated skin sites showed no variation in vascular morphology. The weekly comparison of the vessel morphology between the different measurement sites can be seen in Figure 4.

At the beginning the *cluster* pattern clearly predominated with a frequency of more than 80%, while after 16 weeks the *mottle* pattern was predominant with a frequency of 75%. This was the case for wound borders, while adjacent skin showed a *mottle* followed by a *mesh* pattern initially and changed to *no pattern*, *mottle* and *mesh* in the course of time. Vessel density was significantly higher at the wound edge than in non-ulcerated skin at weeks 0, 8 and 16. In the wound centre, this difference was only statistically significant in

weeks 0 and 16, with higher density in the wound centre than in non-ulcerated skin.

### Vascular analysis based on the healing tendency of the wounds

Non-healing wounds had fewer *dots* and *blobs* at the wound margin, fewer *dots*, *coils*, *clumps*, *lines* and *serpiginous vessels* at the centre, and fewer *dots* in healthy skin adjacent to the wound. *Serpiginous vessels* were not found in the wound centre in non-healing wounds (Figure 5).

Vessel density showed no differences between healing and non-healing wounds. At the wound margin, non-healing wounds showed a *mottle* pattern less frequently and a *cluster* pattern was more common compared to healing wounds. At the wound centre of non-healing wounds, the *mottle* pattern decreased and *no pattern* could be detected.

### Temperature measurement of the wounds

In non-ulcerated skin higher temperatures were found in comparison with the wound border but also at the border compared with the wound centre. Over time a significantly higher temperature was found in non-ulcerated skin at weeks 8 and 16 compared to the wound centre. In week 16 there was a significantly higher temperature at the wound border compared to the wound centre. The comparison of the temperature at the three measurement sites according to wound

**TABLE 1** Estimated mean value (MV) of vessel morphology prevalence, standard deviations (SD) and significance values (*p*-values) of the seven vessel shapes of all five control appointments at the wound border, wound centre, adjacent dermatosclerotic skin >2 cm adjacent from the ulcer and in non-ulcerated skin on the contralateral leg.

	Dots		Blobs		Coils		Clumps		Lines		Curves		Serpiginous	
	MV ± SD	<i>p</i> -Value	MV ± SD	<i>p</i> -Value	MV ± SD	<i>p</i> -Value	MV ± SD	<i>p</i> -Value	MV ± SD	<i>p</i> -Value	MV ± SD	<i>p</i> -Value	MV ± SD	<i>p</i> -Value
Wound border	1.34 (0.56)	0.261	0.71 (0.57)	0.140	1.14 (0.92)	0.107	2.00 (0.65)	<0.001	1.11 (0.63)	0.168	0.82 (0.59)	0.042	0.07 (0.16)	0.410
Wound centre	1.41 (0.81)		0.83 (0.76)		0.93 (0.89)		1.09 (1.11)		1.25 (0.82)		1.00 (0.81)		0.25 (1.13)	
Wound border	1.34 (0.56)	<0.001	0.71 (0.57)	<0.001	1.14 (0.92)	0.031	2.00 (0.65)	<0.001	1.11 (0.63)	0.006	0.82 (0.59)	0.040	0.07 (0.16)	<0.001
Adjacent skin	0.84 (0.84)		0.35 (0.58)		0.83 (0.88)		0.59 (0.86)		1.44 (0.83)		1.04 (0.78)		1.32 (1.12)	
Wound border	1.34 (0.56)	0.033	0.71 (0.57)	0.002	1.14 (0.92)	<0.001	2.00 (0.65)	<0.001	1.11 (0.63)	0.022	0.82 (0.59)	0.042	0.07 (0.16)	<0.001
Contralateral skin	1.05 (0.93)		0.43 (0.68)		0.57 (0.82)		0.25 (0.62)		1.36 (0.90)		1.04 (0.80)		1.49 (1.02)	
Wound centre	1.41 (0.81)	<0.001	0.83 (0.76)	<0.001	0.93 (0.89)	0.422	1.09 (1.11)	0.006	1.25 (0.82)	0.148	1.00 (0.81)	0.783	0.25 (1.13)	<0.001
Adjacent skin	0.84 (0.84)		0.35 (0.58)		0.83 (0.88)		0.59 (0.86)		1.44 (0.83)		1.04 (0.78)		1.32 (1.12)	
Wound centre	1.41 (0.81)	0.011	0.83 (0.76)	<0.001	0.93 (0.89)	0.004	1.09 (1.11)	<0.001	1.25 (0.82)	0.328	1.00 (0.81)	0.664	0.25 (1.13)	<0.001
Contralateral skin	1.05 (0.93)		0.43 (0.68)		0.57 (0.82)		0.25 (0.62)		1.36 (0.90)		1.04 (0.80)		1.49 (1.02)	

Note: The darker the color shade is, the higher is the significance.

status only showed differences at the wound centre, which had significantly lower temperatures in non-healing wounds (Figure 6).

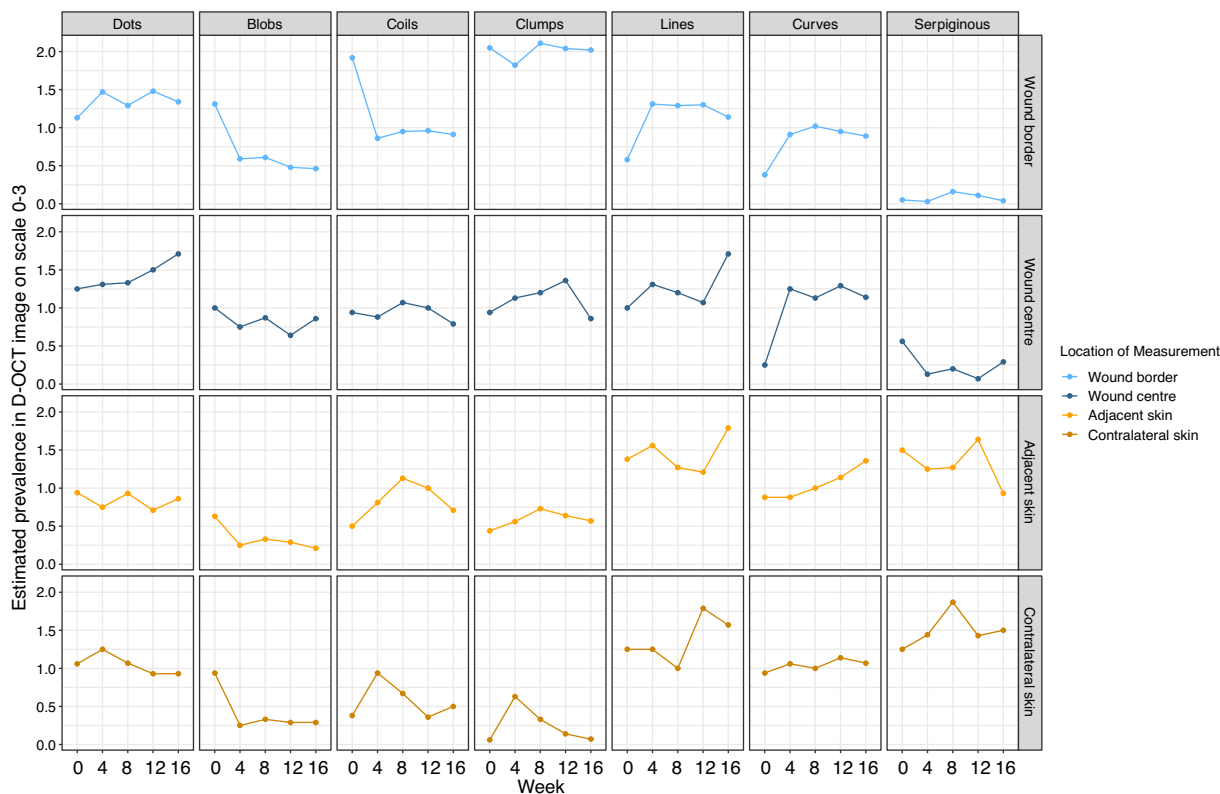
## DISCUSSION

Chronic leg ulcers are a major burden on our health care system. Thus, the need is high for new diagnostic methods which allow non-invasive repetitive evaluation of the vascularisation of chronic wounds. D-OCT is a non-invasive imaging device which allows the visualisation of superficial blood vessels of the skin and can be used for the follow-up examination of chronic wounds. Important information on chronic wounds can be obtained by D-OCT, which until now can only be partially reached by biopsies, only from one location, invasively and not replicable for monitoring.

This study showed a higher presence of *clumps* at the wound area of venous ulcers. These findings correlated with the histopathological glomerulum-like vessels in the wound area.<sup>17</sup> The presence of *serpiginous vessels* in non-ulcerated skin was striking and may be interpreted as a sign of microvaricosis.<sup>7</sup> At the wound border, the *mottle* and *cluster* patterns appeared more frequently, which can be explained by the higher presence of *clumps* in this area. In the wound centre, the *cluster* pattern was less frequent compared to the wound border due to a significantly lower occurrence of *clumps*. As expected, non-ulcerated skin showed a significant increase in *mesh* pattern due to more *serpiginous vessels*. The branching of *arborising*-type vessels was almost exclusively seen in non-ulcerated skin. This could be explained by the discontinuity of the tissue and their associated vessels in the ulcer, making it difficult for the vessels to fully mesh. Vessel density in the wound area was found to be significantly increased compared to non-ulcerated skin. This observation correlates with previously published findings that capillary volume at its peak in healing wounds can reach three or even more times of normal uninjured tissue.<sup>18</sup> These new capillaries supply the wound not only with oxygen, but also with nutrients and immune cells to support wound healing.<sup>19,20</sup>

*Blobs* and *coils* occurred more frequently at the wound edge in week 0, and *curves* more frequently in week 16. In the wound centre, only differences for *curves* were found, with an increase in week 16. *Curved* vessels can therefore be a good parameter for therapy response, as they appeared more common at the wound margin and centre with increasing treatment time. Vessel arrangement also showed significant differences over time. At the beginning the *cluster* pattern clearly predominated, while at the end of the study it was the *mottle* type. Thus, it can be concluded that newly developing vessels form a *mottled* pattern during wound healing.

Patients with non-healing wounds had fewer *dots*, *coils*, *clumps*, *lines* and *serpiginous* vessels at the wound centre. Unexpected was the fact that *serpiginous vessels* were not detected there. This could be explained by the depth of the



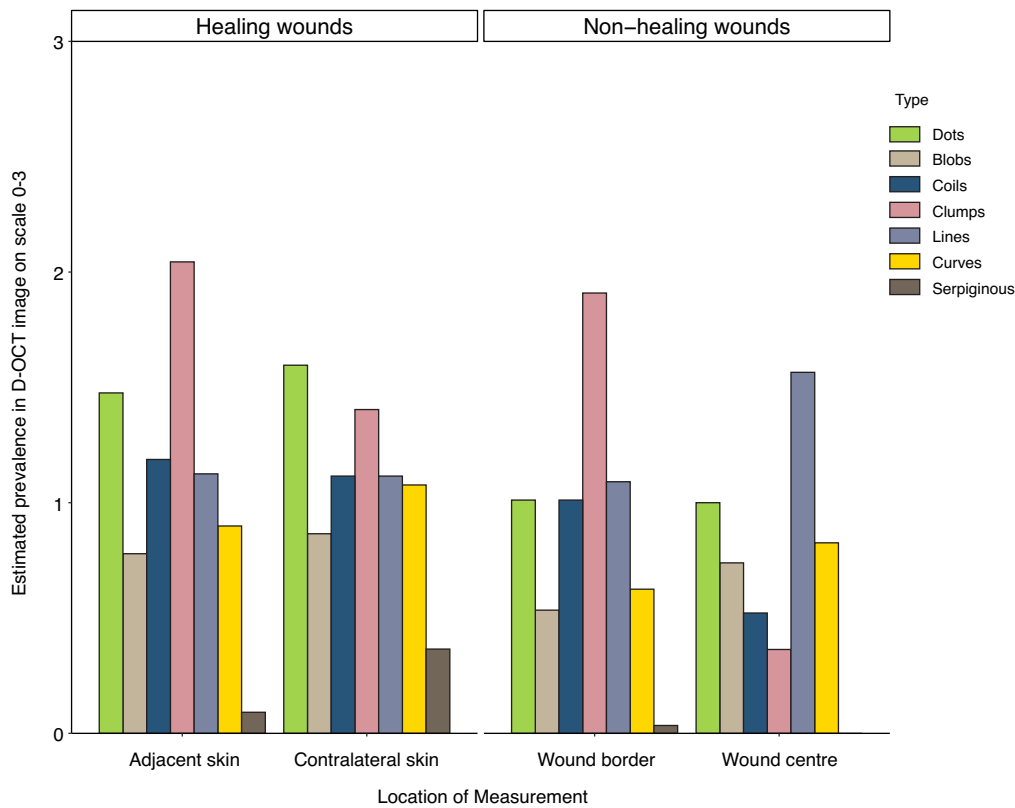
**FIGURE 4** Mean values of the measurements of the seven different vessel morphologies over time at the wound border, wound centre, adjacent dermatosclerotic skin and contralateral non-ulcerated skin. Scale ranges from 0 to 3, at which '0' corresponded to absent, '1' to a few, '2' to some and '3' to many vessels.

wound; a parameter we did not consider in this study. In deeper wound defects, the missing of *serpiginous* vessels may be explained by the absence of both dermal vascular plexuses. It is possible that the formation of these vessels is a feature of the progression of new vessel formation. Until now, these vessels were considered characteristic for healthy appearing skin in chronic venous insufficiency patients. These new findings could imply that the formation of new *serpiginous* vessels is essential for wound healing in the wound centre. Ultimately, the appearance of *serpiginous* vessels requires a larger tissue and vascular continuity than the other smaller vessel forms. Another interesting observation is that in non-healing wounds, most of the differences were found in the wound centre and not at the wound edge where re-epithelialisation and angiogenesis actually begin.<sup>21–24</sup> This observation should lead to further investigations and new therapeutic approaches concerning the wound centre.

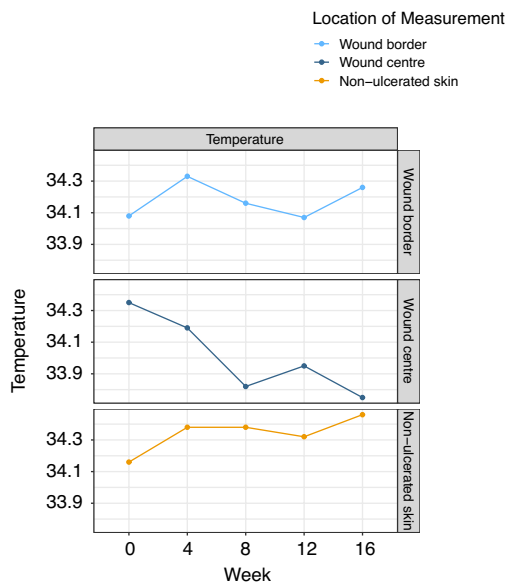
Higher temperatures were found in non-ulcerated skin followed by the wound border and then the wound centre. This may be explained by the discontinuity of blood flow in the ulcer. Other explanations could include differences in the wound milieu in chronic wounds compared to non-ulcerated skin, as the three key factors regulating skin temperature are the ambient temperature, the rate of water loss from the skin surface through sweating and the diffusion of thermal energy from within the body.<sup>25</sup>

Another reason could be the massive dermatoliposclerosis, leading to a prolonged diffusion distance due to a perivascular fibrosis and sclerosis.<sup>26</sup> The decrease in skin temperature following injury has been demonstrated as an indication of skin barrier impairment in mouse models.<sup>27</sup> In horses, wound temperature was shown to be lower in limb than in trunk wounds throughout the healing process.<sup>28</sup> Therapeutic approaches like temperature-activated dressings could be of great importance. Yao et al. proposed a programmable skin temperature-activated electromechanical synergistic wound dressing that successfully demonstrated wound healing in rats.<sup>29</sup> 'Smart' wound dressings could also be developed to raise the temperature of the wound bed to the physiological temperature of healthy skin. Another study tested the reduction of wound temperature during dressing changes. Pre-intervention temperatures showed that wound beds were slightly below the threshold of 33°C immediately after dressing removal (mean: 32.7°C). This value decreased by an average of two further degrees because of dressing change. A threshold of 33°C is required for normal cellular activity and temperatures below this threshold cause delayed wound healing.<sup>30</sup> Maintaining normothermia of the wound bed at dressing changes would be an interesting approach for future research.

Limitations of this study included the small sample size, the genesis and location of the wounds, which



**FIGURE 5** Mean values of the estimated prevalence of the seven vessel shapes of all five control appointments at the wound border and wound centre in healing and non-healing wounds. Scale ranges from 0 to 3, at which ‘0’ corresponded to absent, ‘1’ to a few, ‘2’ to some and ‘3’ to many vessels.



**FIGURE 6** Mean values of the temperature over time at the wound border, in the wound centre and in non-ulcerated skin.

were limited to venous ulcers. The subjectivity of the vessel analysis by the human eye should also not be underestimated.

## CONCLUSION

These results highlight the use of D-OCT for the examination and monitoring of venous ulcers. Based on this proof-of-concept study, further multicentre studies on chronic wounds should be conducted. Due to the steady ageing of our population, the incidence of chronic leg ulcers and wound healing disorders will continue to increase in the future. The blood vessel visualisation will allow us to detect disorders of wound healing at an early stage and may allow the differentiation of ulcers of different genesis in the future. A process that has so far been limited to clinical assessment. D-OCT will allow a more individual, patient-oriented therapy and monitoring of wounds.

## AUTHOR CONTRIBUTIONS

All authors fulfilled criteria for authorship. The specific contributions to the study and manuscript of each of the authors were: Sandra Schuh and Julia Welzel designed the research study and concept. Sandra Schuh and Julia Welzel contributed essential D-OCT images for the study and acquired all the data. Sandra Schuh, Jennifer Vélez and Julia Welzel planned the statistical analysis, Anna Rubeck, Stefan Schiele and Gernot Müller performed the statistical analysis supervised by Jennifer Vélez, Sandra Schuh and Julia Welzel. Jennifer Vélez analysed the D-OCT images supervised

by Sandra Schuh and Julia Welzel. Jennifer Vélez and Sandra Schuh wrote the paper, Maximilian Berger, Julia Welzel, Stefan Schiele, Anna Rubeck and Gernot Müller critically revised the manuscript. All authors have read and approved the final manuscript. They agreed to be accountable for all aspects of the work in ensuring that questions related to the accuracy or integrity of the work are appropriately investigated and resolved.

## ACKNOWLEDGMENTS

We thank our patients for participating in the study. Open Access funding enabled and organized by Projekt DEAL.

## FUNDING INFORMATION

The project is part of the ADVANCE (Automatic Detection of Vascular Networks for Cancer Evaluation) project, which received funding from the European Union's ICT Policy Support Program as part of the Competitiveness and Innovation Framework Program, Grant No. 621015. The manuscript reflects only the authors' views and the European Union is not liable for any use that might be made of information contained herein.

## CONFLICT OF INTEREST STATEMENT

Julia Welzel and Sandra Schuh received a fee for the development of an OCT training platform from the Company DermScan. Julia Welzel is the current President of the German Dermatological Society. The other authors declare that there is no conflict of interest, and that the manuscript contains original, unpublished work that is not being considered for publication elsewhere at this time.

## DATA AVAILABILITY STATEMENT

The data that support the findings of this study are available from the corresponding author upon reasonable request.

## ETHICS STATEMENT

The study was carried out with the ethics committee approval of the Ludwig-Maximilians University (Project Number 755-16) as a prospective, observational, non-interventional, longitudinal study. This study was guided according to the principles of the Declaration of Helsinki and international guidelines concerning clinical studies. They gave their written informed consent for publication of their case details.

## ORCID

Jennifer Jahel Vélez González  <https://orcid.org/0000-0003-2893-6188>

Maximilian Berger  <https://orcid.org/0009-0002-4649-3405>

Stefan Schiele  <https://orcid.org/0000-0003-2054-9052>

Anna Rubeck  <https://orcid.org/0009-0008-8730-7596>

Gernot Müller  <https://orcid.org/0000-0002-4426-6252>

Julia Welzel  <https://orcid.org/0000-0002-6099-7418>

Sandra Schuh  <https://orcid.org/0000-0002-1470-7619>

## REFERENCES

- Charles H. Does leg ulcer treatment improve patients' quality of life? *J Wound Care*. 2004;13:209–13.
- Hopman WM, Vandenkerkhof EG, Carley ME, Kuhnke JL, Harrison MB. Factors associated with health-related quality of life in chronic leg ulceration. *Qual Life Res*. 2014;23:1833–40.
- Heyer K, Herberger K, Protz K, Glaeske G, Augustin M. Epidemiology of chronic wounds in Germany: analysis of statutory health insurance data. *Wound Repair Regen*. 2016;24:434–42.
- Von Braunmühl T. Optical coherence tomography. *Hautarzt*. 2015;66:499–503.
- Schuh S, Berger M, Brunmeier G, Welzel J. Dynamic OCT - what do the vessels tell us? *Aktuel Dermatol*. 2020;46:158–70.
- Von Braunmühl T. Optische Kohärenztomographie. In: Welzel J, Sattler E, editors. *Nichtinvasive physikalische Diagnostik in der Dermatologie*. Berlin Heidelberg: Springer-Verlag; 2016. p. 49–62.
- Holmes J, Schuh S, Bowling FL, Mani R, Welzel J. Dynamic optical coherence tomography is a new technique for imaging skin around lower extremity wounds. *Int J Low Extrem Wounds*. 2019;18:65–74.
- Gambichler T, Jaedicke V, Terras S. Optical coherence tomography in dermatology: technical and clinical aspects. *Arch Dermatol*. 2011;303:457–73.
- Sattler E, Kästle R, Welzel J. Optical coherence tomography in dermatology. *J Biomed Opt*. 2013;18:061224.
- Gelfand J, Hoffstad O, Margolis D. Surrogate endpoints for the treatment of venous leg ulcers. *J Invest Dermatol*. 2002;119:1420–5.
- MichelsonDiagnostics. VivoSight OCT scanner – Technische Daten. <https://de.vivosight.com/forschungs-anwender/vivosight-scanner/#technische-daten>. (o. J.) [21.09.2021]
- Ulrich M, Themstrup L, De Carvalho N, et al. Dynamic optical coherence tomography of skin blood vessels - proposed terminology and practical guidelines. *J Eur Acad Dermatol*. 2018;32:152–5.
- Themstrup L, Welzel J, Ciardo S, Kaestle R, Ulrich M, Holmes J, et al. Validation of dynamic optical coherence tomography for non-invasive, in vivo microcirculation imaging of the skin. *Microvasc Res*. 2016;107:97–105.
- Welzel J, Schuh S. Noninvasive diagnosis in dermatology. *J Dtsch Dermatol Ges*. 2017;15:999–1016.
- Schuh S, Holmes J, Ulrich M, Themstrup L, Jemec GBE, de Carvalho N, et al. Imaging blood vessel morphology in skin: dynamic optical coherence tomography as a novel potential diagnostic tool in dermatology. *Dermatol Ther (Heidelb)*. 2017;7:187–202.
- Manfredi M, Grana C, Pellacani G. Proceedings of the 11th joint conference on computer vision, imaging and computer graphics theory and applications (VISIGRAPP). Vol 4. Rome: Scitepress; 2016. p. 234–40.
- Welt K, Gall N, Sindrilaru A, Scharffetter-Kochanek K. Pathogenese des chronisch-venösen Ulcus cruris. *Phlebologie*. 2005;34:81–6.
- DiPietro LA. Angiogenesis and scar formation in healing wounds. *Curr Opin Rheumatol*. 2013;25:87–91.
- Demidova-Rice TN, Durham JT, Herman IM. Wound healing angiogenesis: innovations and challenges in acute and chronic wound healing. *Adv Wound Care*. 2012;1:17–22.
- DiPietro LA. Angiogenesis and wound repair: when enough is enough. *J Leukoc Biol*. 2016;100:979–84.
- Glinos GD, Verne SH, Aldahan AS, Liang L, Nouri K, Elliot S, et al. Optical coherence tomography for assessment of epithelialization in a human ex vivo wound model. *Wound Repair Regen*. 2017;25:1017–26.
- Li J, Chen J, Kirsner R. Pathophysiology of acute wound healing. *Clin Dermatol*. 2000;25:9–18.
- Reinke JM, Sorg H. Wound repair and regeneration. *Eur Surg Res*. 2012;49:35–43.
- Tonnesen MG, Feng X, Clark RA. Angiogenesis in wound healing. *J Investig Dermatol Symp Proc*. 2000;5:40–6.
- Romanovsky AA. Skin temperature: its role in thermoregulation. *Acta Physiol*. 2014;210:498–507.



26. Klejtman T, Lazareth I, Yannoutsos A, Priollet P. Specific management of lipodermatosclerosis (sclerotic hypodermatitis) in acute and chronic phase. *J Med Vasc*. 2022;47:186–90.
27. Govil SK, Flynn AJ, Flynn GL, Ackermann C. Relationship of hairless mouse skin surface temperature to wound severity and maturation time. *Skin Pharmacol Appl Skin Physiol*. 2003;16:313–23.
28. Celeste CJ, Deschesne K, Riley CB, Theoret CL. Skin temperature during cutaneous wound healing in an equine model of cutaneous fibroproliferative disorder: kinetics and anatomic-site differences. *Vet Surg*. 2013;42:147–53.
29. Yao G, Mo X, Yin C, Lou W, Wang Q, Huang S, et al. A programmable and skin temperature-activated electromechanical synergistic dressing for effective wound healing. *Sci Adv*. 2022;8:eabl8379.
30. McGuinness W, Vella E, Harrison D. Influence of dressing changes on wound temperature. *J Wound Care*. 2004;13:383–5.

**How to cite this article:** Vélez González JJ, Berger M, Schiele S, Rubeck A, Müller G, Welzel J, et al. Dynamic optical coherence tomography of chronic venous ulcers. *J Eur Acad Dermatol Venereol*. 2024;38:223–231. <https://doi.org/10.1111/jdv.19496>