

Cause or compensation? Complex changes in cerebello-thalamo-cortical networks in pathological action tremor

Jan Raethjen, Muthuraman Muthuraman

Angaben zur Veröffentlichung / Publication details:

Raethjen, Jan, and Muthuraman Muthuraman. 2015. "Cause or compensation? Complex changes in cerebello-thalamo-cortical networks in pathological action tremor." *Brain* 138 (10): 2808–10. <https://doi.org/10.1093/brain/awv238>.

Nutzungsbedingungen / Terms of use:

licgercopyright

Dieses Dokument wird unter folgenden Bedingungen zur Verfügung gestellt: / This document is made available under these conditions:

Deutsches Urheberrecht

Weitere Informationen finden Sie unter: / For more information see:

<https://www.uni-augsburg.de/de/organisation/bibliothek/publizieren-zitieren-archivieren/publiz/>



Cause or compensation? Complex changes in cerebello-thalamo-cortical networks in pathological action tremor

Tremor is one of the most common clinical neurological symptoms. Its high prevalence in neurological patients is not surprising given the architecture of the CNS. Largely organized in loops of reciprocal inhibitory and excitatory connections on the neuronal as well as the network level, the CNS is prone to producing oscillatory activity (Shaikh *et al.*, 2008). In fact, flexibly coupled

oscillations between and within different neuronal populations and brain regions represent an important functional principle of the healthy human brain (Uhlhaas *et al.*, 2010). A number of oscillatory activities in the motor system in different frequency bands are coupled not only between different centres of the brain, but also with the peripheral muscles. Although the exact function of these oscillations is still under debate they seem to play an important role in human central motor control (Kristeva *et al.*, 2007). However, when these centrally generated oscillations become higher in amplitude and lower in frequency

they no longer contribute to fine motor control but impede it. The basis of the transition from physiological oscillations during normal motor control to pathological action tremors is not clear (Elble *et al.*, 2005). The emergence of new central oscillators at the tremor frequency is one possibility; however, a breakdown of compensatory mechanisms that would otherwise prevent such deleterious oscillatory motor activity is probably at least as important for tremor pathogenesis.

Whereas electrophysiological methods (e.g. EEG, MEG) are a powerful means of recording and analysing

tremor-related brain activity—that is, detecting the tremor oscillators (Timmermann *et al.*, 2004)—compensatory activities are more difficult to resolve. Either they are similarly coupled to the peripheral tremor rhythm and cannot be distinguished from the oscillators or they occur at completely unrelated frequencies. Functional MRI methods can detect a much broader spectrum of anatomical and functional states, and are more sensitive to both tremor-related and compensatory changes. One problem of resolving action tremor-related phenomena in functional MRI analyses, however, is the simultaneous occurrence of movement- and tremor activation. Action tremors emerge only during active muscle innervation and movement. Thus any tremor recording is superimposed on motor activity, making it difficult to separate tremor-related from movement-related changes in the MRI scanner.

In this issue of *Brain*, Gallea *et al.* (2015) study the central network of pathological action tremor using an approach that overcomes these problems. Using resting state functional MRI, they have looked specifically at activity in different parts of the cerebellum, the thalamus, and frontal motor areas including the primary motor cortex (M1) and the supplementary motor area (SMA), in 20 well-characterized patients with essential tremor and 20 age-matched controls. The MRI signal was analysed with measures of volume (voxel-based-morphometry) and anatomical connections (fractional anisotropy/tractography). In addition, the functional parameters ‘amplitude of low frequency spontaneous BOLD fluctuation’ (ALFF) and effective functional connectivity between the different motor areas under study were analysed using dynamic causal modelling (DCM). As a first step, all measures were compared between healthy controls and patients in order to identify brain regions in which changes in structure and function play an intrinsic role in tremor. Those measures that differed significantly in the patients

were then correlated with clinical characteristics (tremor frequency, tremor amplitude, clinical tremor scores, disease duration); this was done for each of the altered areas, to identify their role in the tremor network.

The key finding of Gallea *et al.* (2015) was of opposing changes in the cortical and cerebellar areas under study. The cerebellum showed a decrease in grey matter volume, which was positively correlated with the tremor frequency but without other correlations with any of the clinical characteristics. The SMA showed an increase in volume, which was negatively correlated with the cerebellar volume and with the tremor frequency and positively correlated with tremor intensity and disease duration. Trends in the same direction were found for M1. Spontaneous low frequency blood oxygen level-dependent (BOLD) signal fluctuations in cortical regions were correlated with a number of clinical tremor characteristics, whereas these fluctuations in the cerebellum were completely unrelated to these measures or to the course of the disease. If the tremor network were simply an oscillating loop involved in the production and transmission of tremor oscillations as shown in EEG and MEG studies (Hellwig *et al.*, 2001), one would expect concordant functional MRI changes in all its constituents. Thus the new findings of Gallea *et al.* convincingly indicate highly differential roles for the network components beyond oscillation. Action tremor in essential tremor evolves slowly over time and it is likely that the emergence of pathological oscillations is accompanied by compensatory activities. These compensatory mechanisms may significantly delay the onset of clinically visible tremor, which probably occurs only after breakdown of these mechanisms in the subclinical phase of the disease.

The findings of Gallea *et al.* are in keeping with a primary cerebellar defect leading to the emergence of an oscillator which sets the tremor frequency. But the clinical

manifestation of tremor is dependent on the cortical output. The strong correlations between MRI measures in M1—and especially the SMA—and clinical tremor characteristics support this. That the mostly opposing cerebellar changes are relatively independent of tremor amplitude and disease duration seems to indicate that the cortical MRI changes are secondary, and are not solely related to tremor output but also reflect compensatory mechanisms as expected in the evolution of tremor. This interpretation remains speculative, of course, but it is in line with other published results on the pathophysiology of essential tremor: it is well documented that the cerebellum is the key structure in the emergence of essential tremor (Louis *et al.*, 2007; Brittain *et al.*, 2015). The cortical motor areas have been shown to be part of the tremor network in a number of studies (Schnitzler *et al.*, 2009). And for presymptomatic relatives of patients with essential tremor it has been shown that the oscillatory activity in the motor cortex does not show subclinical oscillations at the tremor frequency but an enhancement of the physiological corticomuscular coupling in the beta-band (Raethjen *et al.*, 2013). This may well be the electrophysiological correlate of cortical compensation hypothesized by Gallea *et al.* on the basis of their MRI results.

Taking all the results together we can hypothesize that there is an evolution of the tremor network from the presymptomatic to the symptomatic phase of the disease (Fig. 1). In the early, presymptomatic phase of essential tremor, it is mainly the cerebellum that is affected and which probably starts to produce pathological oscillatory activity; however, this activity does not reach the muscles because M1 and the SMA play a largely compensatory role by enhancing their physiological oscillatory connections with the peripheral muscles. In the symptomatic phase the oscillations transmitted from the cerebellum to the cortex become so strong that compensation in M1 breaks down, passing the

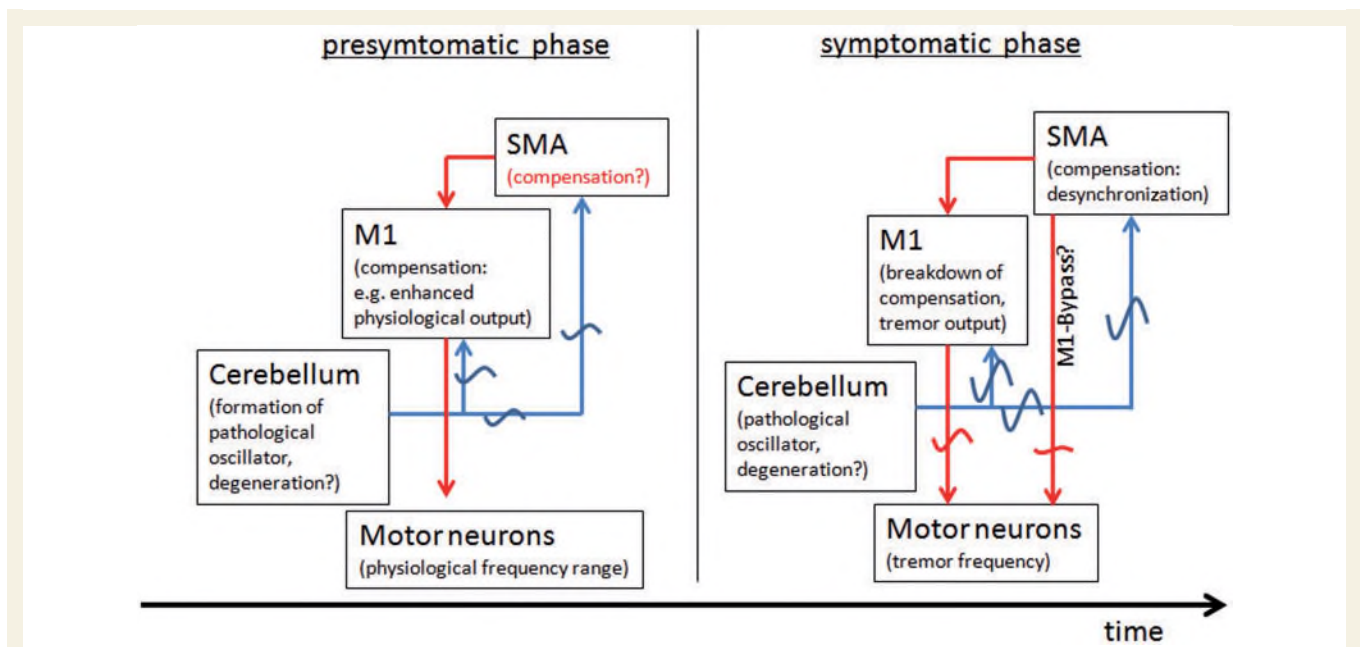


Figure 1 Hypothetical schemata of the cerebello-cortical network in the presymptomatic and symptomatic stages of essential tremor. See text for explanations.

oscillatory signals on to the muscles so that the tremor becomes visible. The SMA may keep up its compensatory role and possibly acts to desynchronize the tremor oscillations in other motor areas (Gallea *et al.*, 2015). Indeed, it may normalize the corticospinal output by taking over from and bypassing M1 as implied by the tractography and DCM results of Gallea *et al.* Although this is a highly simplified model, ignoring the thalamus and other cortical motor and higher order sensory areas which may also play a compensatory role in essential tremor, it contains a number of new hypotheses driven by the paper of Gallea *et al.* These clearly need to be tested with longitudinal studies that combine functional MRI and electrophysiology. But ultimately, more detailed insights into the nature of compensatory activities that counter tremor oscillations have the potential to aid the development of electrophysiological interventions and possibly pharmacological treatments for action tremor.

Jan Raethjen^{1,2} and
Muthuraman Muthuraman²

¹ *Neurology Clinic, Preußerstraße 1-9, 24105 Kiel, Germany*

² *Department of Neurology, University of Kiel, Schittenhelmstr. 10, 24105 Kiel*

Correspondence to: Jan Raethjen
E-mail: j.raethjen@neurologie.uni-kiel.de

References

- Brittain JS, Cagnan H, Mehta AR, Saifee TA, Edwards MJ, Brown P. Distinguishing the central drive to tremor in Parkinson's disease and essential tremor. *J Neurosci* 2015; 14: 795–806.
- Elble RJ, Higgins C, Elble S. Electrophysiologic transition from physiologic tremor to essential tremor. *Mov Disord* 2005; 20: 1038–42.
- Gallea C, Popa T, García-Lorenzo D, Valabregue R, Legrand AP, Marais L, et al. Intrinsic signature of essential tremor in the cerebello-frontal network. *Brain* 2015; 138: 2920–33.
- Hellwig B, Häussler S, Schelter B, Lauk M, Guschlbauer B, Timmer J, et al. Tremor-correlated cortical activity in essential tremor. *Lancet* 2001; 17: 519–23.
- Kristeva R, Patino L, Omlor W. Beta-range cortical motor spectral power and corticomuscular coherence as a mechanism for

effective corticospinal interaction during steady-state motor output. *Neuroimage* 2007; 36: 785–92.

Louis ED, Faust PL, Vonsattel JP, Honig LS, Rajput A, Robinson CA, et al. Neuro-pathological changes in essential tremor: 33 cases compared with 21 controls. *Brain* 2007; 130: 3297–307.

Raethjen J, Muthuraman M, Kostka A, Nahrwold M, Hellriegel H, Lorenz D, et al. Corticomuscular coherence in asymptomatic first-degree relatives of patients with essential tremor. *Mov Disord* 2013; 28: 679–82.

Schnitzler A, Münks C, Butz M, Timmermann L, Gross J. Synchronized brain network associated with essential tremor as revealed by magnetoencephalography. *Mov Disord* 2009; 24: 1629–35.

Shaikh AG, Miura K, Optican LM, Ramat S, Tripp RM, Zee DS. Hypothetical membrane mechanisms in essential tremor. *J Transl Med* 2008; 6: 68. doi: 10.1186/1479-5876-6-68.

Timmermann L, Gross J, Butz M, Kircheis G, Haussinger D, Schnitzler A. Pathological oscillatory coupling within the human motor system in different tremor syndromes as revealed by magnetoencephalography. *Neuro Clin Neurophysiol* 2004; 30: 26.

Uhlhaas PJ, Roux F, Rodriguez E, Rotarska-Jagiela A, Singer W. Neural synchrony and the development of cortical networks. *Trends Cogn Sci* 2010; 14: 72–80.