

## **Dynamic imaging of coherent sources: identification of neuronal networks underlying frequency-associated EEG patterns**

**Natia Japaridze, Michael Siniatchkin, Muthuraman Muthuraman, Jan Raethjen, Ulrich Stephani, F. Moeller**

### **Angaben zur Veröffentlichung / Publication details:**

Japaridze, Natia, Michael Siniatchkin, Muthuraman Muthuraman, Jan Raethjen, Ulrich Stephani, and F. Moeller. 2013. "Dynamic imaging of coherent sources: identification of neuronal networks underlying frequency-associated EEG patterns." *Zeitschrift für Epileptologie* 26 (1): 19-24.  
<https://doi.org/10.1007/s10309-012-0292-0>.

### **Nutzungsbedingungen / Terms of use:**

**licgercopyright**

Dieses Dokument wird unter folgenden Bedingungen zur Verfügung gestellt: / This document is made available under these conditions:

**Deutsches Urheberrecht**

Weitere Informationen finden Sie unter: / For more information see:

<https://www.uni-augsburg.de/de/organisation/bibliothek/publizieren-zitieren-archivieren/publiz/>



N. Japaridze<sup>1</sup> · M. Siniatchkin<sup>2</sup> · M. Muthuraman<sup>3</sup> · J. Raethjen<sup>3</sup> · U. Stephani<sup>1</sup> · F. Moeller<sup>1</sup>

<sup>1</sup> Clinic for Child Neurology, Department of Neuropediatrics, Christian-Albrechts-University of Kiel

<sup>2</sup> University Hospital of Child and Adolescent Psychiatry, Johann Wolfgang

Goethe-University of Frankfurt, Frankfurt am Main

<sup>3</sup> Department of Neurology, Christian-Albrechts-University of Kiel

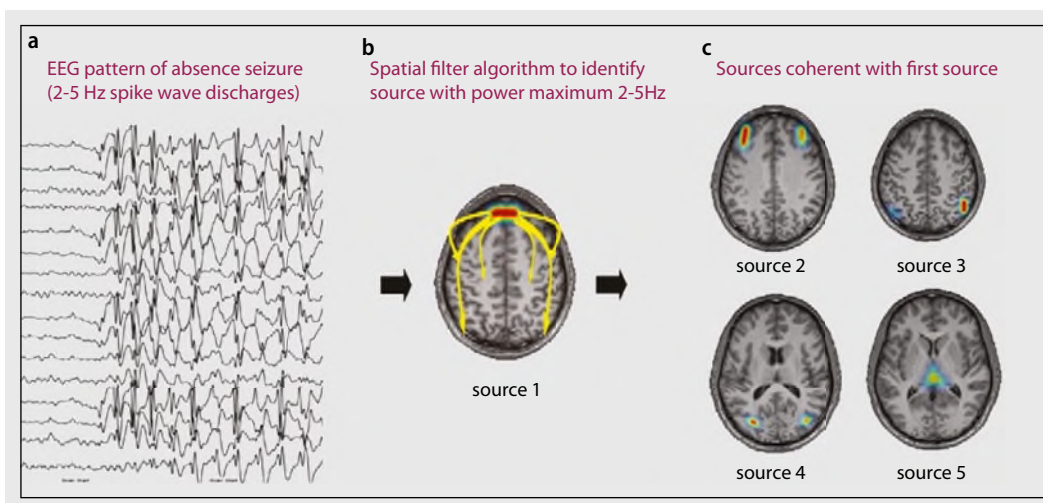
# Dynamic imaging of coherent sources

## Identification of neuronal networks underlying frequency-associated EEG patterns

Good temporal resolution of the electroencephalogram (EEG) permits good interpretation of different parts of neuronal networks, such as the separation of brain areas involved in the generation of epileptic activity from regions of propagation [1, 2, 3]. However, EEG signals measured on the scalp surface do not directly indicate the location of the active neurons in the brain due to the vagueness of the underlying static electromagnetic inverse problem [4]. It is particularly challenging to measure electric sources in deep brain structures: Previous studies on EEG source analyses in generalized spike and wave activity did not detect thalamic sources which, however,

is crucially important for the complete representation of the neuronal networks including both cortical and subcortical structures [5, 6, 7]. Recent achievements in the development of EEG inverse and forward solutions substantially improved the localization power of the EEG. Dynamic imaging of coherent sources (DICS) is one of these solutions. DICS is a source analysis method which is able to detect brain regions that are coherent, hence functionally related to each other [8]. DICS works in the frequency domain for EEG and magnetoencephalographic (MEG) data and is able to describe neuronal networks by imaging power and coherence of oscillatory

brain activity [8] (for illustration of the method please see [Fig. 1](#)). Applied to different types of tremor and voluntary motor control, DICS was able to characterize networks including deep structures, such as thalamus, cerebellum and brainstem in MEG [8, 9, 10, 11, 12, 13] as well as in EEG studies [14, 15, 16]. The DICS method employs a spatial filter algorithm [17] to identify the spatial power maximum or coherence in the brain for a particular frequency band. It uses a regularization parameter which determines the spatial extent of source representation. The brain region representing the strongest power in a specific frequency band can subsequently be used as a ref-



**Fig. 1** ◀ a Typical EEG pattern for absence seizures: generalized, high amplitude 2–5 Hz spike and wave discharges. b Spatial filter is applied in order to identify sources with the maximum power in the specific frequency band. c Subsequent coherent sources in the 2–5 Hz frequency band

erence region for cortico-cortical coherence analysis [8]. In order to create topographic maps, the spatial filter is applied to a large number of voxels covering the entire brain. For the detailed description of the spatial filter see Muthuraman et al. [18]. The forward problem is solved by estimating the lead-field matrix (LFM) with specified models for the brain. The LFM contains information about the geometry and the conductivity of the model; it is calculated using the boundary-element method (BEM) [19]. For a complete description of the solution for the forward problem see Muthuraman et al. [20].

However, DICS does not provide information regarding the effective connectivity between the signals. In order to study the direction of informational flow between the signals, the method of renormalized partial directed coherence (RPDC) [21] can be applied. RPDC is a technique performed in the frequency domain to detect the direction of information flow from one signal to the other and vice versa. The pooled time courses of all the voxel source signals identified in a source need to be taken for the calculation of the RPDC. This method applies a multivariate (MVAR) modeling approach which uses an autoregressive process to obtain the coefficients of the signals in the predefined frequency band [21].

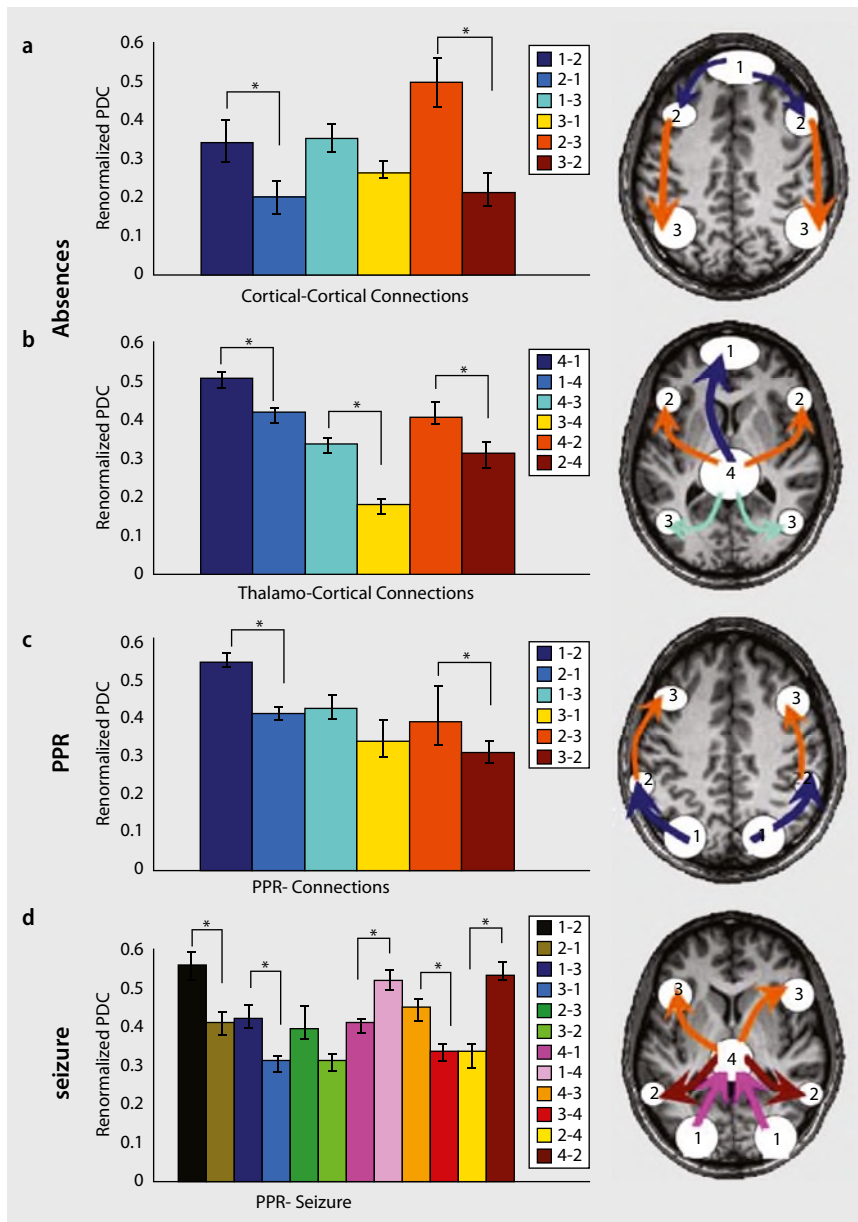
This focus article summarizes studies representing the ability of DICS and RPDC to detect cortical and subcortical neuronal sources and describes networks underlying different frequency-associated EEG abnormalities, thus contributing to the better understanding of these epilepsies.

### **DICS in absences and generalized photoparoxysmal responses**

In the study of Moeller et al. [14] DICS was applied to different types of generalized epileptiform discharges, such as absence seizures (10 patients) and photoparoxysmal responses (PPR; 8 patients) to describe the representation and propagation of these discharges in the brain. In order to validate the source localization

DICS analysis was performed on EEGs recorded in EEG-fMRI studies [22, 23, 24, 25]. Thus it was possible to directly compare the results of the DICS analysis with EEG-fMRI results for the same events and patients. Generalized spike-and-wave discharges (GSW) is a high amplitude oscillatory activity with a well-defined frequency range, which makes it an ideal condition to perform DICS. The study showed that similar networks were detected by EEG-fMRI and DICS in absence seizures, PPR and PPR preceding a generalized tonic-clonic seizure. Interestingly, the best concordance between the two methods was found in the thalamus which was involved in all absence

patients and in none of the PPR patients as revealed by both methods. However, both DICS and EEG-fMRI showed thalamic involvement when PPR preceded a generalized tonic-clonic seizure. Concordant results were also found for the default mode network and the occipital cortex in the case of absences and for the occipital cortex and the parietal and premotor regions in PPR. Thus this study confirmed that in case of high amplitude epileptic activity DICS is able to detect networks similar to EEG-fMRI including subcortical structures. However, the spatial resolution of both methods is different and the BOLD activation and oscillatory activity are not equivalent. This may



**Fig. 2** ▲ Renormalized directed partial coherence (RPDC). *Left* RPDC for all directions of connections are shown in *bar graphs*. Directions which were significantly stronger are indicated by an *asterisk*. *right* RPDC connections which were significantly stronger are shown schematically for all sources overlaid on the brain. **a** Cortical–cortical connections of the sources in absences: information flow from the frontomedial cortex via the prefrontal cortex to the parietal cortex. **b** Thalamo–cortical connections of the sources in absences: RPDC from the thalamus to all other sources are stronger. **c** Cortical connections of the sources in PPR: information flow from the occipital cortex via the intraparietal sulcus to the premotor cortex. **d** Cortical–cortical and thalamo–cortical connections of the sources in a patient in whom PPR was followed by a generalized tonic–clonic seizure. (Adapted from [14], with permission from John Wiley & Sons)

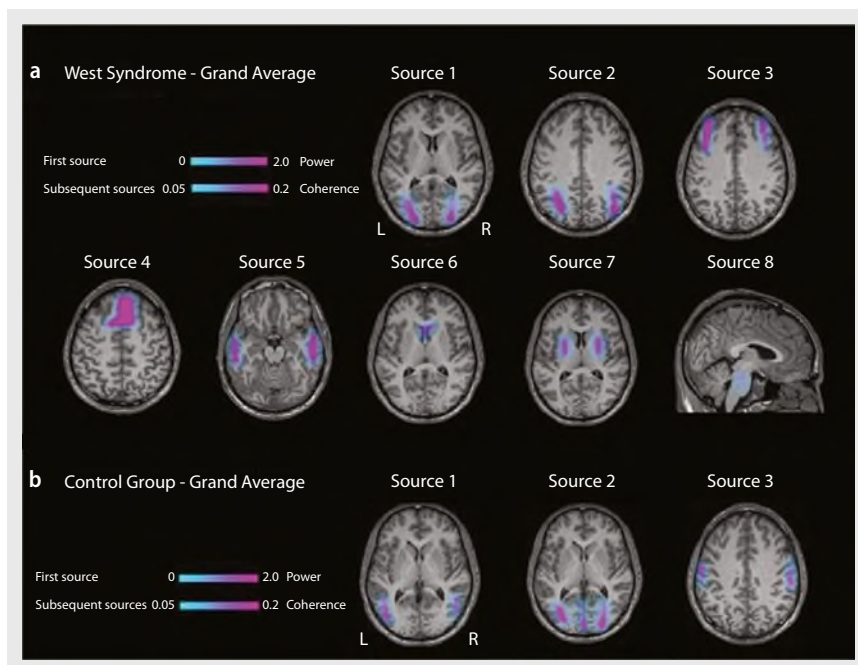
be the reason for a few discordant results of EEG–fMRI and DICS [14]. On the one hand this challenges a one-to-one validation of DICS by EEG–fMRI; on the other hand it might indicate that both methods provide complimentary information about the epileptic network.

Valuable additional information could be derived from the analysis of the interaction between the sources. The signal of the sources was used to analyze the direction of information flow between the different sources by RPDC. In absences RPDC demonstrated an information flow

from the prefrontal sources to the parietal sources on the cortical level. However, all cortical sources were similarly influenced by the thalamic source. In PPR, the flow of information between the cortical sources was dominated by the opposite posterior–anterior direction, from the occipital cortex via the parietal cortex to the frontal cortex. The signal from the thalamic region seems to act as a pacemaker during absences, whereas it seems to be recruited secondarily by occipital cortical activity in the photically induced seizure. For illustration please see **Fig. 2**.

### DICS reveals neuronal networks in west syndrome

The aim of this study [26] was to describe neuronal networks underlying hypsarrhythmia, an EEG pattern characteristic for the West syndrome, using DICS. RPDC was also applied in order to investigate the effective connectivity and direction of informational flow within the detected network. DICS was applied to delta ( $\delta$ ) activity (1–4 Hz) in 8 patients with West syndrome and in 8 patients with drug-resistant partial epilepsies (control group). The brain area with the strongest power in the given frequency range was defined as the reference region. The coherence between this reference region and the entire brain was computed using DICS. The results of electric source imaging were compared to results of a previous EEG–fMRI study [27] which had been performed using the same cohort of patients. The EEG–fMRI results had shown that multifocal epileptiform discharges within the hypsarrhythmia were associated with a complex and diverse pattern of cortical activations, whereas the high-amplitude slow activity in hypsarrhythmia correlated with BOLD signal changes in the putamen and brainstem [27]. Concordant with the EEG–fMRI study DICS showed that  $\delta$  activity in hypsarrhythmia was associated with coherent sources in the occipital cortex (main source) as well as the parietal cortex, putamen, caudate nucleus and brainstem. In patients with partial epilepsies,  $\delta$  activity was attributed to sources only in the cortical regions (occipital, parietal and sensory-motor



**Fig. 3** ▲ DICS grand average analyses for the sources described in both groups. *Color bars* demonstrating the power and the coherence of the first source and subsequent sources respectively. **a** West syndrome patients showing sources in cortical (occipital, parietal and frontal) as well as in subcortical (lenticular nucleus, brainstem) regions. **b** Control group patients showing sources in cortical regions (occipital, parietal and frontal). (Adapted from [26])

cortex; see **Fig. 3**). In West syndrome patients, RPDC showed the strongest and most significant direction of ascending information flow from the brainstem towards the putamen and cerebral cortex. These results are supported by considerable evidence suggesting that the brainstem is the area from which the spasms and the hypsarrhythmic EEG pattern seem to arise [28, 29, 30, 31, 32]. Hrachovy and Frost [33] published a model of infantile spasms suggesting that disruption of certain monoaminergic or cholinergic areas within the region of the pontine reticular formation involved in the control of the sleep cycle could be the primary defect in this disorder.

### Methodological considerations

DICS is a powerful technique of electric source imaging which investigates neuronal interactions by imaging power and coherence estimates of oscillatory brain activity [8]. Studies had shown that DICS can localize sources and describe neuronal networks in cortical as well as in subcortical structures involved during certain rhythmic EEG patterns [8, 9, 10, 11,

12, 13, 14, 26]. It has been a matter of debate whether subcortical sources can be detected in EEG signals recorded from the skull surface. An important concern might be that DICS is locating artificial midline sub-cortical sources due to distributed activity in the cortex. However, a simulation described by Moeller et al. [14] demonstrated that DICS does not locate any artificial sources. A second concern could be that the application of inverse algorithms to 32-channel EEG is unable to correctly locate sources in the deep structures of the brain like the thalamus, cerebellum, and brainstem. However, simulation described by Japaridze et al. [26] indicated that in the cases of high signal to noise ratio and certain dipole orientation deep sources like the brainstem can be identified. In order to validate the source localization the results of EEG-source analysis were compared to results obtained by a second technique with a better spatial resolution also deep in the brain. Therefore DICS was applied to EEGs recorded in EEG-fMRI studies in patients with West syndrome [26] and generalized epileptiform discharges [14]. Thus, it was possible to directly compare

the results of DICS to EEG-fMRI results in the same events and patients. The comparison revealed a high correspondence between the methods applied. However a limitation of the described studies is that a standard head model was used with standard electrode locations. To increase the localization accuracy of the sources, the individual electrode locations can be used in the estimation of the individual lead field matrixes.

### Conclusion

DICS and RPDC methods can give a new perspective and contribute to a better understanding of neurophysiological background of epilepsies. Using scalp EEG recording these methods enable us to locate cortical as well as subcortical sources and describe neuronal networks and effective connectivity within the networks.

Based on the DICS analysis it was possible to describe interrelation and informational flow (effective connectivity) between different sources using the method of the RPDC [21]. In case of absences RPDC analyses showed the informational flow from anterior to posterior regions; whereas in case of PPR posterior to anterior propagation was shown. RPDC in West syndrome patients suggests that brainstem could have a key role in the pathogenesis of West syndrome. This study supports the theory that hypsarrhythmia results from ascending brainstem pathways that project widely from the brainstem to basal ganglia and cerebral cortex [28, 29, 30, 31, 32].

### Corresponding address

**PD Dr. F. Moeller**  
 Clinic for Child Neurology,  
 Department of Neuropediatrics,  
 Christian-Albrechts-University of Kiel  
 Schwanenweg 20, 24105 Kiel  
 Germany  
 f.moeller@pedneuro.uni-kiel.de

**Conflict of interest.** On behalf of all authors, the corresponding author states that there are no conflicts of interest. The Königsteiner AK receives financial reimbursement for travelling and hotel expenses from Desitin for its annual meeting.

## References

1. Groening K et al (2009) Combination of EEG-fMRI and EEG source analysis improves interpretation of spike-associated activation networks in paediatric pharmacoresistant focal epilepsies. *Neuroimage* 46:827–833
2. Vulliemoz S et al (2009) The spatio-temporal mapping of epileptic networks: combination of EEG-fMRI and EEG source imaging. *Neuroimage* 46:834–843
3. Siniatchkin M et al (2010) Neuronal networks in children with continuous spikes and waves during slow sleep. *Brain* 133:2798–2813
4. Michel CM et al (2004) EEG source imaging. *Clin Neurophysiol* 115:2195–2222
5. Holmes MD (2008) Dense array EEG: methodology and new hypothesis on epilepsy syndromes. *Epilepsia* 49:3–14
6. Holmes MD, Quiring J, Tucker DM (2010) Evidence that juvenile myoclonic epilepsy is a disorder of frontotemporal corticothalamic networks. *Neuroimage* 49:80–93
7. Holmes MD, Brown M, Tucker DM (2004) Are “generalized” seizures truly generalized? Evidence of localized mesial frontal and frontopolar discharges in absence. *Epilepsia* 45:1568–1579
8. Gross J et al (2001) Dynamic imaging of coherent sources: studying neural interactions in the human brain. *Proc Natl Acad Sci U S A* 98:694–699
9. Gross J et al (2002) The neural basis of intermittent motor control in humans. *Proc Natl Acad Sci U S A* 99:2299–2302
10. Timmermann L et al (2003) The cerebral oscillatory network of parkinsonian resting tremor. *Brain* 126(Pt 1):199–212
11. Timmermann L et al (2003) Mini-asterix in hepatic encephalopathy induced by pathologic thalamo-motor-cortical coupling. *Neurology* 61:689–692
12. Sudmeyer M et al (2006) Wilson’s disease tremor is associated with magnetic resonance imaging lesions in basal ganglia structures. *Mov Disord* 21:2134–2139
13. Schnitzler A, Timmermann L, Gross J (2006) Physiological and pathological oscillatory networks in the human motor system. *J Physiol Paris* 99:3–7
14. Moeller F et al (2012) Representation and propagation of epileptic activity in absences and generalized photoparoxysmal responses. *Hum Brain Mapp* doi 10.1002/hbm.22026
15. Muthuraman M et al (2012) Source analysis of Beta-synchronisation and cortico-muscular coherence after movement termination based on high resolution electroencephalography. *PloSone* 7(e33928):1–8
16. Muthuraman M, Heute U, Arning K et al (2012) Oscillating central motor networks in pathological tremors and voluntary movements. What makes the difference? *NeuroImage* 60:1331–1339
17. Drongelen W et al (1996) A spatial filtering technique to detect and localize multiple sources in the brain. *Brain Topogr* 9:39–49
18. Muthuraman M et al (2008) Imaging coherent sources of tremor related EEG activity in patients with Parkinson’s disease. *Conf Proc IEEE Eng Med Biol Soc* 2008:4716–4719
19. Fuchs M et al (2002) A standardized boundary element method volume conductor model. *Clin Neurophysiol* 113:702–712
20. Muthuraman M et al (2010) The central oscillatory network of essential tremor. *Conf Proc IEEE Eng Med Biol Soc* 2010:154–157
21. Schelter B, Timmer J, Eichler M (2009) Assessing the strength of directed influences among neural signals using renormalized partial directed coherence. *J Neurosci Methods* 179:121–130
22. Moeller F et al (2008) Simultaneous EEG-fMRI in drug-naive children with newly diagnosed absence epilepsy. *Epilepsia* 49:1510–1519
23. Moeller F et al (2010) Absence seizures: individual patterns revealed by EEG-fMRI. *Epilepsia* 51:2000–2010
24. Moeller F et al (2009) fMRI activation during spike and wave discharges evoked by photic stimulation. *Neuroimage* 48:682–695
25. Moeller F et al (2009) Mapping brain activity on the verge of a photically induced generalized tonic-clonic seizure. *Epilepsia* 50:1632–1637
26. Japaridze N et al (2012) Neuronal networks in west syndrome as revealed by source analysis and renormalized partial directed coherence. *Brain Topogr* (in press)
27. Siniatchkin M et al (2007) Different neuronal networks are associated with spikes and slow activity in hypsarrhythmia. *Epilepsia* 48:2312–2321
28. Chugani HT et al (1992) Infantile spasms: II. Lenticular nuclei and brain stem activation on positron emission tomography. *Ann Neurol* 31:212–219
29. Hrachovy RA, Frost JD Jr, Kellaway P (1981) Sleep characteristics in infantile spasms. *Neurology* 31:688–693
30. Morimatsu Y et al (1972) Pathology in severe physical and mental disabilities in children—with special reference to 4 cases of nodding spasm. *Shinkei Kenkyu No Shimpo* 16:465–470
31. Neville BG (1972) The origin of infantile spasms: evidence from a case of hydranencephaly. *Dev Med Child Neurol* 14(5):644–647
32. Satoh J, Mizutani T, Morimatsu Y (1986) Neuropathology of the brainstem in age-dependent epileptic encephalopathy—especially of cases with infantile spasms. *Brain Dev* 8:443–449
33. Hrachovy RA, Frost JD Jr (1989) Infantile spasms. *Pediatr Clin North Am* 36:311–329