

Locoregional therapy: from mastectomy to reconstruction, targeted surgery, and ultra-hypofractionated radiotherapy

Maggie Banys-Paluchowski, Steffi Hartmann, Nina Ditsch, Natalia Krawczyk, Thorsten Kühn, Jana de Boniface, Joanna Banys-Kotomska, Achim Rody, David Krug

Angaben zur Veröffentlichung / Publication details:

Banys-Paluchowski, Maggie, Steffi Hartmann, Nina Ditsch, Natalia Krawczyk, Thorsten Kühn, Jana de Boniface, Joanna Banys-Kotomska, Achim Rody, and David Krug. 2023. "Locoregional therapy: from mastectomy to reconstruction, targeted surgery, and ultra-hypofractionated radiotherapy." *Breast Care* 18 (6): 428–39. <https://doi.org/10.1159/000533748>.

Locoregional Therapy: From Mastectomy to Reconstruction, Targeted Surgery, and Ultra-Hypofractionated Radiotherapy

Maggie Banys-Paluchowski^a Steffi Hartmann^b Nina Ditsch^c
Natalia Krawczyk^d Thorsten Kühn^e Jana de Boniface^{f,9}
Joanna Banys-Kotomska^h Achim Rody^a David Krugⁱ

^aDepartment of Gynecology and Obstetrics, University Hospital Schleswig-Holstein, Campus Lubeck, Lubeck, Germany; ^bDepartment of Gynecology and Obstetrics, University Hospital Rostock, Rostock, Germany; ^cBreast Cancer Center, Department of Gynaecology and Obstetrics, University Hospital Augsburg, Augsburg, Germany; ^dDepartment of Gynecology and Obstetrics, Heinrich-Heine-University Düsseldorf, Dusseldorf, Germany; ^eDepartment of Gynecology and Obstetrics, Die Filderklinik, Filderstadt, Germany; ^fDepartment of Molecular Medicine and Surgery, Karolinska Institutet, Stockholm, Sweden; ^gDepartment of Surgery, Capio St. Görän's Hospital, Stockholm, Sweden; ^hI Department and Clinic of Gynaecology and Obstetrics, Wrocław Medical University, Wrocław, Poland; ⁱDepartment of Radiation Oncology, University Hospital Schleswig-Holstein, Campus Kiel, Kiel, Germany

Introduction

Often, looking back toward where we came from gives us a clearer picture of what is to come. In the current era of overwhelming change in locoregional management of breast cancer – which is enabled, paralleled, and probably overshadowed by an unprecedented progress in the development of systemic therapies – one does not need to look far back in time to understand how much has changed up until now, and to get a glimpse of where we might be heading.

It is 85 years ago since Halsted's radical mastectomy was challenged by Patey and Dyson's less mutilating modified radical mastectomy, the latter of which is still used today. About 20 years later, Bernard Fisher formulated the hypothesis of breast cancer being a systemic disease, giving fuel to the NSABP B-04 trial initiated in 1971 and showing the oncological equivalence of radical mastectomy and total mastectomy. At the same time, national mammography screening programs initiated a significant stage shift and systemic therapy was rapidly improving, raising questions about the necessity and appropriateness of extensive and morbidity-fraught locoregional treatments.

One of the big game changers arrived in 1977, when the sentinel lymph node biopsy (SLNB) was first described. Even though it would take several decades to validate and implement it in clinical reality, it is still today one of the most important surgical tools we have. The last decades have seen a refinement of its use, ramifications of its indications in more detail than ever seen before, the addition of modern techniques such as the targeted lymph node biopsy, and even the first trials omitting it, and thus all axillary staging, entirely. At the same time, also the extent of breast surgery has been modified and individualized, and again, technical refinement has led to improved cosmetic results, a larger variety of reconstructive options both after mastectomy and after breast-conserving surgery, and reduced postoperative morbidity and recovery time. Radiotherapy has joined the development toward "less is more," allowing more precise, versatile, and shorter treatments with less impact on patients' return to their daily life. This narrative overview wishes to offer insights into specific areas of treatment optimization, individualization, and modernization, significantly increasing both the complexity and the abundance of choice in locoregional management, and possibly pointing toward future developments in breast cancer care.

Surgical Therapy of the Breast

Breast-conserving therapy is the standard procedure for removing the primary tumor from the breast and ensuring local control. Nowadays, it is used in 70–80% of all breast cancer patients [1–3]. This is because this procedure offers the same oncological safety as mastectomy procedures in terms of overall survival (OS) and breast cancer-specific survival [4]. The ACOSOG Z11102 study was presented at SABCs 2022 and showed no increased local recurrence rate even for multifocal/multicentric tumors (≥ 2 cm distance) that extended within a maximum of two quadrants [5]. If breast-conserving surgery (BCS) is performed and the tumor is not palpable, intraoperative tumor localization must be supported by image guidance as reported later. Complete removal of the tumor should be ensured by specimen

ultrasonography or radiography (optimally, by the same method chosen for preoperative marking). Regarding margins, it has been shown that achieving "no ink on tumor" is sufficient [6]. In the case of DCIS without any invasive component, a 2-mm resection margin is recommended.

In the case of large tumor volumes, plastic surgical techniques are necessary for tumor removal, which require oncoplastic know-how and a special training of the breast surgeon. This serves to achieve safe resection margins while maintaining an esthetic breast shape. Intra-mammary glandular displacement flaps as well as tumor-adapted reduction mammoplasties can be used [7]. To achieve a cosmetically favorable result, the focus should be on favorable scar placement and adequate soft tissue formation. If necessary, surgery of the opposite side may also be required to achieve a symmetrical result. In any case, the patient should be informed about this before any surgical intervention.

Performing a mastectomy remains indicated in individual cases of unfavorable tumor-to-breast size ratio, skin involvement, contraindications regarding radiotherapy, or positive resection margins despite repeated re-excision. If a patient wishes or the situation requires a mastectomy, it can be performed in a modified radical way with skin or nipple areola preservation, depending on the location of the tumor. If reconstruction is desired, implant-supported reconstruction or reconstruction with autologous tissue transfer is possible. In this case, reconstruction can be performed either as immediate reconstruction or as a two-stage procedure.

If implant-supported reconstruction is chosen, subpectoral insertion was usually performed until a few years ago. However, the prepectoral position is now mostly used. A recently published review and meta-analysis [8] showed an advantage for the prepectoral approach with regard to clinical complications (significantly lower rates of capsular contracture, animation deformity, and prosthesis failure) but the data of a prospective study of the OPBC group as well as from the I-PREPARE study of the EUBREAST network must be awaited to be able to give clear recommendations in the future. Using implants in combination with synthetic meshes/mesh pockets or acellular dermal matrices, a sustainable stable result can usually be achieved. Subsequent remodeling by means of lipofilling is also usually unproblematic.

Targeted Surgery

Surgical excision of non-palpable tumors requires some form of imaging-guided localization. The oldest and most commonly used technique is currently the wire-guided localization (WGL), initially developed in the 1960s and popularized in the 1970s and 1980s [9, 10],

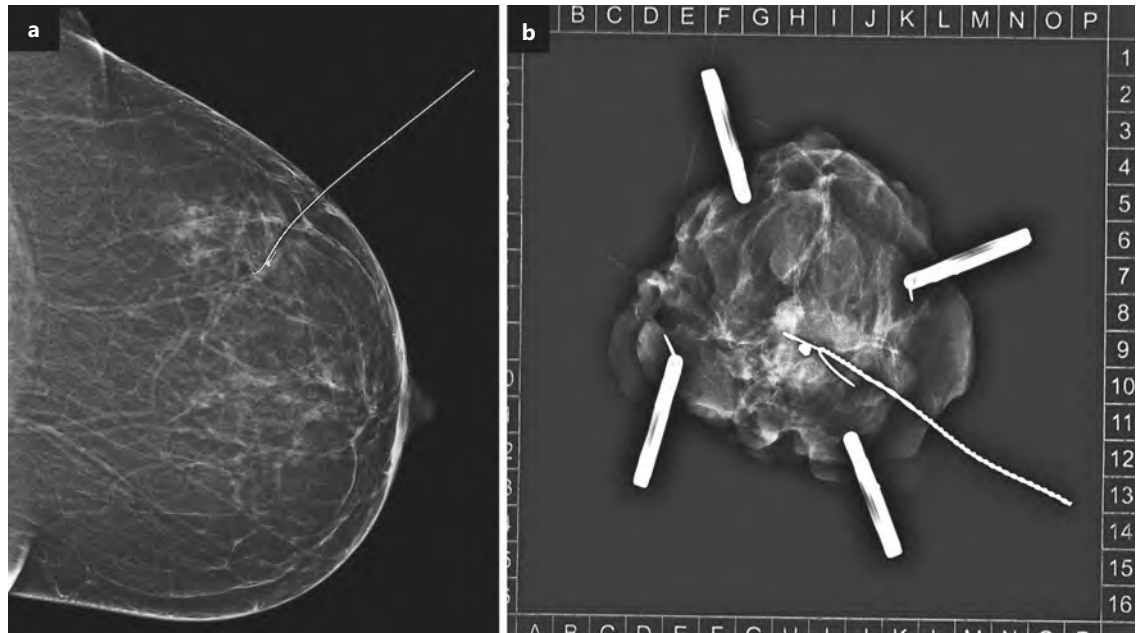


Fig. 1. WGL. **a** Mammography showing wire tip touching the clip. **b** Specimen radiography confirming the removal of the clipped area.

WGL involves a wire or a needle placed preoperatively into the lesion under sonographic, mammographic, or MRI guidance, usually followed by radiography or ultrasound of the surgically removed specimen (Fig. 1) [11]. Potential disadvantages of this technique are the logistical challenges, mainly the necessity to perform the procedure on the day of surgery or – less frequently – on the day before, risk of wire dislocation, patient distress due to invasiveness, and relatively low negative margin rates in previous studies [12]. Despite widespread use of wire localization, a majority of breast surgeons have voiced a preference to switch to an alternative localization method [10]. Therefore, new techniques such as intraoperative ultrasound (IOUS) and probe-guided detection have been developed to overcome these disadvantages.

IOUS was first introduced as an alternative to WGL in the 1980s [13]. Since then, the technique has been investigated in several trials and adopted by many surgeons worldwide [12]. No preoperative localization procedure is necessary using IOUS, since the imaging is performed during surgery by the surgeon or – in a small minority of departments – by a radiologist present in the operating room (Fig. 2). Meta-analyses of randomized controlled trials demonstrated significantly higher negative margin rates in case of IOUS compared to WGL [14–16]. Before implementing IOUS, the following requirements need to be considered: the surgeon must have experience in breast ultrasound and an adequate ultrasound machine must be available in the operating room. The use of this technique is limited to lesions unequivocally visible upon ultrasound.

The probe-guided detection techniques involve the placement of a marker that can be intraoperatively detected using a specific probe. Several detection systems are available, that are based either on radioactivity (radioactive seeds and radioactive occult lesion localization), magnetism (magnetic and paramagnetic markers), radar localization, or radiofrequency (Fig. 3) [12, 17]. These techniques are suitable for lesions visible upon ultrasound or mammography and offer an improved flow toward surgery due to the omission of a preoperative procedure on the day of surgery. The markers can be placed into the lesion several days, weeks, or even months before planned removal, thus enabling their use in the neoadjuvant setting as an alternative to traditional clips. However, the possibility of MRI artifacts, especially in case of (para) magnetic and radiofrequency markers, may hinder response assessment during neoadjuvant therapy. First, analyses suggest an improved patient satisfaction and less preoperative pain, compared with wire guidance [18, 19], but large multicohort studies on patient, surgeon, and radiologist preferences are pending [12]. Further, the higher cost of new probe-guided detection markers, compared to a wire, needs to be taken into account. Currently, the costs of a marker reach between 200 and 400 euro.

Radiotherapy of the Breast

Adjuvant whole breast irradiation (WBI) has been established as standard of care following results of randomized controlled trials demonstrating a significant reduction of local recurrences compared to lumpectomy alone. This indication was further substantiated by the

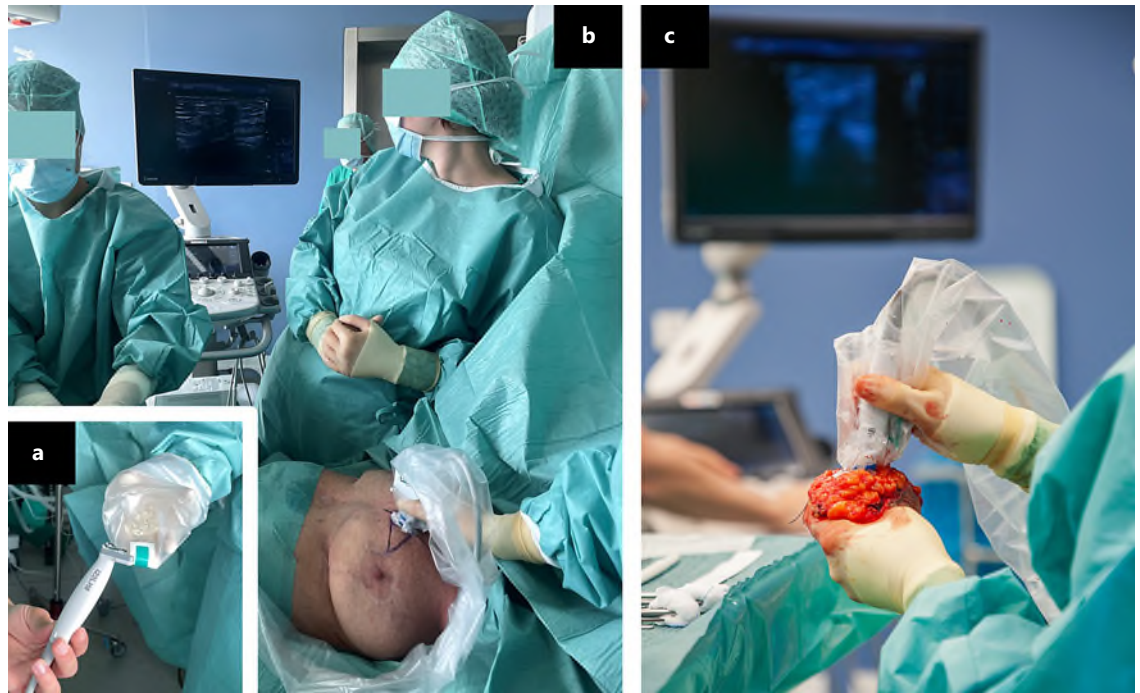


Fig. 2. IOUS. **a** Ultrasound probe is covered in a sterile sheath. **b** The lesion is visualized by the surgeon and the incision is planned. Afterward, the lesion is visualized intermittently during specimen removal. **c** Specimen ultrasound is performed directly after excision to evaluate margins.

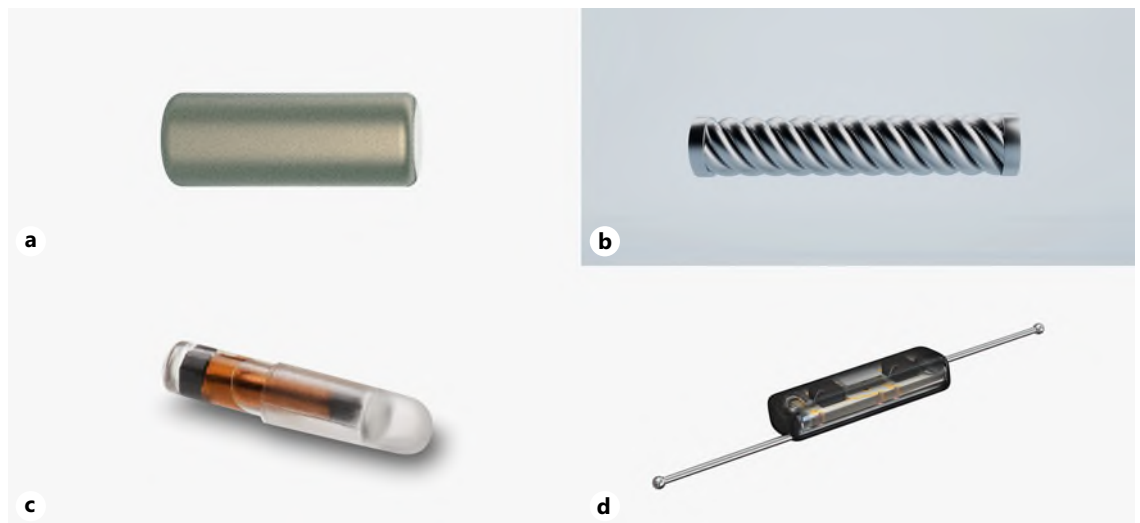


Fig. 3. Examples of markers suitable for intraoperative detection using a probe guidance. **a** Magnetic marker Sirius Pintuition (5 × 1.65 mm). **b** Paramagnetic marker Magseed (5 × 1 mm). **c** Radiofrequency identification tag Localizer (11 × 2 mm). **d** Radar reflector SAVI SCOUT (12 × 1.6 mm).

EBCTCG meta-analysis which established an additional reduction in breast cancer related and overall mortality [20].

Traditionally, radiotherapy was delivered with a dose per fraction of 1.8–2 Gy (conventional fractionation). This assumes that tumor cells possess a higher sensitivity to radiation than normal tissue. Thus, small doses per

fraction were chosen to spare normal tissue and take advantage of interfractional recovery of DNA-damage.

While high radiation sensitivity is indeed true for highly proliferative tumors such as small-cell lung cancer or squamous cell carcinoma, breast cancer exhibits a radiation sensitivity that is very similar to surrounding normal tissues with low proliferation [21]. This offers a

Table 1. Key characteristics of the FAST and FAST forward trials

	FAST	FAST forward
Sample size	915	4,096
Enrollment	2004–2007	2011–2014
Median follow-up	10 years	6 years
Dose/fractionation	25 × 2 Gy versus 5 × 6 Gy versus 5 × 5.7 Gy	15 × 2.67 Gy versus 5 × 5.4 Gy versus 5 × 5.2 Gy
Treatment duration	5 weeks	3 weeks versus 1 week
Primary endpoint	Photographic breast appearance	Ipsilateral breast tumor recurrence
Eligibility criteria	T <3 cm pN0 Age ≥50 years BCS No chemotherapy	pT1-3 pN0-1 Age ≥18 years BCS or mastectomy
Boost irradiation	None	Sequential, 5–8 × 2 Gy (25% of patients)

strong radiobiological rationale for the use of higher doses per fraction with a reduced number of treatment sessions (hypofractionation). From a socioeconomic perspective, an additional advantage is increased patient throughput. Some trials have used hypofractionation but kept the overall treatment duration constant. For example, the FAST-trial used 5 fractions over the course of 5 weeks. On the contrary, the FAST forward trial (5 fractions over 1 week) used a reduced treatment duration (acceleration).

Moderate hypofractionation with a total dose of 40–42.5 Gy in 15–16 fractions over 3 weeks is considered standard of care for WBI as well as most other clinical scenarios [21, 22]. A Cochrane review of 9 trials with 8,228 patients demonstrated comparable oncological results in terms of local tumor control and survival as well as comparable late toxicity and cosmesis [23]. Nevertheless, the uptake of moderate hypofractionation has been slow. Many radiation oncologists were hesitant to give up conventional fractionation that had been in use for decades. Several large cohort studies have now closed evidence gaps for subgroups that were not well represented in clinical trials, e.g., patients with triple-negative or HER2-positive tumors, very young patients, patients with large breasts or autoimmune diseases [24–27]. Recently, two large randomized controlled trials that integrated boost irradiation into moderate hypofractionation over the course of 3 weeks (simultaneous integrated boost of 48 Gy to the tumor bed and 40 Gy to the breast in 15 fractions) were presented at international conferences and demonstrated non-inferiority to sequential boost irradiation [27, 28]. Despite these advances, reimbursement policies tied to the number of treatment sessions still incentivize the use of conventional fractionation. This is a matter that needs to be addressed by professional societies and health care agencies to decrease barriers to the use of hypofractionation.

In 2020, results of two large randomized controlled trials delivering ultra-hypofractionated WBI in 5 fractions over the course of 5 weeks (FAST-trial) or

1 week (FAST forward trial) have been published [29]. Key characteristics of the two trials are listed in Table 1 [30].

Both trials found comparable local recurrence rates, however only FAST Forward was powered to demonstrate non-inferiority. In both trials, two ultra-hypofractionated regimens were studied and compared to the standard arm. The experimental arms with the higher dose ultra-hypofractionated regimen were associated with significantly higher rates of late toxicity, although the difference in the prescription doses was only 1–1.5 Gy. In the lower dose ultra-hypofractionated regimens, subdomains also showed increased late toxicity. Practically, all hazard ratios for late toxicity subdomains favored the respective standard arms, although absolute differences were small. While ultra-hypofractionation was adopted as the new standard of care for WBI in the UK and can be offered according to a European consensus, others have raised concerns regarding the small therapeutic window [31]. Nevertheless, ultra-hypofractionation offers a valuable option for selected patients [22, 32].

After BCS, most recurrences occur in the tumor bed. For women with early-stage low-risk breast cancer (unifocal non-lobular carcinoma, T <3 cm, pN0, hormone receptor positive, HER2 negative, grade 1–2, wide negative margins, age ≥50 years) targeting the lumpectomy cavity with an additional safety margin instead of the whole breast using partial breast irradiation (PBI) is a valuable option [31, 33]. A variety of techniques have been studied. The most commonly used techniques are external beam radiotherapy and multicatheter brachytherapy since non-inferiority regarding local recurrence and better tolerability compared to WBI have been demonstrated in several randomized controlled trials. Although intraoperative radiotherapy is certainly most attractive in terms of convenience and treatment duration, its use is only conditionally recommended in most guidelines [33]. Heated discussions

have resulted from concerns over study design and outcome reporting for intraoperative radiotherapy with low energy photons [34].

While PBI represents a de-escalation approach, the application of a tumor bed boost may be used to escalate treatment in patients at higher risk of local recurrence. When added to whole breast radiotherapy, boost irradiation decreases the relative risk of local recurrence by 36% without improving survival [35]. The absolute benefit is highest in women aged <50 years and those with poorly differentiated tumors while women aged >50 years with luminal A-like tumors do not derive a benefit and suffer from a significantly higher risk of breast fibrosis [36, 37]. Traditionally, boost irradiation was performed after completion of whole breast radiotherapy. However, there is now sufficient evidence for a simultaneous integrated boost that incorporates the boost dose into whole breast radiotherapy and does not lead to a prolongation of the overall treatment time [38, 39].

Surgical Therapy of the Axilla

Axillary lymph node status is considered the strongest classical prognostic factor of early breast cancer [40]. Since cures were observed for solid tumors in the late 19th century after radical removal of the tumor and regional lymph nodes, systematic axillary lymph node dissection (ALND) was also established as a therapeutic standard for breast cancer [41]. At least 10 axillary lymph nodes from level 1 and level 2 should be removed as part of primary surgical therapy [42]. However, the radicality of axillary intervention has been gradually reduced over the past 20 years without a loss of oncologic safety while reducing arm morbidity.

Axillary Surgery in cN0 Patients

At the beginning of the 21st century, axillary SLNB became the standard of care in clinically node negative patients (cN0) [43]. Arm morbidity is significantly lower after SLNB than after ALND (lymphedema 7–9% vs. 10–20%; neuropathy 11% vs. 31%) [42]. Randomized clinical trials have shown that although the false-negative rate (FNR) for SLNB is 5–8%, this has no impact on disease-free and OS [44]. The second milestone in the de-escalation of axillary surgery in cN0 patients was the implementation of the results of the ACOSOG-Z0011 trial in clinical practice, first published in 2010 [45, 46]. The study showed no benefit from completion ALND (cALND) for patients with T1/2 tumor and 1 or 2 metastatic axillary sentinel lymph nodes (SLNs) who underwent BCS and adjuvant WBI. Since the long-term data on 10-year OS, metastasis-free survival, and axillary recurrence rate published in 2017 also confirmed this [47], it is possible to forgo ALND in patients who meet the inclusion criteria of the ACOSOG-Z0011 trial. Recently published results from the Italian SINODAR ONE

trial suggest that omitting ALND in patients receiving a mastectomy is oncologically safe [48]. However, the reported median follow up of 33 months remains relatively short, so it remains open at present whether this approach should be applied to mastectomy cases. POSNOC (NCT02401685) and SENOMAC (NCT02240472) may be able to answer this question, as they are also recruiting patients undergoing mastectomy. Currently, the only data available for the mastectomy cohort are from the AMAROS and OTOASOR trials. In both trials (17% with mastectomy in each study), axillary radiotherapy was equivalent to cALND for positive SLNB, with a significantly lower rate of lymphedema in the radiotherapy arm [49, 50]. On the other hand, patients treated with axillary radiotherapy showed a higher incidence of secondary cancers in the 10-year follow up of the AMAROS study [51].

SLNB is also the standard of care for all patients undergoing neoadjuvant chemotherapy (NACT) with initial cN0 status. It should be performed after NACT as part of breast surgery [6, 52]. Compared to performing SLNB before NACT, the advantages of this are that additional surgery is avoided, a statement regarding the achievement of pathologic complete remission becomes possible, systemic therapy is not delayed by surgery, and nodal downstaging (ypN+ 41% vs. 12%) is achieved without increasing the axillary recurrence rate or the distant metastasis risk [53]. It should be noted, however, that in contrast to patients undergoing primary surgery, cALND is recommended even in cases of low tumor burden in the axillary SLN after NACT [54, 55]. The rationale for this recommendation is that not only in the case of macro- but also in the case of micrometastases in the SLN after NACT, further axillary lymph node metastases are detectable in more than 60% of cases [55, 56].

Outside of clinical trials, we can omit surgical axillary staging (i.e., also SLNB) in older patients (≥ 70 years) with hormone receptor-positive, HER2-negative T1cN0 tumors [57], especially if comorbidities are present [6]. Whether this is also possible for other patient groups in the future is currently being evaluated in clinical trials like SOUND (NCT02167490), INSEMA (NCT02466737), NAUTILUS (NCT04303715), and BOOG 2013-08 (NCT02271828). Primary outcome data from the SOUND trial were presented at the St Gallen International Breast Cancer Conference in 2023 and the full publication is expected soon. The evaluation of the oncological endpoints of other trials is still pending. Already published data were the patient-reported outcomes of the INSEMA trial, which showed a significant benefit in terms of arm and breast symptoms for patients without axillary surgery compared to patients with SLNB, supporting the clinical relevance of further de-escalation in axillary surgery [58]. Also, for initial cN0 patients receiving NACT, the EUBREAST-01 trial (NCT04101851),

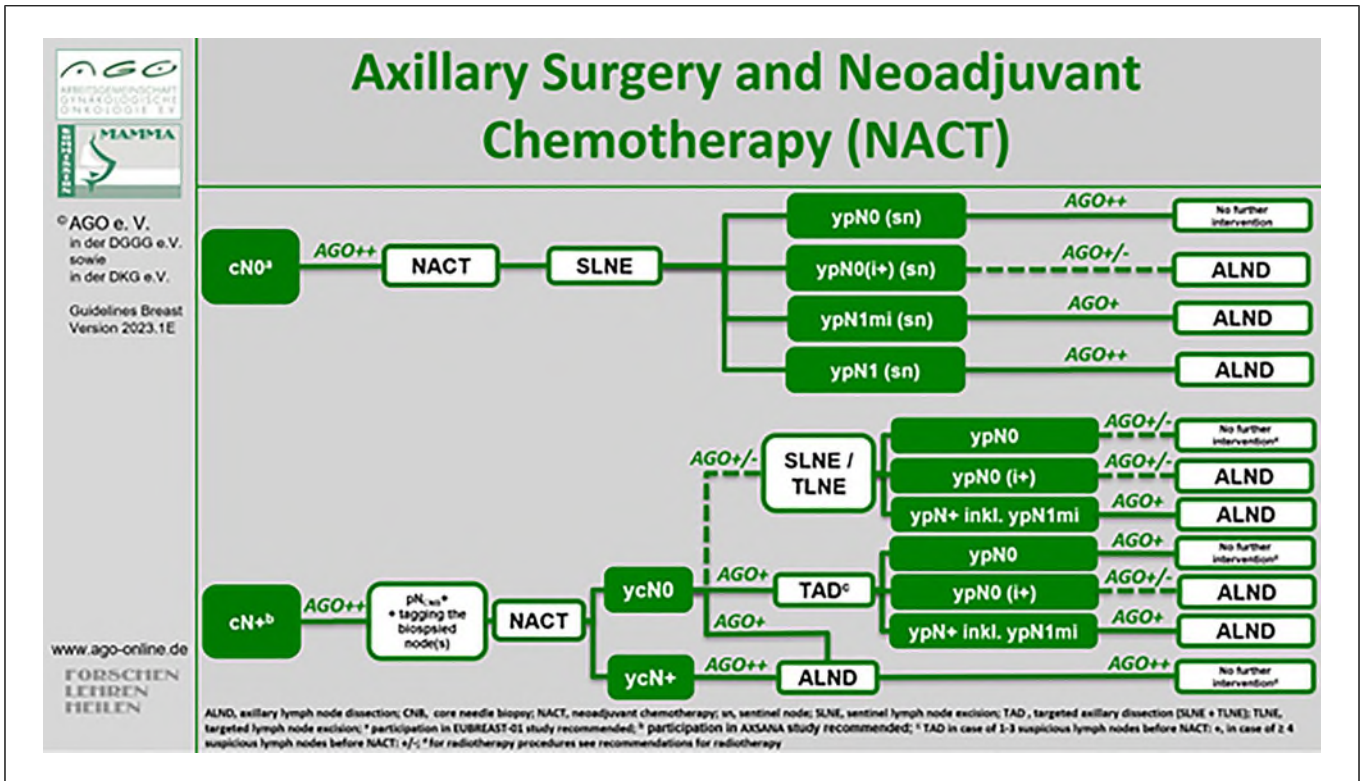


Fig. 4. Current recommendations of the AGO Breast Committee regarding axillary staging in the neoadjuvant setting [59].

the ASLAN trial (NCT04993625), and the ASICS trial (NCT04225858) are currently evaluating whether SLNB can be omitted, at least in triple-negative or HER2-positive breast cancer with cN0 and pCR in the breast.

Axillary Surgery in cN + Patients

For patients with clinically suspicious axillary lymph nodes at diagnosis (cN+) who did not receive a neoadjuvant therapy ALND is currently considered standard of care [59]. The results of National Surgical Adjuvant Breast Project (NSABP) B-04 trial, first published in 1977, have shown that ALND in these patients significantly reduces axillary recurrence rate (7% in patients after mastectomy and axillary irradiation vs. 1% in patients after mastectomy and ALND). However, it is worth mentioning that ALND had no influence on the rate of distant metastasis or OS [60]. The cN + status was defined as palpable suspicious lymph nodes in this study and patients with negative clinical examination and lymph node metastases detected on ultrasound were not included [61].

In contrast to patients undergoing primary surgery, optimal surgical management of cN + patients receiving NACT remains to be clarified. Since there is no survival benefit of ALND in the upfront surgery setting and the procedure leads to increased morbidity compared to SLNB, several studies have raised the question whether

ALND can be replaced by SNLB at least in those cN + patients who convert to ycN0 status through NACT [62–65]. However, a recent meta-analysis showed a relatively low detection rate of 89% and high FNR of 17% for SNLB in this clinical setting [66]. Therefore, SLNB alone seems not to be an adequate lymph node staging method in this patient group and is not recommended by German guidelines (Fig. 4) [54, 59]. Despite high FNRs, SLNB is a frequently chosen technique in the cN+ → ycN0 setting in some countries, such as Italy and the USA [67], while others prefer the so-called “targeted axillary dissection” (TAD), a term coined by Caudle et al. [68]. TAD is a combination of SNLB, and the excision of the biopsy-proven and marked metastatic lymph node referred to as “target lymph node” (TLN) (Fig. 5). Identification and removal of TLN decreased the FNR of SNLB in the ACOSOG Z1071 trial from 12.6% to 6.8%. Several trials since analyzed the FNR of TAD in initially node-positive patients undergoing NACT demonstrating acceptable FNR between 2 and 9% (Table 2). Interestingly, the TLN and SLN are the same node in approximately 70% of patients [61]. In the remaining 30% of cases, the marking of the initially metastatic lymph node allows its identification and resection after completion of NACT. One of the open questions remains the optimal marking technique, since not all clips are sufficiently visible upon imaging [69–76].

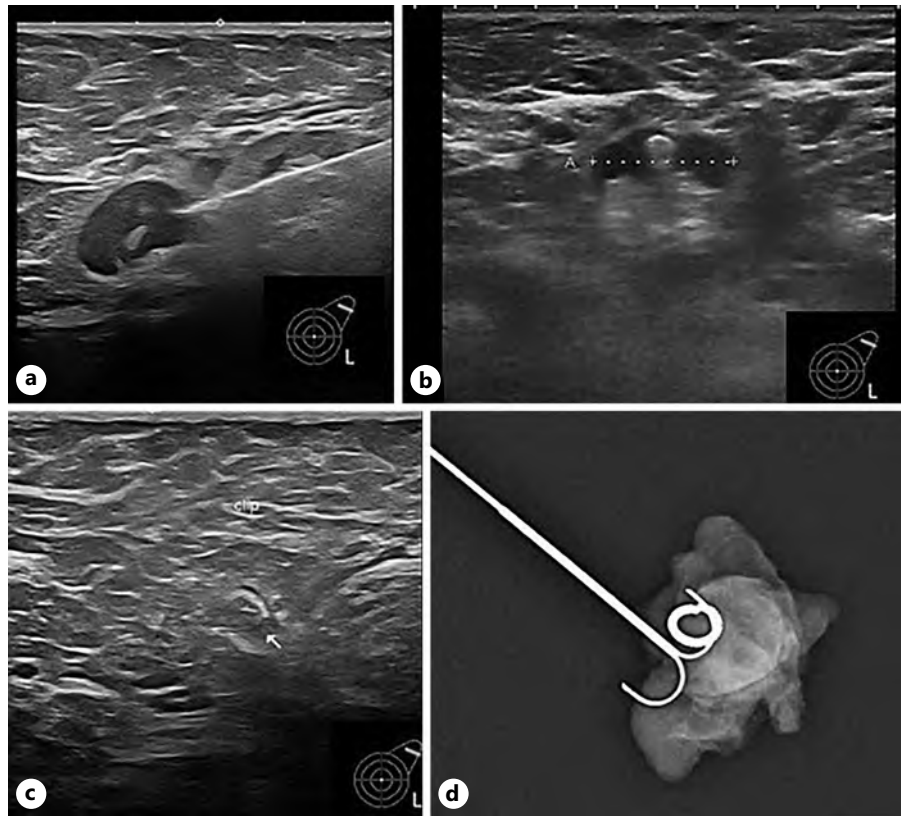


Fig. 5. Targeted axillary dissection (TAD). **a** Biopsy of metastatic axillary lymph node. **b** Marking of the metastatic lymph node with a clip. **c** Identification of the initially metastatic lymph node (target lymph node, TLN) with unsuspecting sonomorphology after completion of neoadjuvant chemotherapy. **d** Resection of the sentinel lymph node and TLN. Confirmation of the TLN resection at surgery by intraoperative radiography of the axillary specimen.

Table 2. Clinical trials evaluating the accuracy of TAD for axillary staging in patients with initially metastatic axillary lymph nodes undergoing NACT

Trial	N	Tumor stage	Marking/localization method TLN	FNR, %
Boughey et al. [64] Ann Surg 2016 (ACOSOG Z1071)	107	T0–T4, N1–N2	Clip	6.8
Caudle et al. [68] JCO 2016	85	T0–T4, N1–N2	Clip/iodine seed	2
Siso et al. [69] Ann Surg Oncol 2018 (ILINA)	35	T1–T4, N1–N2	Clip/IOUS	4.1
Simons et al. [69] (RISAS)	227	T1–T4, N1–N2	Iodine seed	3.5
Hartmann et al. [70] BJS 2021 (TATTOO)	110	Stadium I–IV, N1–N3	Carbon	9
Boniface et al. [71] Breast Cancer Res Treat. 2022 (extended TATTOO)	149	T1–T4, N1–N3	Carbon	6.2
Renaudeau et al. [72] SABCs 22-OT1 09-01 (GANEAS)	260	T1–T4c, N1–N3	Clip	6
Kuemmel et al. [73] Ann Surg 2022 (SENTA)	77	T1–T4c, N+	Clip	4.3

Based on these data, most guidelines agree that TAD can accurately stage the axilla in cN+ patients converting to ycN0 status through NACT and that cALND can be omitted in those with nodal pCR (ypN0) confirmed by TAD [77]. However, in case of residual tumor burden in SLN and/or TLN after NACT cALND is still recommended [52, 59].

Despite growing evidence on new surgical techniques in cN+ patients after NACT, the impact of surgical de-escalation on oncological outcomes and health-related quality of life is still unclear [62, 77]. In this context it is worth noting that several recently published retrospective trials reported low (0–1.6%) axillary recurrence rates after

SLNB alone in cN+ → ycN0 patients, suggesting that high FNRs of SLNB do not necessarily translate into worse clinical outcome [78]. Axillary staging techniques in cN+ patients after NACT and their impact on oncological outcome and arm morbidity are being currently evaluated in the prospective multicentre AXSANA study with an estimated enrollment of 4,500 patients (NCT04373655) [77].

Radiotherapy of the Axilla

Like adjuvant WBI after BCS, postoperative radiotherapy to the axilla (ART) can sterilize subclinical residual disease. When discussing ART, this typically

refers to coverage of level 1/2 while the term “regional nodal irradiation” mostly addresses irradiation of the supraclavicular fossa and the internal mammary nodes. With standard tangential irradiation of the breast, there is always incidental exposure of axillary levels 1 and 2. In a central review of the German INSEMA trial, median doses to levels 1 and 2 were 72% and 38% of the prescription dose to the breast, respectively [79]. When the upper field border is less than 2 cm below the humeral head (so-called high tangent), therapeutic doses are delivered to large amounts of level 1 and 2 [80].

De-escalation of axillary surgery and the increasing adoption of axillary surgery as a staging procedure rather than a therapeutic measure have changed the use of ART. In fact, in patients with subclinical involvement of SLN after primary surgery, the AMAROS and OTOASOR trials have shown that ART can serve as a substitute for ALND and provides similar axillary recurrence rates with a substantial decrease in the risk of lymphedema [50]. In these trials, radiotherapy was delivered to axillary level 1–3 and the supraclavicular region. Results of the ACOSOG Z0011 trial suggest that some patients in this clinical scenario may need neither ALND nor ART. Per trial protocol, all patients were planned to receive tangential WBI. However, a retrospective analysis found that approximately 20% received supraclavicular irradiation and >50% high tangents [81]. Thus, it remains unclear whether ART at least in part compensated for deescalated axillary surgery. Both the AGO and the ASCO-guidelines currently recommend ART instead of ALND for patients with subclinical SLN-involvement meeting the ACOSOG Z0011-criteria [6, 57].

Regarding radiotherapy of the axilla after NACT and surgery, there is only very limited data to guide clinical management. Thus, most of the recommendations are based on extrapolation from the above-mentioned clinical trials. Currently, the most comprehensive data come from the RAPCHEM-trial [82]. In this prospective trial, patients with cT1-2 cN1 breast cancer were stratified according to the response to NACT into three risk groups with tailored radiotherapy fields. Patients with ypN0 and ypN1(ALND) received only tangential radiotherapy. Patients with ypN1(SLNB) and ypN2-3(ALND) were treated with irradiation of level 3 and the supraclavicular fossa. Level 1/2 was included in the radiotherapy fields for patients with SLNB. Isolated locoregional recurrence rates were low at 2.1%, 2.2%, and 2.3% after 5 years for the three risk groups. However, the overall compliance with the radiotherapy guidelines was only 64% with 25% of patients receiving more extensive radiotherapy.

The two most frequent clinical questions are how to manage the axilla in patients with cN+/ypN0 after SLNB/TAD and whether ART may be a safe alternative to

ALND in patients with cN+/ycN0 with limited SLN-involvement. Regarding the first question, pre-treatment stage and the type of axillary surgery as well as the respective FNRs should be taken into account. Especially if a patient had bulky axillary lymph nodes and/or had SLNB with only one or two removed SLN, irradiation of level 1/2 should be considered. The ongoing NSABP B-51/RTOG 1304 trial that studies the role of regional nodal irradiation in patients with cN+/ypN0 recommends inclusion of the undissected part of the axilla in the radiotherapy treatment volume.

Regarding the second question, most experts agree that the results of AMAROS and OTOASOR should not be extrapolated to the neoadjuvant setting since residual tumor post-NACT may be less sensitive to radiotherapy. Nevertheless, a recent EUBREAST survey demonstrated that more than 30% of participants use ART alone in patients with SLN-involvement after NACT irrespective of the presence of isolated tumor cells, micro-, or macrometastases [67]. The ALLIANCE A011202 is comparing ALND to axillary radiotherapy in patients with SLN-involvement after NACT. The TAXIS-trial enrolls patients with ycN + -status and randomizes them to ALND versus targeted axillary surgery, which combines SLNB with removal of all clinically suspicious lymph nodes.

Conclusions

Both surgery and radiotherapy for breast cancer have undergone a substantial evolution during the past decades. De-escalation approaches like SLNB and PBI offer the chance to reduce morbidity for a substantial number of patients without compromising oncological outcomes. Technological advances have been made but it remains crucial to establish their added value in terms of improved outcomes and ultimately, survival or quality of life. Future efforts should involve multidisciplinary expert panels to design clinical trials in a meaningful way that further improves patient care.

Conflict of Interest Statement

M.B.P. received honoraria for lectures and participation in advisory boards from: Roche, Novartis, Pfizer, PFM, Eli Lilly, Onkowissen, Seagen, AstraZeneca, Eisai, Amgen, Samsung, Canon, MSD, GSK, Daiichi Sankyo, Gilead, Sirius Pintuition, Pierre Fabre, ExactSciences. Study support from EndoMag, Mammotome, Merit Medical, Gilead, Hologic, ExactSciences, Sirius Pintuition; and travel reimbursement from Eli Lilly, ExactSciences, Pierre Fabre, Pfizer, Daiichi Sankyo, Roche. D.K. received honoraria from Merck Sharp & Dohme, Onkowissen, and Pfizer and research funding from Merck KGaA. T.K. received honoraria from MSD, Pfizer, Gilead, AstraZeneca, Daiichi Sankyo, Roche, Merit Medical, Endomagnetics, Sirius

Medical, Hologic. N.D. received honoraria from AstraZeneca, Daiichi Sankyo, Lilly, Molecular Health, MSD, Novartis, Onkowsen, Pfizer, Roche, Seagen. Other authors declare no conflicts of interest.

Funding Sources

There was no funding for this article.

References

- Rutherford CL, Barker S, Romics L. A systematic review of oncoplastic volume replacement breast surgery: oncological safety and cosmetic outcome. *Ann R Coll Surg Engl*. 2022;104(1):5–17.
- Mohamedahmed AYY, Zaman S, Zafar S, Laroia I, Iqbal J, Tan MLH, et al. Comparison of surgical and oncological outcomes between oncoplastic breast-conserving surgery versus conventional breast-conserving surgery for treatment of breast cancer: a systematic review and meta-analysis of 31 studies. *Surg Oncol*. 2022;42:101779.
- Andre C, Holsti C, Svenner A, Sackey H, Oikonomou I, Appellgren M, et al. Recurrence and survival after standard versus oncoplastic breast-conserving surgery for breast cancer. *BJS Open*. 2021;5(1):zraa013.
- Veronesi U, Cascinelli N, Mariani L, Greco M, Saccozzi R, Luini A, et al. Twenty-year follow-up of a randomized study comparing breast-conserving surgery with radical mastectomy for early breast cancer. *N Engl J Med*. 2002;347(16):1227–32.
- Boughey JC, Rosenkranz KM, Ballman KV, McCall L, Haffty BG, Cuttino LW, et al. Local recurrence after breast-conserving therapy in patients with multiple ipsilateral breast cancer: results from ACOSOG Z11102 (alliance). *J Clin Oncol*. 2023; 41(17):3184–93.
- Ditsch N, Wöcke A, Untch M, Jackisch C, Albert US, Banys-Paluchowski M, et al. AGO recommendations for the diagnosis and treatment of patients with early breast cancer: update 2022. *Breast Care*. 2022;17(4):403–20.
- Kosasih S, Tayeh S, Mokbel K, Kasem A. Is oncoplastic breast conserving surgery oncologically safe? A meta-analysis of 18,103 patients. *Am J Surg*. 2020;220(2):385–92.
- Ostapenko E, Nixdorf L, Devyatko Y, Exner R, Wimmer K, Fitzal F. Prepectoral versus subpectoral implant-based breast reconstruction: a systemic review and meta-analysis. *Ann Surg Oncol*. 2023;30(1):126–36.
- Schermers B, van Riet YE, Schipper RJ, Vrancken Peeters MJ, Voogd AC, Nieuwenhuijzen GAP, et al. Nationwide registry study on trends in localization techniques and reoperation rates in non-palpable ductal carcinoma in situ and invasive breast cancer. *Br J Surg*. 2021;109(1):53–60.
- Somasundaram SK, Potter S, Elgammal S, Maxwell AJ, Sami AS, Down SK, et al. Impalpable breast lesion localisation, a logistical challenge: results of the UK iBRA-NET national practice questionnaire. *Breast Cancer Res Treat*. 2021;185(1):13–20.
- Chan BK, Wiseberg-Firtell JA, Jois RSH, Jensen K, Audisio RA. Localization techniques for guided surgical excision of non-palpable breast lesions. *Cochrane Database Syst Rev*. 2015;2015(12):CD009206.
- Banys-Paluchowski M, Kühn T, Masannat Y, Rubio I, de Boniface J, Ditsch N, et al. Localization techniques for non-palpable breast lesions: current status, knowledge gaps, and rationale for the MELODY study (EU-BREAST-4/iBRA-NET, NCT 05559411). *Cancers*. 2023;15(4):1173.
- Schwartz GF, Goldberg BB, Rifkin MD, D’Orazio SE. Ultrasonography: an alternative to x-ray-guided needle localization of nonpalpable breast masses. *Surgery*. 1988;104(5):870–3.
- Banys-Paluchowski M, Rubio IT, Karadeniz Cakmak G, Esgueva A, Krawczyk N, Paluchowski P, et al. Intraoperative ultrasound-guided excision of non-palpable and palpable breast cancer: systematic review and meta-analysis. *Ultraschall Med*. 2022;43(4):367–79.
- Athanasidou C, Mallidis E, Tuffaha H. Comparative effectiveness of different localization techniques for non-palpable breast cancer. A systematic review and network meta-analysis. *Eur J Surg Oncol*. 2022;48(1):53–9.
- Davey MG, O’Donnell JPM, Boland MR, Ryan EJ, Walsh SR, Kerin MJ, et al. Optimal localization strategies for non-palpable breast cancers -a network meta-analysis of randomized controlled trials. *Breast*. 2022;62:103–13.
- Dave RV, Barrett E, Morgan J, Chandarana M, Elgammal S, Barnes N, et al. Wire- and magnetic-seed-guided localization of impalpable breast lesions: iBRA-NET localisation study. *Br J Surg*. 2022;109(3):274–82.
- Bloomquist EV, Ajkay N, Patil S, Collett AE, Frazier TG, Barrio AV. A randomized prospective comparison of patient-assessed satisfaction and clinical outcomes with radioactive seed localization versus wire localization. *Breast J*. 2016;22(2):151–7.
- Micha AE, Sinnen V, Downey K, Allen S, Bishop B, Hector LR, et al. Patient and clinician satisfaction and clinical outcomes of Magseed compared with wire-guided localisation for impalpable breast lesions. *Breast Cancer*. 2021;28(1):196–205.
- Early Breast Cancer Trialists’ Collaborative Group (EBCTCG), Darby S, McGale P, Correa C, Taylor C, Arriagada R, et al. Effect of radiotherapy after breast-conserving surgery on 10-year recurrence and 15-year breast cancer death: meta-analysis of individual patient data for 10,801 women in 17 randomised trials. *Lancet*. 2011;378(9804):1707–16.
- Haviland JS, Owen JR, Dewar JA, Agrawal RK, Barrett J, Barrett-Lee PJ, et al. The UK Standardisation of Breast Radiotherapy (START) trials of radiotherapy hypofractionation for treatment of early breast cancer: 10-year follow-up results of two randomised controlled trials. *Lancet Oncol*. 2013;14(11):1086–94.
- Krug D, Baumann R, Combs SE, Duma MN, Dunst J, Feyer P, et al. Moderate hypofractionation remains the standard of care for whole-breast radiotherapy in breast cancer: considerations regarding FAST and FAST-Forward. *Strahlenther Onkol*. 2021;197(4):269–80.
- Hickey BE, James ML, Lehman M, Hider PN, Jeffery M, Francis DP, et al. Fraction size in radiation therapy for breast conservation in early breast cancer. *Cochrane Database Syst Rev*. 2016;7(7):CD003860.
- Dilworth JT, Griffith KA, Pierce LJ, Jagsi R, Quinn TJ, Walker EM, et al. The impact of chemotherapy on toxic effects and cosmetic outcome in patients receiving whole breast irradiation: an analysis within a statewide quality consortium. *Int J Radiat Oncol Biol Phys*. 2022;113(2):266–77.
- Purswani JM, Jaros B, Oh C, Sandigursky S, Xiao J, Gerber NK. Toxicity and cosmetic outcome of breast irradiation in women with breast cancer and autoimmune connective tissue disease: the role of fraction and field size. *Pract Radiat Oncol*. 2022;12(2):e90–100.
- Jagsi R, Griffith KA, Vicini FA, Abu-Isa E, Bergsma D, Bhatt A, et al. Disease control after hypofractionation versus conventional fractionation for triple negative breast cancer: comparative effectiveness in a large observational cohort. *Int J Radiat Oncol Biol Phys*. 2022;112(4):853–60.
- Fodor A, Brombin C, Mangili P, Borroni F, Pasetti M, Tummineri R, et al. Impact of molecular subtype on 1325 early-stage breast cancer patients homogeneously treated with hypofractionated radiotherapy without boost: should the indications for radiotherapy be more personalized? *Breast*. 2021;55:45–54.
- Vicini FA, Winter K, Freedman G, Arthur D, Hayman J, Rosenstein B, et al. Nrg RTOG 1005: a phase III trial of hypo fractionated whole breast irradiation with concurrent boost vs. Conventional whole breast irradiation plus sequential boost following lumpectomy for high risk early-stage breast cancer. *Int J Radiat Oncology*Biophysics*. 2022;114(3):S1.

Author Contributions

Conceptualization: Maggie Banys-Paluchowski and David Krug. Project administration: Maggie Banys-Paluchowski. Writing - original draft: Maggie Banys-Paluchowski, Steffi Hartmann, Nina Ditsch, Natalia Krawczyk, Thorsten Kühn, Jana de Boniface, Joanna Banys-Kotomska, Achim Rody, David Krug. Writing - review and editing: Maggie Banys-Paluchowski, Steffi Hartmann, Nina Ditsch, Natalia Krawczyk, Thorsten Kühn, Jana de Boniface, Joanna Banys-Kotomska, Achim Rody, David Krug.

- 29 Brunt AM, Haviland JS, Sydenham M, Agrawal RK, Algrufi H, Alhasso A, et al. Ten-year results of FAST: a randomized controlled trial of 5-fraction whole-breast radiotherapy for early breast cancer. *J Clin Oncol*. 2020;38(28):3261–72.
- 30 Murray Brunt A, Haviland JS, Wheatley DA, Sydenham MA, Alhasso A, Bloomfield DJ, et al. Hypofractionated breast radiotherapy for 1 week versus 3 weeks (FAST-Forward): 5-year efficacy and late normal tissue effects results from a multicentre, non-inferiority, randomised, phase 3 trial. *Lancet*. 2020;395(10237):1613–26.
- 31 Meattini I, Becherini C, Boersma L, Kaidar-Person O, Marta GN, Montero A, et al. European society for radiotherapy and oncology advisory committee in radiation oncology practice consensus recommendations on patient selection and dose and fractionation for external beam radiotherapy in early breast cancer. *Lancet Oncol*. 2022;23(1):e21–31.
- 32 Whelan T, Levine M, Sussman J. Hypofractionated breast irradiation: what's next? *J Clin Oncol*. 2020;38(28):3245–7.
- 33 Strnad V, Krug D, Sedlmayer F, Piroth MD, Budach W, Baumann R, et al. DEGRO practical guideline for partial-breast irradiation. *Strahlenther Onkol*. 2020;196(9):749–63.
- 34 Piroth MD, Strnad V, Krug D, Fastner G, Baumann R, Combs SE, et al. Long-term results of the TARGIT-A trial: more questions than answers. *Breast Care*. 2022;17(1):81–4.
- 35 Kindts I, Laenen A, Depuydt T, Weltens C. Tumour bed boost radiotherapy for women after breast-conserving surgery. *Cochrane Database Syst Rev*. 2017;11(11):CD011987.
- 36 Bartelink H, Maingon P, Poortmans P, Weltens C, Fourquet A, Jager J, et al. Whole-breast irradiation with or without a boost for patients treated with breast-conserving surgery for early breast cancer: 20-year follow-up of a randomised phase 3 trial. *Lancet Oncol*. 2015;16(1):47–56.
- 37 Vrieling C, van Werkhoven E, Maingon P, Poortmans P, Weltens C, Fourquet A, et al. Prognostic factors for local control in breast cancer after long-term follow-up in the eortc boost vs No boost trial: a randomized clinical trial. *JAMA Oncol*. 2017;3(1):42–8.
- 38 Forster T, Köhler C, Dorn M, Häfner MF, Ariens N, König L, et al. Noninferiority of local control and comparable toxicity of intensity modulated radiation therapy with simultaneous integrated boost in breast cancer: 5-year results of the IMRT-MC2 phase III trial. *Int J Radiat Oncol Biol Phys*. 2023;S0360-3016(23):00523–0.
- 39 Coles CE, Haviland JS, Kirby AM, Griffin CL, Sydenham MA, Titley JC, et al. Dose-escalated simultaneous integrated boost radiotherapy in early breast cancer (IMPORT HIGH): a multicentre, phase 3, non-inferiority, open-label, randomised controlled trial. *Lancet*. 2023;401(10394):2124–37.
- 40 Fisher ER, Costantino J, Fisher B, Redmond C. Pathologic findings from the national surgical adjuvant breast Project (protocol 4). Discriminants for 15-year survival. National surgical adjuvant breast and bowel Project investigators. *Cancer*. 1993;71(6 Suppl):2141–50.
- 41 Zylka-Menhorn V. Karzinomchirurgie: ist die Lymphadenektomie nicht mehr zeitgemäß? *Dtsch Arztebl*. 2009;106.
- 42 Rao R, Euhus D, Mayo HG, Balch C. Axillary node interventions in breast cancer: a systematic review. *JAMA*. 2013;310(13):1385–94.
- 43 Schwartz GF, Giuliano AE, Veronesi U; Consensus Conference Committee. Proceedings of the consensus conference of the role of sentinel lymph node biopsy in carcinoma of the breast April 19–22, 2001, Philadelphia, PA, USA. *Breast J*. 2002;8(3):124–38.
- 44 Lyman GH, Temin S, Edge SB, Newman LA, Turner RR, Weaver DL, et al. Sentinel lymph node biopsy for patients with early-stage breast cancer: American Society of Clinical Oncology clinical practice guideline update. *J Clin Oncol*. 2014;32(13):1365–83.
- 45 Giuliano AE, Hunt KK, Ballman KV, Beitsch PD, Whitworth PW, Blumencranz PW, et al. Axillary dissection vs no axillary dissection in women with invasive breast cancer and sentinel node metastasis: a randomized clinical trial. *JAMA*. 2011;305(6):569–75.
- 46 Giuliano AE, McCall L, Beitsch P, Whitworth PW, Blumencranz P, Leitch AM, et al. Locoregional recurrence after sentinel lymph node dissection with or without axillary dissection in patients with sentinel lymph node metastases: the American College of Surgeons Oncology Group Z0011 randomized trial. *Ann Surg*. 2010;252(3):426–32; discussion 432–3.
- 47 Giuliano AE, Ballman KV, McCall L, Beitsch PD, Brennan MB, Kelemen PR, et al. Effect of axillary dissection vs No axillary dissection on 10-year overall survival among women with invasive breast cancer and sentinel node metastasis: the ACOSOG Z0011 (alliance) randomized clinical trial. *JAMA*. 2017;318(10):918–26.
- 48 Tinterri C, Canavese G, Gatzemeier W, Barbieri E, Bottini A, Sagona A, et al. Sentinel lymph node biopsy versus axillary lymph node dissection in breast cancer patients undergoing mastectomy with one to two metastatic sentinel lymph nodes: sub-analysis of the SINODAR-ONE multicentre randomized clinical trial and reopening of enrolment. *Br J Surg*. 2023;110(9):1143–52.
- 49 Donker M, van Tienhoven G, Straver ME, Meijnen P, van de Velde CJH, Mansel RE, et al. Radiotherapy or surgery of the axilla after a positive sentinel node in breast cancer (EORTC 10981-22023 AMAROS): a randomised, multicentre, open-label, phase 3 non-inferiority trial. *Lancet Oncol*. 2014;15(12):1303–10.
- 50 Savolt A, Péley G, Polgár C, Udvarhelyi N, Rubovszky G, Kovács E, et al. Eight-year follow up result of the OTOASOR trial: the Optimal Treatment of the Axilla: surgery or Radiotherapy after positive sentinel lymph node biopsy in early-stage breast cancer: a randomized, single centre, phase III, non-inferiority trial. *Eur J Surg Oncol*. 2017;43(4):672–9.
- 51 Bartels SAL, Donker M, Poncet C, Sauvé N, Straver ME, van de Velde CJH, et al. Radiotherapy or surgery of the axilla after a positive sentinel node in breast cancer: 10-year results of the randomized controlled EORTC 10981-22023 AMAROS trial. *J Clin Oncol*. 2023;41(12):2159–65.
- 52 Banys-Paluchowski M, Thill M, Kühn T, Ditsch N, Heil J, Wöckel A, et al. AGO recommendations for the surgical therapy of breast cancer: update 2022. *Geburtshilfe Frauenheilkd*. 2022;82(10):1031–43.
- 53 Fernandez-Gonzalez S, Falo C, Pla MJ, Pernas S, Bajen M, Soler T, et al. The shift from sentinel lymph node biopsy performed either before or after neoadjuvant systemic therapy in the clinical negative nodes of breast cancer patients. Results, and the advantages and disadvantages of both procedures. *Clin Breast Cancer*. 2018;18(1):71–7.
- 54 Banys-Paluchowski M, Untch M, Krawczyk N, Thurmann M, Kühn T, Sehouli J, et al. Current trends in diagnostic and therapeutic management of the axilla in breast cancer patients receiving neoadjuvant therapy: results of the German-wide NOGGO MONITOR 24 survey. *Arch Gynecol Obstet*. 2023;307(5):1547–56.
- 55 Moo TA, Edelweiss M, Hajiyeva S, Stempel M, Raiss M, Zabor EC, et al. Is low-volume disease in the sentinel node after neoadjuvant chemotherapy an indication for axillary dissection? *Ann Surg Oncol*. 2018;25(6):1488–94.
- 56 Banys-Paluchowski M, Rubio IT, Ditsch N, Krug D, Gentilini OD, Kühn T. Real de-escalation or escalation in disguise? *Breast*. 2023;69:249–57.
- 57 Brackstone M, Baldassarre FG, Perera FE, Cil T, Chavez Mac Gregor M, Dayes IS, et al. Management of the axilla in early-stage breast cancer: ontario health (cancer care ontario) and ASCO guideline. *J Clin Oncol*. 2021;39(27):3056–82.
- 58 Reimer T, Stachs A, Veselinovic K, Polata S, Müller T, Kühn T, et al. Patient-reported outcomes for the Intergroup Sentinel Mamma study (INSEMA): a randomised trial with persistent impact of axillary surgery on arm and breast symptoms in patients with early breast cancer. *EClinicalMedicine*. 2023;55:101756.
- 59 Banys-Paluchowski M, Thill M, Kühn T, Ditsch N, Heil J, Wöckel A, et al. AGO Breast Committee Recommendations: surgical therapy Update 2022. *AGO Empfehlungen zur operativen Therapie des Mammakarzinoms: update 2022*. *GebFra*. 2022.
- 60 Fisher B, Montague E, Redmond C, Barton B, Borland D, Fisher ER, et al. Comparison of radical mastectomy with alternative treatments for primary breast cancer. A first report of results from a prospective randomized clinical trial. *Cancer*. 1977;39(6 Suppl):2827–39.
- 61 Euhus DM. Management of the clinically positive axilla. *Breast J*. 2020;26(1):35–8.
- 62 Hartmann S, Kühn T, Hauptmann M, Stickeler E, Thill M, Lux MP, et al. Axillary staging after neoadjuvant chemotherapy for initially node-positive breast carcinoma in Germany: initial data from the AXSANA study. *Geburtshilfe Frauenheilkd*. 2022;82(9):932–40.
- 63 Kuehn T, Bauerfeind I, Fehm T, Fleige B, Hausschild M, Helms G, et al. Sentinel-lymph-node biopsy in patients with breast cancer before and after neoadjuvant chemotherapy (SENTINA): a prospective, multicentre cohort study. *Lancet Oncol*. 2013;14(7):609–18.

- 64 Boughey JC, Suman VJ, Mittendorf EA, Ahrendt GM, Wilke LG, Taback B, et al. Sentinel lymph node surgery after neoadjuvant chemotherapy in patients with node-positive breast cancer: the ACOSOG Z1071 (Alliance) clinical trial. *JAMA*. 2013;310(14):1455–61.
- 65 Classe JM, Loac C, Gimbergues P, Alran S, de Lara CT, Dupre PF, et al. Sentinel lymph node biopsy without axillary lymphadenectomy after neoadjuvant chemotherapy is accurate and safe for selected patients: the GANEA 2 study. *Breast Cancer Res Treat*. 2019;173(2):343–52.
- 66 Simons JM, van Nijnatten TJA, van der Pol CC, Luiten EJT, Koppert LB, Smidt ML. Diagnostic accuracy of different surgical procedures for axillary staging after neoadjuvant systemic therapy in node-positive breast cancer: a systematic review and meta-analysis. *Ann Surg*. 2019;269(3):432–42.
- 67 Gasparri ML, de Boniface J, Poortmans P, Gentilini OD, Kaidar-Person O, Banys-Paluchowski M, et al. Axillary surgery after neoadjuvant therapy in initially node-positive breast cancer: international EUBREAST survey. *Br J Surg*. 2022;109(9):857–63.
- 68 Caudle AS, Yang WT, Krishnamurthy S, Mittendorf EA, Black DM, Gilcrease MZ, et al. Improved axillary evaluation following neoadjuvant therapy for patients with node-positive breast cancer using selective evaluation of clipped nodes: implementation of targeted axillary dissection. *J Clin Oncol*. 2016;34(10):1072–8.
- 69 Siso C, de Torres J, Esgueva-Colmenarejo A, Espinosa-Bravo M, Rus N, Cordoba O, et al. Intraoperative ultrasound-guided excision of axillary clip in patients with node-positive breast cancer treated with neoadjuvant therapy (ILINA trial): a new tool to guide the excision of the clipped node after neoadjuvant treatment. *Ann Surg Oncol*. 2018;25(3):784–91.
- 70 Hartmann S, Kühn T, de Boniface J, Stachs A, Winckelmann A, Frisell J, et al. Carbon tattooing for targeted lymph node biopsy after primary systemic therapy in breast cancer: prospective multicentre TATTOO trial. *Br J Surg*. 2021;108(3):302–7.
- 71 de Boniface J, Frisell J, Kühn T, Wiklander-Bråkenhielm I, Dembrower K, Nyman P, et al. False-negative rate in the extended prospective TATTOO trial evaluating targeted axillary dissection by carbon tattooing in clinically node-positive breast cancer patients receiving neoadjuvant systemic therapy. *Breast Cancer Res Treat*. 2022;193(3):589–95.
- 72 Renaudeau C, Gimbergues P, Guillot E, Chauvet MP, Gutowski M, Jouve M, et al. Abstract OT1-09-01: Axillary surgery de-escalation after neoadjuvant chemotherapy in breast cancer patients with initially involved node: the GANEA 3 trial. *Cancer Res*. 2023;83(5).
- 73 Kuemmel S, Heil J, Rueland A, Seiberling C, Harrach H, Schindowski D, et al. A prospective, multicenter registry study to evaluate the clinical feasibility of targeted axillary dissection (TAD) in node-positive breast cancer patients. *Ann Surg*. 2022;276(5):e553–62.
- 74 Hartmann S, Reimer T, Gerber B, Stubert J, Stengel B, Stachs A. Wire localization of clip-marked axillary lymph nodes in breast cancer patients treated with primary systemic therapy. *Eur J Surg Oncol*. 2018;44(9):1307–11.
- 75 Banys-Pachulowski M, Paluchowski P, Krawczyk N. Twinkle artifact in sonographic breast clip visualization. *Arch Gynecol Obstet*. 2023;307(6):2021–2.
- 76 Simons JM, van Nijnatten TJA, van der Pol CC, van Diest PJ, Jager A, van Klaveren D, et al. Diagnostic accuracy of radioactive iodine seed placement in the axilla with sentinel lymph node biopsy after neoadjuvant chemotherapy in node-positive breast cancer. *JAMA Surg*. 2022;157(11):991–9.
- 77 Banys-Paluchowski M, Gasparri ML, de Boniface J, Gentilini O, Stickeler E, Hartmann S, et al. Surgical management of the axilla in clinically node-positive breast cancer patients converting to clinical node negativity through neoadjuvant chemotherapy: current status, knowledge gaps, and rationale for the EUBREAST-03 AXSANA study. *Cancers*. 2021;13(7):1565.
- 78 Galimberti V, Ribeiro Fontana SK, Vicini E, Morigi C, Sargenti M, Corso G, et al. This house believes that: Sentinel node biopsy alone is better than TAD after NACT for cN+ patients”. *Breast*. 2023;67:21–5.
- 79 Hildebrandt G, Stachs A, Gerber B, Potenberg J, Krug D, Wolter K, et al. Central review of radiation therapy planning among patients with breast-conserving surgery: results from a quality assurance process integrated into the INSEMA trial. *Int J Radiat Oncol Biol Phys*. 2020;107(4):683–93.
- 80 Borm KJ, Oechsner M, Düsberg M, Buschner G, Weber W, Combs SE, et al. Irradiation of regional lymph node areas in breast cancer: dose evaluation according to the Z0011, AMAROS, EORTC 10981-22023 and MA-20 field design. *Radiother Oncol*. 2020;142:195–201.
- 81 Jaggi R, Chadha M, Moni J, Ballman K, Laurie F, Buchholz TA, et al. Radiation field design in the ACOSOG Z0011 (alliance) trial. *J Clin Oncol*. 2014;32(32):3600–6.
- 82 de Wild SR, de Munck L, Simons JM, Verloop J, van Dalen T, Elkhuizen PHM, et al. De-escalation of radiotherapy after primary chemotherapy in cT1-2N1 breast cancer (RAPCHEM; BOOG 2010-03): 5-year follow-up results of a Dutch, prospective, registry study. *Lancet Oncol*. 2022;23(9):1201–10.