

Disclosing tumor biology by means of molecular imaging in a patient with malignant melanoma and chronic lymphocytic leukemia

Alexander Gäble, Johanna S. Enke, Martin J. Hügler, Przemyslaw Grochowski, Martin Trepel, Alexander Dierks, Christian H. Pfob, Ralph A. Bundschuh, Constantin Lapa, Malte Kircher

Angaben zur Veröffentlichung / Publication details:

Gäble, Alexander, Johanna S. Enke, Martin J. Hügler, Przemyslaw Grochowski, Martin Trepel, Alexander Dierks, Christian H. Pfob, Ralph A. Bundschuh, Constantin Lapa, and Malte Kircher. 2024. "Disclosing tumor biology by means of molecular imaging in a patient with malignant melanoma and chronic lymphocytic leukemia." *European Journal of Nuclear Medicine and Molecular Imaging* 52 (1): 366–67. <https://doi.org/10.1007/s00259-024-06834-3>.

Nutzungsbedingungen / Terms of use:

CC BY 4.0

Dieses Dokument wird unter folgenden Bedingungen zur Verfügung gestellt: / This document is made available under these conditions:

CC-BY 4.0: Creative Commons: Namensnennung


Weitere Informationen finden Sie unter: / For more information see:

<https://creativecommons.org/licenses/by/4.0/deed.de>





Disclosing tumor biology by means of molecular imaging in a patient with malignant melanoma and chronic lymphocytic leukemia

Alexander Gäble^{1,4} · Johanna S. Enke^{1,4} · Martin J. Hügle^{1,4} · Przemyslaw Grochowski^{2,4} · Martin Trepel^{3,4} · Alexander Dierks^{1,4} · Christian H. Pfof^{1,4} · Ralph A. Bundschuh^{1,4} · Constantin Lapa^{1,4}  · Malte Kircher^{1,4}

Received: 24 May 2024 / Accepted: 4 July 2024 / Published online: 15 July 2024
© The Author(s) 2024, corrected publication 2024

Figure

C-X-C motif chemokine receptor 4 (CXCR4) plays a major role in tumor growth and the process of metastasis and is thus a highly attractive target in oncology [1]. Non-invasive chemokine receptor imaging using positron emission tomography (PET) has demonstrated promising results, especially in hematologic malignancies including multiple myeloma or lymphoma [2]. Tumor detection in solid cancers is more heterogeneous (as compared to [¹⁸F]-fluorodeoxyglucose ([¹⁸F]FDG)) with many entities showing only low to moderate in vivo CXCR4 expression [3, 4].

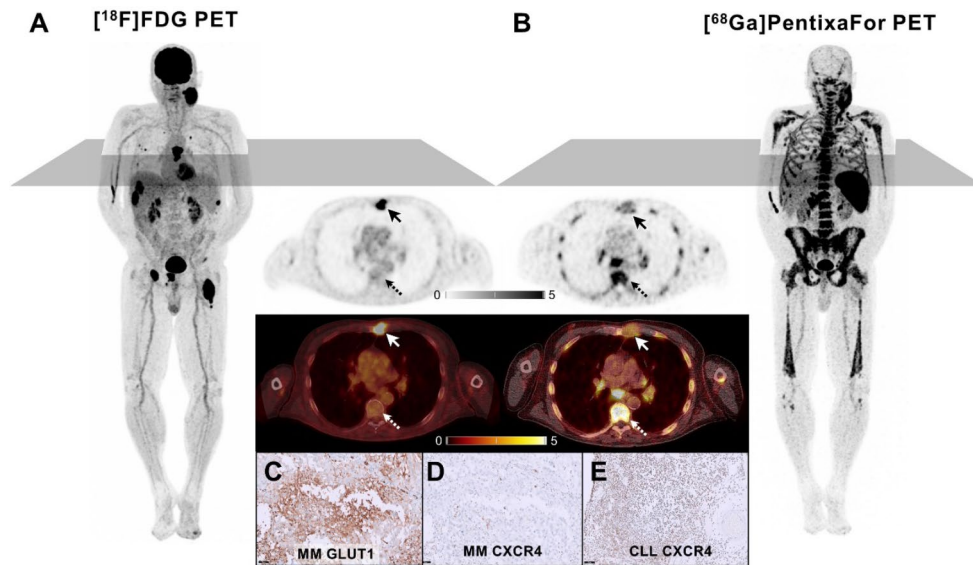
A 73-year-old male with a history of Binet Stage B chronic lymphocytic leukemia (CLL), and lentigo maligna melanoma (UICC IA) presented for re-staging with a rapidly enlarging cervical mass as well as new liver lesions (detected by previous ultrasound). [¹⁸F]FDG-PET/computed tomography (CT) displayed high uptake in the

cervical mass and liver lesions. In addition, pulmonary and osteolytic bone lesions with intense [¹⁸F]FDG accumulation could be detected (A). In contrast, CT showed various additional enlarged lymph nodes and splenomegaly with only minimal [¹⁸F]FDG uptake (A). Thus, CXCR-directed imaging was added. Contrary to [¹⁸F]FDG, [⁶⁸Ga]Ga-PentixaFor displayed intense tracer uptake -consistent with CLL- in the enlarged lymph nodes, bone marrow and spleen, and minimal uptake in the aforementioned [¹⁸F]FDG-avid sites, suggestive of melanoma metastases (B). Immunohistochemical staining confirmed these findings showing high GLUT1 (C) and low CXCR4 expression (D) in an osteolytic melanoma lesion (arrows; SUV_{max} 14.0 vs. 2.2) as opposed to intense CXCR4 expression (E) in a site with osseous CLL infiltration (dotted arrows; SUV_{max} 2.6 vs. 9.1). Our case highlights the ability of molecular imaging to non-invasively phenotype disease and visualize tumor biology.

✉ Constantin Lapa
Constantin.Lapa@uk-augsburg.de

Alexander Gäble
Alexander.Gaebler@uk-augsburg.de

- ¹ Nuclear Medicine, Faculty of Medicine, University of Augsburg, Augsburg, Germany
- ² Pathology, Faculty of Medicine, University of Augsburg, Augsburg, Germany
- ³ Hematology and Oncology, Faculty of Medicine, University of Augsburg, Augsburg, Germany
- ⁴ Bavarian Cancer Research Center (BZKF), Erlangen, Germany



Funding Open Access funding enabled and organized by Projekt DEAL.

Declarations

Ethical approval All procedures performed in studies involving human participants were in accordance with the ethical standards of the institutional and/or national research committee and with the 1964 Helsinki declaration and its later amendments or comparable ethical standards.

Informed consent Informed consent was obtained from the patient reported in this case report.

Conflict of interest CL reports prior consulting activities for Blue Earth Diagnostics Ltd. (Oxford, UK) and Novartis. RAB is consultant for and has received speaker's honoraria from Bayer Healthcare (Leverkusen, Germany), Novartis Pharma (Nürnberg, Germany) and Eisai GmbH (Frankfurt, Germany). All other authors do not report relevant conflicts of interest regarding this article.

Open Access This article is licensed under a Creative Commons Attribution 4.0 International License, which permits use, sharing, adaptation, distribution and reproduction in any medium or format, as long as you give appropriate credit to the original author(s) and the source, provide a link to the Creative Commons licence, and indicate if changes were made. The images or other third party material in this article are included in the article's Creative Commons licence, unless indicated otherwise in a credit line to the material. If material is not included in the article's Creative Commons licence and your intended

use is not permitted by statutory regulation or exceeds the permitted use, you will need to obtain permission directly from the copyright holder. To view a copy of this licence, visit <http://creativecommons.org/licenses/by/4.0/>.

References

1. Domanska UM, Kruizinga RC, Nagengast WB, Timmer-Bosscha H, Huls G, de Vries EG, et al. A review on CXCR4/CXCL12 axis in oncology: no place to hide. *Eur J Cancer*. 2013;49:219–30. <https://doi.org/10.1016/j.ejca.2012.05.005>.
2. Buck AK, Haug A, Dreher N, Lambertini A, Higuchi T, Lapa C, et al. Imaging of C-X-C motif chemokine receptor 4 expression in 690 patients with solid or hematologic neoplasms using (68) Ga-Pentixafor PET. *J Nucl Med*. 2022;63:1687–92. <https://doi.org/10.2967/jnumed.121.263693>.
3. Werner RA, Kircher S, Higuchi T, Kircher M, Schirbel A, Wester HJ, et al. CXCR4-directed imaging in solid tumors. *Front Oncol*. 2019;9:770. <https://doi.org/10.3389/fonc.2019.00770>.
4. Vag T, Gerngross C, Herhaus P, Eiber M, Philipp-Abbrederis K, Graner FP, et al. First experience with chemokine receptor CXCR4-Targeted PET imaging of patients with solid cancers. *J Nucl Med*. 2016;57:741–6. <https://doi.org/10.2967/jnumed.115.161034>.

Publisher's Note Springer Nature remains neutral with regard to jurisdictional claims in published maps and institutional affiliations.