

Arthroscopic repair of anterior-inferior glenohumeral instability using a portal at the 5:30-o'clock position: analysis of the effects of age, fixation method, and concomitant shoulder injury on surgical outcomes

Andreas B. Imhoff, Patrick Ansah, Thomas Tischer, Christoph Reiter, Christoph Bartl, Maximilian Hench, Jeffrey T. Spang, Stephan Vogt

Angaben zur Veröffentlichung / Publication details:

Imhoff, Andreas B., Patrick Ansah, Thomas Tischer, Christoph Reiter, Christoph Bartl, Maximilian Hench, Jeffrey T. Spang, and Stephan Vogt. 2010. "Arthroscopic repair of anterior-inferior glenohumeral instability using a portal at the 5:30-o'clock position: analysis of the effects of age, fixation method, and concomitant shoulder injury on surgical outcomes." *The American Journal of Sports Medicine* 38 (9): 1795–1803.
<https://doi.org/10.1177/0363546510370199>.



Arthroscopic Repair of Anterior-Inferior Glenohumeral Instability Using a Portal at the 5:30-o'Clock Position

Analysis of the Effects of Age, Fixation Method, and Concomitant Shoulder Injury on Surgical Outcomes

Andreas B. Imhoff,* MD, Patrick Ansah, MD, Thomas Tischer, MD, Christoph Reiter, MD, Christoph Bartl, MD, Maximilian Hench, MD, Jeffrey T. Spang, MD, and Stephan Vogt, MD
From the Department of Orthopaedic Sports Medicine, Klinikum Rechts der Isar, Technical University Munich, Munich, Germany

Background: Traumatic anterior-inferior shoulder joint dislocations are common injuries among the young athletic population. The aim of this study was to assess which factors, including concomitant injury (rotator cuff tears, superior labral anterior posterior [SLAP] lesions), patient age, and fixation methods, led to redislocation after arthroscopic stabilization.

Hypothesis: There are several risk factors for the outcome after arthroscopic anterior-inferior glenohumeral stabilization.

Study Design: Cohort Study; Level of evidence, 3.

Methods: Between 1996 and 2000, 221 patients were treated with arthroscopic stabilization for anterior-inferior shoulder dislocation. Of these 221 consecutive patients, 190 (140 male, 50 female) with an average age of 28.0 years (range, 14.4-59.2 years) were available for follow-up (average follow-up, 37.4 ± 15.8 months). Fixation methods were FASTak (n = 138), Suretac (n = 28), or Panalok (n = 24) anchors. Concomitant SLAP lesions were seen in 38 of 190 cases (20%).

Results: Redislocation rates varied between anchor systems (FASTak, 6.5%; Suretac, 25%; Panalok, 16.8%). Superior labral anterior posterior lesions, when treated, did not influence clinical outcomes or redislocation rate. A concomitant rotator cuff tear did not influence redislocation rate. Postoperative outcomes (Rowe score, Constant score, American Shoulder and Elbow Surgeons [ASES] shoulder index, 12-item questionnaire) in patients with a partial tear were also not altered. On the other hand, the redislocation rate correlated with patient age and number of prior dislocations. Return to sports at preinjury level was possible in 80% of cases.

Conclusion: Arthroscopic repair of anterior-inferior instability using the 5:30-o'clock portal is dependent on anchor type and can show good to excellent results. Because of several coinjuries in anterior-inferior instability, an arthroscopic approach may be required to identify and treat such lesions.

Keywords: glenohumeral; instability; risk factors; anterior-inferior portal

Shoulder dislocation is a common injury among young, active people. The risk of redislocation after a first-time traumatic shoulder instability depends on the age of the

patient and approaches 80% in people younger than 20 years.^{14,24,28} Therefore the surgical treatment of shoulder instability is indicated, especially in younger patients. Surgery can be performed with an open or arthroscopic technique. The success rate of open surgical treatment for shoulder instability has been high, with reported redislocation rates of less than 10%.^{12,20} Open surgical techniques permit repair of the medial capsulolabral complex through capsular tightening and appropriate tensioning of the capsular ligaments. A loss of external rotation may occur as a result of overtightening.^{30,31} Also, the open approach and its associated dissection of the subscapularis tendon can lead to partial muscle insufficiency.³² Return to sports

*Address correspondence to Andreas B. Imhoff, MD, Department of Orthopaedic Sports Medicine, Klinikum rechts der Isar, TU Munich, Ismaninger Strasse 22, 81675 Munich, Germany (e-mail: A.Imhoff@lrz.tu-muenchen.de).

The authors declared that they had no conflicts of interest in their authorship and publication of this contribution.

at a lower level has been reported, especially in overhead throwing athletes.^{2,30}

To avoid these problems, arthroscopic stabilization procedures have gained in popularity. Over the past decade, rapid technical evolution has allowed arthroscopic stabilization to be considered a standard technique.^{10,17,35} Less soft tissue dissection, better diagnostic capabilities, and repair of all accompanying lesions have been noted as strengths of the arthroscopic approach. Additionally, patient morbidity is significantly decreased. The best procedure for collision athletes is not yet established.^{22,27}

The aim of this study was to examine which factors contributed to failure of arthroscopic stabilization with the deep anterior-inferior (5:30-o'clock) portal in 190 consecutive arthroscopic shoulder stabilization procedures. Factors examined included type of anchor, concomitant injury (previous stabilization surgery, superior labral anterior posterior [SLAP] lesions,³³ and rotator cuff tears), number of dislocations before the stabilization procedure, and patient age. The pre- and postoperative level of sport activity was also examined.

MATERIALS AND METHODS

A total of 190 consecutive patients with anterior-inferior shoulder instability who were managed with arthroscopic stabilization procedures between April 1996 and December 2000 compose the patient group. Different suture anchors were used during treatment (FASTak, Arthrex, Naples, Florida [n = 138]; Suretac, Smith & Nephew Endoscopy, Andover, Massachusetts [n = 28]; Panalok, DePuy Mitek, Raynham, Massachusetts [n = 24]) (Figure 1) for anterior-inferior glenohumeral instability. Patients with a previous anterior-inferior shoulder stabilization (open or arthroscopic) (n = 14), concomitant rotator cuff tears (n = 15), or SLAP V²¹ (n = 38) lesions were included. Patients with other unrelated sources of shoulder pain including acromioclavicular joint arthritis, brachial plexus lesions, and glenohumeral arthritis were excluded. Also excluded were patients with posterior or multidirectional instability as well as bony Bankart defects. A total of 221 patients met the criteria for inclusion in the study. Seventeen patients could not be contacted for the last follow-up, and 14 patients declined to participate for various reasons (no time [n = 6], unrelated severe disease [n = 1], dissatisfaction with the team [n = 3], displeasure with the outcome [n = 2], no comment [n = 2]). Therefore, the results of 190 arthroscopic anterior-inferior glenohumeral arthroscopic stabilizations were available for review.

Demographics

The study group consisted of 140 male and 50 female patients with anterior-inferior shoulder instability. Average follow-up was 37.4 ± 15.8 months (range, 14.1-72.8 months). Mean age at the time of surgery was 28.0 ± 8.4 years (range, 14.4-59.2 years).

Patient Factors

The dominant shoulder was involved in 101 patients and the nondominant shoulder in 89 patients. Six patients had subluxations. A subluxation was presumed if patients had feelings of instability during an abduction/external rotation movement but had no dislocation. Forty-four patients had 1 dislocation, 58 had 2 to 5 previous dislocations, and 68 had more than 5 previous dislocations. Fourteen patients experienced redislocations after initial operative shoulder stabilization (open, n = 7; arthroscopic, n = 7).

METHODS

Before the operation, all patients completed the Rowe-score questionnaire.³¹ A sport activity level pre- and postoperative questionnaire was also completed that included frequency (times per week), intensity (hours per day), and level (leisure, amateur, professional) of performed sport. Radiographs were obtained in 3 planes (true AP, axial, Y view). Preoperative MRI with intra-articular contrast enhancer (Magnevist [2.5 mmol/L], Schering GmbH, Berlin, Germany) was completed to obtain images of the capsulolabral lesion and biceps tendon anchor and to evaluate the capsule volume.

Follow-up measures included the Rowe questionnaire, the American Shoulder and Elbow Surgeons (ASES) shoulder index, and the scoring system of Constant and Murley.^{7,26} Strength measurements (abduction in the scapula plane) for the Constant-Murley score were performed with a strength measurement device (Isobex 3.0, Prima-tron AG, Bern, Switzerland). In addition, the patients completed the 12-item questionnaire according to Dawson et al.⁸ Both shoulders were examined for stability using the anterior drawer test, posterior drawer test, and the sulcus sign. Results were graded according to Hawkins et al.¹¹

Surgical Technique

One surgeon (A.B.I.) either performed or directed all surgeries. The surgical technique has been described previously.³⁵ Briefly, the patient was placed in the beach-chair position under general anesthesia and the type and direction of the instability was confirmed. Diagnostic arthroscopy was performed from a posterior portal. Next, the anterior-superior portal was placed anterior to the acromioclavicular joint, slightly medial to the long biceps tendon and close to the glenoid rim. The stability of the labrum and the biceps tendon anchor were assessed with a probe. For anterior-inferior labral lesions, the anterior labrum was mobilized with an elevator. Decortication of the glenoid neck was done until punctuate bleeding occurred. Next, the deep anterior-inferior portal was placed about 8 to 10 cm distal to the coracoid process and lateral to the axillary fold.⁹ Under arthroscopic visualization, a Wissinger rod was inserted through the lower third of the subscapularis tendon and a long clear arthroscopy cannula (9 × 8.25 mm) was advanced. Anchors were implanted (after debridement with a bur of each position)



Figure 1. Photographs of the different anchors: A, Panalok (Depuy Mitek); B, Suretac (Smith & Nephew Endoscopy); and C, 2.8-mm FASTak/2.0 Ethibond (Arthrex).

at the glenoid edge and the capsular shift (FASTak and Panalok anchors) was carried out with a suitable set of instruments (eg, Spectrum [Linvatec, Largo, Florida]). The exact amount of capsular shift depended on the existing capsular laxity, which was determined by a dynamic shoulder examination visualized arthroscopically. A minimum of 3 anchors was used, favoring the 5:30-, 4:30-, and 3:00-o'clock positions. Capsular tensioning was performed based on maximum tension of the inferior glenohumeral ligament in 60° of abduction and 0° of external rotation, so that excessive tightening was avoided. The middle glenohumeral ligament was then tightened in 45° of abduction and 0° of external rotation. If needed, the superior glenohumeral ligament was tightened in 15° of abduction and 0° of external rotation. The “Nicky” or fisherman’s sliding knots were utilized as these can be tied quickly and easily.

For the Suretac anchor, the released capsulolabral tissue was grasped through the superior portal and shifted superiorly, thus proximally advancing the edge of the labrum and the inferior glenohumeral ligament complex. Then the drill and guidewire were placed against the capsule or labrum via the deep anterior-inferior portal at a point that placed maximum tension on the soft tissue. The drill was then placed over the guidewire in the bone to the desired depth at the glenoid edge. The inferior Suretac was placed first over the guidewire. The Suretac was then tapped into the glenoid, and the guidewire was removed.

If an accompanying SLAP lesion was detected, 2 additional anchors were placed. A so-called “suspension sling” was placed as a first step to pull the superior labrum in a mediocranial direction away from the glenoid rim.⁴ This created sufficient space for glenoid preparation (decortication), anchor positioning, and suture placement. Using needle localization, a lateral portal was created. Anchors were inserted and the sutures were passed around the biceps tendon anchor. Small bucket-handle tears or frayed labrum were resected.

Excessive capsule volume could be reduced by additional insertion of resorbable polydioxanone synthetic (PDS) 2-0 plication sutures. In cases of accompanying hyperlaxity (positive sulcus sign persisting in external rotation), closure of the rotator interval was performed with 2 PDS sutures.³⁵

Postoperative Management

After anterior-inferior glenohumeral stabilization, the arm was immobilized in a sling for 24 hours. The sling was continued at night for 4 weeks. Rehabilitation began on postoperative day 1 under the direction of a trained physical therapist, focusing on rotator cuff strengthening and range of motion (weeks 1-3: active abduction and flexion 45°, active internal/external rotation 80° to -30°; weeks 4-6: active abduction and flexion 90°, active internal/external rotation 80° to 0°; afterward free range of motion is allowed). Free motions of the elbow and wrist were encouraged. The rehabilitation program lasted for approximately 6 months. If an accompanying SLAP lesion was present, no active biceps training was permitted for 6 weeks. Full overhead sporting activities were allowed after 6 months.

Factors examined included the following: type of anchor, concomitant injury (SLAP lesions and rotator cuff tears), revision surgery, number of dislocations before the stabilization procedure, and patient age.

Statistical Analysis

Paired *t* tests were used to determine if differences existed between preoperative and postoperative scores. Within-subject analyses of variance were used to evaluate differences among items (such as degree of instability, patient compliance, and frequency of preoperative dislocations) with 3 variables or more. Tukey post hoc testing was completed for all possible pairwise comparisons, with the overall experimental alpha level maintained at .05. Standard statistical software (SPSS, Chicago, Illinois) was used to analyze the data.

RESULTS

Postoperative Results for Patients Without Redislocation

A total of 170 patients did not have a postoperative redislocation at the last follow-up. The Rowe score increased significantly from 32.2 ± 17.2 preoperatively to $88.0 \pm$

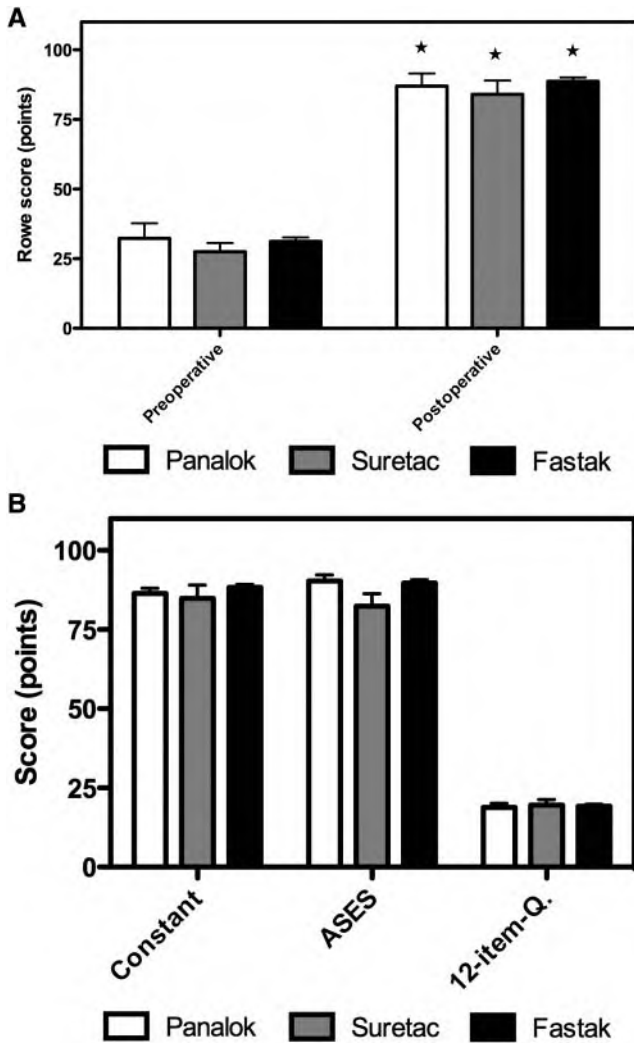


Figure 2. A, Rowe score. Significant increase of postoperative compared with preoperative score. * $P < .05$. Results are not dependent on anchor type ($P > .05$). B, postoperative shoulder scores. Results are not dependent on anchor type ($P > .05$). ASES, American Shoulder and Elbow Surgeons.

17.1 postoperatively ($P < .05$) in these patients (Figure 2A). In addition, there were good to excellent results for the postoperative Constant-Murley and ASES scores and the 12-item-questionnaire (Figure 2B). Although the redislocation rates for the Panalok and Suretac anchors were much higher than for the FASTak anchor system ($P < .05$) (Figure 3), there was no significant difference in clinical outcome between patient groups if no redislocation occurred ($P > .05$).

The external rotation deficit (in 0°/90° abduction) in comparison with the contralateral side in the FASTak group was $6.6^\circ \pm 12.8^\circ/3.9^\circ \pm 8.8^\circ$; in the Panalok group, $2.6^\circ \pm 3.8^\circ/1.6^\circ \pm 4.7^\circ$; and in the Suretac group, $4.3^\circ \pm 4.8^\circ/2.8^\circ \pm 4.3^\circ$. There was no significant difference between the anchor groups regarding external rotation ($P > .05$).

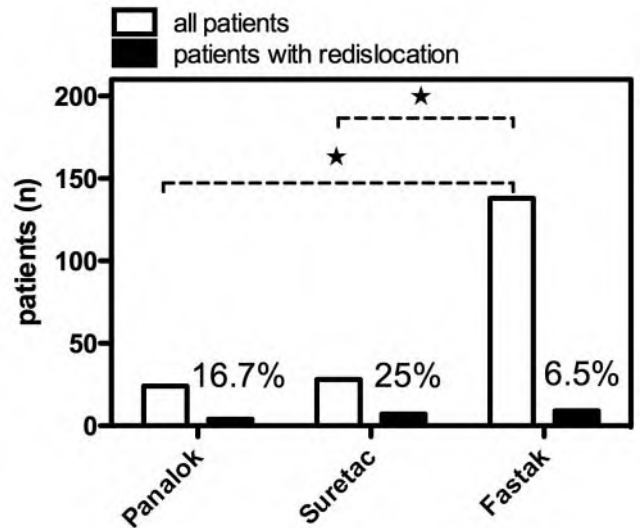


Figure 3. Influence of anchors on postoperative redislocation. Redislocation rate is dependent on anchor type. * $P < .05$.

Fixation Type Affects Redislocation Rate

The majority of patients ($n = 138$) were treated with FASTak anchors. Nine of 138 (6.5%) of these patients sustained a redislocation and 3 of 138 (2.2%) a subluxation after 3 years. The Suretac anchor was used in 28 cases. In this group, 25% (7 of 28) of patients experienced a redislocation and 7.1% (2 of 28) a subluxation. Panalok anchors were placed in 24 patients. In this group, 4 of 24 patients sustained a redislocation (16.8%) and 2 of 24 a subluxation (8.3%) (Figure 3). The redislocation rate in the FASTak group was significantly lower than in the Suretac or in the Panalok group ($P < .05$), whereas there was no statistically significant difference between the redislocation rate of the Panalok and the Suretac group ($P > .05$). The redislocations were traumatic in 16 cases and atraumatic in 5 cases. Redislocations occurred at approximately 16.7 ± 12.2 months after surgery.

Results After Arthroscopic Stabilization With a Concomitant SLAP Lesion

In 38 of 190 patients (20%), a SLAP V lesion was identified. Two additional anchors were used for SLAP repair after the primary labral repair had been completed. The Rowe, Constant-Murley, ASES, and 12-item questionnaire scores were comparable among patients with and without a concomitant SLAP lesion if a redislocation was not recorded ($P > .05$) (Figure 4). The redislocation rate within the SLAP V group was 2 of 32 patients (6.3%) with FASTak anchor fixation, 1 of 2 patients (50%) with Panalok anchor fixation, and 1 of 4 patients (25%) with Suretac anchor fixation. These results were similar to those recorded for patients who did not have a concomitant, treated SLAP lesion: FASTak anchor, 7 of 106 (6.6%) dislocations;

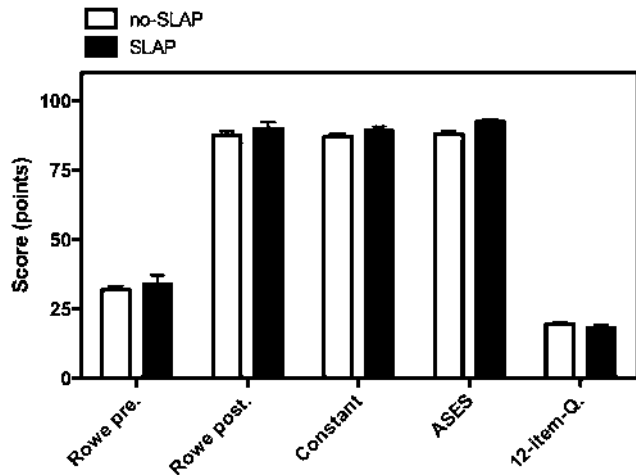


Figure 4. Concomitant SLAP lesion. Scores are not dependent on concomitant SLAP lesions ($P > .05$). SLAP, superior labral anterior posterior; ASES, American Shoulder and Elbow Surgeons.

Panalok anchor, 3 of 22 (13.6%) dislocations; and Suretac anchor, 6 of 24 (25%) dislocations.

Results After Revision Surgery

Seven patients with anterior-inferior glenohumeral instability were treated by an open technique before arthroscopic stabilization (capsular shift, no bone grafting, $n = 7$ in foreign departments). Arthroscopic stabilization in revision surgery was successful in all 7 patients. In addition, 7 patients were treated with an arthroscopic stabilization procedure before arthroscopic treatment in our department for symptomatic instability ($n = 4$ in foreign departments, $n = 3$ in our department). Six of 7 patients had a stable glenohumeral joint after our revision arthroscopic stabilization procedure.

Results After Arthroscopic Stabilization With a Concomitant Rotator Cuff Tear

Fifteen of 190 patients with anterior-inferior glenohumeral instability were diagnosed during surgery with a partial or complete supraspinatus tendon tear (partial: $n = 12$, mean age $30.2 \pm 1.2.6$ years; complete: $n = 3$, mean age 39.7 ± 5.1 years). Four of these rotator cuff tears (3 complete and 1 partial tear) were treated with a mini-open repair of the tendon ($3 \times$ corkscrew, $1 \times$ transosseous). The other partial lesions were not treated. The postoperative results (Rowe, Constant-Murley, ASES score, and 12-item questionnaire) were comparable between patients without a rotator cuff tear and patients with a partial rotator cuff tear ($P > .05$) (Figure 5) regardless of whether the partial tear was treated. In contrast, there was significant impairment for patients with a complete tear of the rotator cuff ($P < .05$) (Figure 5). The presence or absence of a rotator cuff

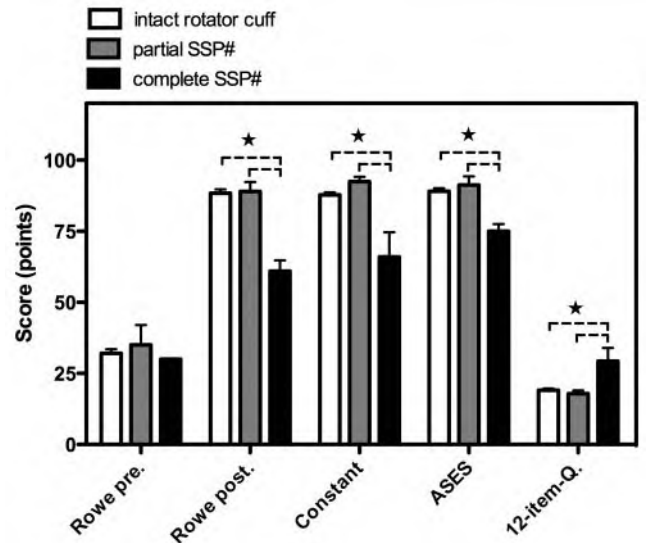


Figure 5. Influence of rotator cuff tears on postoperative results. The postoperative results were comparable between patients without a rotator cuff tear and patients with a partial rotator cuff tear ($P > .05$) regardless of whether the partial tear was treated. In contrast, there was significant impairment for patients with a complete tear of the rotator cuff. $*P < .05$.

tear had no influence on redislocation rate (data not shown).

Redislocation Rate Is Affected by the Number of Preoperative Dislocations

Before arthroscopic shoulder stabilization, 6 patients (group A) had only subluxations, 44 patients (group B) had 1 dislocation, 58 had 2 to 5 dislocations (group C), 68 had over 5 dislocations (group D), and 14 (group E) had redislocations after stabilization. After arthroscopic stabilization, groups A and B had significantly lower redislocation rates than groups C, D, and E ($P < .05$) (Figure 6). Interestingly, there was no difference in redislocation rate between groups C, D, and E ($P > .05$) (Figure 6).

Patient Age Affects Redislocation Rate

The mean age of patients with a redislocation after surgery was 23.8 ± 7.5 years (range, 16.0-59.2 years) and was significantly lower ($P < .05$) than the mean age of patients without redislocation (28.3 ± 8.0 years; range, 15.7-56.7 years). All patients were divided preoperatively into 3 groups. Group I included patients younger than 20 years ($n = 35$, 8 redislocations [22.9%] and 2 subluxations [5.9%]). Group II included patients aged 21 to 30 years ($n = 87$, 8 redislocations [9.2%] and 2 subluxations [2.3%]). Group III included patients aged 31 years and older ($n = 68$, 4 redislocations [5.9%] and 3 subluxations [4.4%]). The redislocation rate was significantly lower in

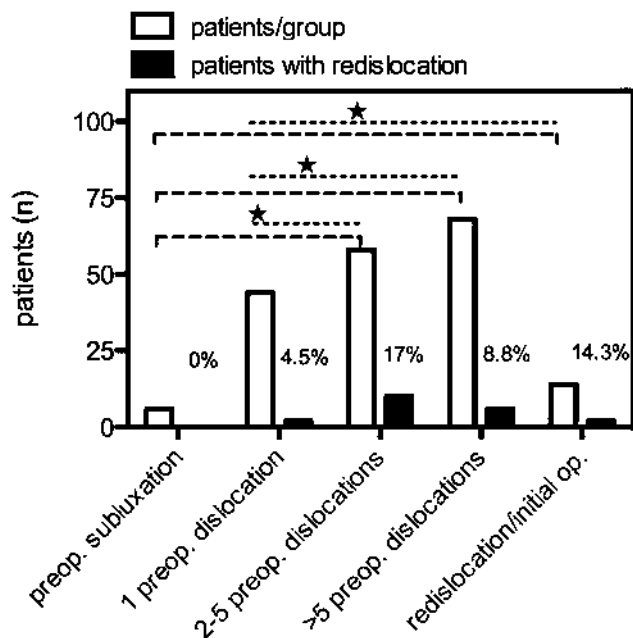


Figure 6. Influence of prior dislocations on postoperative redislocation. Redislocation rate is dependent on amount of previous dislocations. * $P < .05$.

group III compared with groups I and II ($P < .05$). In addition, the redislocation rate in group II was significantly lower than in group I ($P < .05$). The recurrent instability (redislocation plus subluxation) was significantly lower in groups II and III compared with group I ($P < .05$) but there was no significant difference between groups II and III.

Sport Activity

Before injury, 165 of the 170 patients who would go on to remain stable postoperatively noted a decrease in the level of sport activity after their first dislocation. These 165 patients were analyzed regarding their sport activity with a sport activity score (see Materials and Methods section). Two patients did not complete the sport questionnaire while 3 patients continued at the original sport activity level. Thirteen patients were professionally active before their first glenohumeral dislocation. After arthroscopic stabilization, however, 6 of the professional athletes (46.2%) were able to return to sports on a professional level, while 2 returned on an amateur level and 5 on a leisure level. Sixty patients were classified at the amateur level before their first dislocation. After surgery, 35 patients (58.3%) were able to return to sports on the amateur level while 25 patients returned on a lower level. Ninety patients were classified at the leisure level before their first dislocation. After surgery, 87 patients were active on the same level (96.6%), while 3 patients participated at a higher level (amateur) (Table 1). In total for all groups, 19.5% of patients did not reach their former sport level. According to patient self-evaluations, the

frequency, intensity, strength, and range of motion of the operative shoulder increased significantly after arthroscopic stabilization but did not return completely to preinjury levels.

Redislocation in Dependence to a "Learning Curve"

Results for the FASTak anchors were constant during this period. For Suretac and Panalok anchors, results are particularly worse in the first year (Table 2). However, case numbers are too low for a valid statistical analysis.

5:30-o'Clock Portal and Complications

No complications were reported related to the use of the 5:30-o'clock portal. Specifically, no transient or permanent axillary nerve injuries and no arterial or venous injuries were reported.

DISCUSSION

For those patients treated with a FASTak anchor system, the reported redislocation rate of 6.5% in this study is comparable with that in the recent literature.^{10,17} The reported success rate in a recent study using a suture anchor technique with nonabsorbable sutures in 40 consecutive patients who were less than 20 years of age was 93%.¹ Kim et al¹⁷ also reported good results with arthroscopic Bankart repair using a minimum of 3 suture anchors. They noted no differences in loss of external rotation and return to prior activity when comparing groups repaired using arthroscopic versus open techniques.¹⁶ Gartsman et al¹⁰ considered the results of arthroscopic stabilization comparable with open procedures and noted that success rates can be improved with appropriate treatment of concomitant lesions such as a tear of the superior labrum. Although our technique is similar to those previously reported, we used a deep anterior-inferior portal for anchor placement.^{9,35} The lowest anchor (5:30 o'clock) is especially important for refixation and plication of the inferior glenohumeral ligament, which is the main restraint of anterior head translation in the vulnerable abduction/external rotation position. In our opinion, this anchor can be optimally placed through a deep anterior-inferior portal (5:30 o'clock). This deep anterior-inferior portal, when combined with appropriate labral repair, has yielded redislocation rates that are equal to the best studies in the current literature.

For our patient population, the choice of anchor clearly influenced redislocation rates. When employing new technology such as implants, our department makes every effort to review outcomes after an appropriate time period. Our department elected to discontinue use of the Suretac system after multiple clinical failures. The department then employed both kinds of suture anchors until clinical results from our department indicated possible benefits to employing the FASTak anchor system. It was shown

TABLE 1
Sport Questionnaire: Intensity, Frequency, and Level of Sport Initially, Preoperatively, and Postoperatively^a

	Before First Dislocation		Preoperative		Postoperative		Significance (Preop/Postop) P Value
	Mean	SD	Mean	SD	Mean	SD	
Days/wk	3.35	1.72	1.74	1.84	2.43	1.62	<.0001
Hours/d	2.65	1.51	1.45	1.55	2.26	1.56	<.0001
Activity	100%	—	43.9%	36.6%	80.9%	28.9%	<.0001
Force	100%	—	50.1%	33.3%	87.6%	16.4%	<.0001
Endurance	100%	—	57.6%	35.9%	89.5%	16.3%	<.0001
ROM	100%	—	49.8%	31.9%	89.7%	12.1%	<.0001

^aSD, standard deviation; ROM, range of motion.

TABLE 2
Redislocation in Dependence to a "Learning Curve"

	1996	1997	1998	1999	2000
Panalok			2 of 3	1 of 13	1 of 8
Suretac	3 of 8	4 of 20			
FASTak	0 of 3	2 of 13	2 of 30	1 of 36	4 of 56

in a prior biomechanical study that the anchor failure load in a simulated Bankart repair was 722.8 N for the 2.8-mm FASTak anchor with Ethibond No. 2 (Ethicon, Somerville, New Jersey), 468.4 N using Suretac anchors, and 983.8 N using Panalok anchors.²³ As with prior studies, the treatment of anterior-inferior shoulder instability with Suretac anchors resulted in significantly higher redislocation rates.¹⁵ Other reports have noted early biomechanical failure of Suretac anchors.⁵ The high failure rate of the Panalok anchor, which had high initial biomechanical stability, is not easily explained. The initial biomechanical stability in a cadaver and long-term stability of a fixation method in humans are not inevitably comparable. For those patients in whom redislocation did not occur, the clinical results were excellent regardless of which suture anchor was employed.

Patients who previously failed an open stabilization procedure were successfully operated in all 7 cases using the described arthroscopic technique. In addition, patients who previously failed an arthroscopic stabilization had a stable joint in 6 of 7 cases after our arthroscopic procedure at last follow-up. Therefore, arthroscopic revision treatment of repeated glenohumeral instability is possible if careful technique is employed. However, the number of revision cases in our patient cohort is low.

In contrast to other reports, the redislocation rate in patients with more than 5 preoperative dislocations was not significantly higher than the rate for patients who had between 2 and 5 preoperative dislocations.³⁴ The significantly lower redislocation rate noted in first-time dislocators may be a result of the limited damage suffered by the capsulolabral glenoid complex after only 1 dislocation.³ Jakobsen et al¹⁴ showed that results are better and recurrence is lower if the first traumatic anterior dislocation is treated with a primary labral repair. Given our findings

of a higher recurrence rate of instability in the patients who suffered more than 1 preoperative dislocation, it may be important to consider stabilization after only 1 dislocation, especially in the younger patient (<20 years) population, where redislocation rate approaches 80% when left untreated.^{14,24,28}

In our population we found a high prevalence of a superiorly detached labrum (SLAP V lesion, 20%). When adequately repaired, outcomes for these patients were comparable with the overall group without additional SLAP lesions. A high presence of SLAP lesions was also noted in the study of Yiannakopoulos et al.³⁶ Therefore, the arthroscopic stabilization procedure may have an advantage compared with open stabilization because SLAP lesions can be diagnosed and treated during the index procedure.

With regard to tears of the rotator cuff, a partial tear of the rotator cuff did not negatively influence the clinical outcome scores, regardless of whether a rotator cuff repair was attempted. This is in contrast to those patients treated for complete rotator cuff tear at the time of arthroscopic stabilization who had poorer results even though the rotator cuff was repaired. Although clinical outcome scores were negatively affected, a complete rotator cuff tear did not influence the redislocation rate among our patients. This finding is in contrast to the results of Robinson et al²⁹ and Porcellini et al.²⁵ In the first study, patients had an increased risk of early redislocation if a large rotator cuff tear occurred in conjunction with the dislocation. Robinson et al assumed that injury to the rotator cuff had an additional destabilizing effect on the shoulder. In the second study, a strong correlation between the rising number of dislocations and associated lesions of the supraspinatus and infraspinatus tendons was described.²⁵ But data did not permit one to conclude whether repair of the

cuff tear alone can achieve shoulder stability or whether shoulder stabilization alone can resolve the instability. However, the number of concomitant complete rotator cuff tears in our study is low ($n = 3$) and therefore definitive conclusions about the influence of such rotator cuff tears on our outcomes may be hard to reach.

Our results show that the level of sport activity was improved by the surgical procedure, but often patients did not return to preinjury sport activity levels. Whereas leisure-level sport could be continued in almost all patients after surgery, the return of higher level athletes to previous sporting activities was less certain. In the literature, the success rate regarding return to former sport levels after shoulder stabilization varies between 68% and 90%.^{6,13,19} Especially among overhead and throwing athletes, a return to preinjury sport activity level is difficult.¹³

One weakness of this study is the different group size of the 3 compared anchor systems. Because of high redislocation rates within the Suretac and Panalok groups, we think that it is not ethically justifiable to go on with these systems. On the other hand, it is the first study in this field that compared different anchor systems. Strengths of this study include the large patient population, the pre- and postoperative evaluations, and the analysis of concomitant lesions.

CONCLUSION

The wide variety of lesions, the variable patient populations, the operative techniques, the duration of follow-up, and the use of multiple scoring systems complicate comparisons between this report and other arthroscopic or open stabilization studies. However, on the basis of the functional results and the postoperative redislocation rate described in the present analysis, we conclude that the functional results and the redislocation rate of our arthroscopic repair of anterior-inferior glenohumeral instability using FASTak anchors is comparable with that of previous arthroscopic reports^{10,16,18} and is at least equivalent to that of open repair.^{12,20} We noted that anchor selection can greatly affect redislocation rates; therefore the choice of labral fixation method is critical for success. Our data showed that successful treatment requires a flexible operative approach that is capable of addressing all concomitant injuries. We believe that the success of our arthroscopic approach was due to our ability to perform an anatomic repair of the anterior-inferior labrum while identifying and treating concomitant lesions (eg, SLAP lesions, rotator interval insufficiency, capsular laxity). In addition, the 5:30-o'clock portal appears safe as we did not note any complications associated with its use in our patient cohort. On the basis of our results, the surgeon can feel confident that treating instability with associated SLAP lesions and partial rotator cuff tears can lead to a successful outcome.

REFERENCES

- Bacilla P, Field LD, Savoie FH 3rd. Arthroscopic Bankart repair in a high demand patient population. *Arthroscopy*. 1997;13(1):51-60.
- Bigliani LU, Kurzweil PR, Schwartzbach CC, Wolfe IN, Flatow EL. Inferior capsular shift procedure for anterior-inferior shoulder instability in athletes. *Am J Sports Med*. 1994;22(5):578-584.
- Boileau P, Villalba M, Hery JY, Balg F, Ahrens P, Neyton L. Risk factors for recurrence of shoulder instability after arthroscopic Bankart repair. *J Bone Joint Surg Am*. 2006;88(8):1755-1763.
- Burkart A, Imhoff AB. The suspension sling for arthroscopic fixation of SLAP lesions. *Arthroscopy*. 2002;18(6):E33.
- Burkart A, Imhoff AB, Roscher E. Foreign-body reaction to the bioabsorbable suretac device. *Arthroscopy*. 2000;16(1):91-95.
- Cho NS, Hwang JC, Rhee YG. Arthroscopic stabilization in anterior shoulder instability: collision athletes versus noncollision athletes. *Arthroscopy*. 2006;22(9):947-953.
- Constant CR, Murley AH. A clinical method of functional assessment of the shoulder. *Clin Orthop Relat Res*. 1987;214:160-164.
- Dawson J, Fitzpatrick R, Carr A. Questionnaire on the perceptions of patients about shoulder surgery. *J Bone Joint Surg Br*. 1996;78(4):593-600.
- DeSimoni C, Burkart A, Imhoff AB. A new inferior portal for arthroscopic repair of the Bankart-lesion. *Arthroscopie*. 2000;13:217-219.
- Gartsman GM, Roddey TS, Hammerman SM. Arthroscopic treatment of anterior-inferior glenohumeral instability: two to five-year follow-up. *J Bone Joint Surg Am*. 2000;82(7):991-1003.
- Hawkins RJ, Schutte JP, Janda DH, Huckell GH. Translation of the glenohumeral joint with the patient under anesthesia. *J Shoulder Elbow Surg*. 1996;5(4):286-292.
- Hobby J, Griffin D, Dunbar M, Boileau P. Is arthroscopic surgery for stabilization of chronic shoulder instability as effective as open surgery? A systematic review and meta-analysis of 62 studies including 3044 arthroscopic operations. *J Bone Joint Surg Br*. 2007;89(9):1188-1196.
- Ide J, Maeda S, Takagi K. Arthroscopic Bankart repair using suture anchors in athletes: patient selection and postoperative sports activity. *Am J Sports Med*. 2004;32(8):1899-1905.
- Jakobsen BW, Johannsen HV, Suder P, Sojbjerg JO. Primary repair versus conservative treatment of first-time traumatic anterior dislocation of the shoulder: a randomized study with 10-year follow-up. *Arthroscopy*. 2007;23(2):118-123.
- Kartus C, Kartus J, Matis N, Forstner R, Resch H. Long-term independent evaluation after arthroscopic extra-articular Bankart repair with absorbable tacks: a clinical and radiographic study with a seven to ten-year follow-up. *J Bone Joint Surg Am*. 2007;89(7):1442-1448.
- Kim SH, Ha KI. Bankart repair in traumatic anterior shoulder instability: open versus arthroscopic technique. *Arthroscopy*. 2002;18(7):755-763.
- Kim SH, Ha KI, Cho YB, Ryu BD, Oh I. Arthroscopic anterior stabilization of the shoulder: two to six-year follow-up. *J Bone Joint Surg Am*. 2003;85(8):1511-1518.
- Kim SH, Ha KI, Kim YM. Arthroscopic revision Bankart repair: a prospective outcome study. *Arthroscopy*. 2002;18(5):469-482.
- Larain MV, Montenegro HJ, Mauas DM, Collazo CC, Pavon F. Arthroscopic management of traumatic anterior shoulder instability in collision athletes: analysis of 204 cases with a 4- to 9-year follow-up and results with the suture anchor technique. *Arthroscopy*. 2006;22(12):1283-1289.
- Lenters TR, Franta AK, Wolf FM, Leopold SS, Matsen FA 3rd. Arthroscopic compared with open repairs for recurrent anterior shoulder instability: a systematic review and meta-analysis of the literature. *J Bone Joint Surg Am*. 2007;89(2):244-254.
- Maffet MW, Gartsman GM, Moseley B. Superior labrum-biceps tendon complex lesions of the shoulder. *Am J Sports Med*. 1995;23(1):93-98.
- Mazzocca AD, Brown FM Jr, Carreira DS, Hayden J, Romeo AA. Arthroscopic anterior shoulder stabilization of collision and contact athletes. *Am J Sports Med*. 2005;33(1):52-60.
- Mueller MB, Fredrich HH, Steinhauser E, Schreiber U, Arians A, Imhoff AB. Biomechanical evaluation of different suture anchors for the stabilization of anterior labrum lesions. *Arthroscopy*. 2005;21(5):611-619.

24. Owens BD, Duffey ML, Nelson BJ, DeBerardino TM, Taylor DC, Mountcastle SB. The incidence and characteristics of shoulder instability at the United States Military Academy. *Am J Sports Med.* 2007;35(7):1168-1173.
25. Porcellini G, Paladini P, Campi F, Paganelli M. Shoulder instability and related rotator cuff tears: arthroscopic findings and treatment in patients aged 40 to 60 years. *Arthroscopy.* 2006;22(3):270-276.
26. Richards RR, An K-N, Bigliani LU, et al. A standardized method for the assessment of shoulder function. *J Shoulder Elbow Surg.* 1994;3:347-352.
27. Roberts SN, Taylor DE, Brown JN, Hayes MG, Saies A. Open and arthroscopic techniques for the treatment of traumatic anterior shoulder instability in Australian Rules football players. *J Shoulder Elbow Surg.* 1999;8(5):403-409.
28. Robinson CM, Howes J, Murdoch H, Will E, Graham C. Functional outcome and risk of recurrent instability after primary traumatic anterior shoulder dislocation in young patients. *J Bone Joint Surg Am.* 2006;88(11):2326-2336.
29. Robinson CM, Kelly M, Wakefield AE. Redislocation of the shoulder during the first six weeks after a primary anterior dislocation: risk factors and results of treatment. *J Bone Joint Surg Am.* 2002;84(9):1552-1559.
30. Rosenberg BN, Richmond JC, Levine WN. Long-term followup of Bankart reconstruction: incidence of late degenerative glenohumeral arthrosis. *Am J Sports Med.* 1995;23(5):538-544.
31. Rowe CR, Patel D, Southmayd WW. The Bankart procedure: a long-term end-result study. *J Bone Joint Surg Am.* 1978;60(1):1-16.
32. Scheibel M, Tsynman A, Magosch P, Schroeder RJ, Habermeyer P. Postoperative subscapularis muscle insufficiency after primary and revision open shoulder stabilization. *Am J Sports Med.* 2006;34(10):1586-1593.
33. Snyder SJ, Karzel RP, Del Pizzo W, Ferkel RD, Friedman MJ. SLAP lesions of the shoulder. *Arthroscopy.* 1990;6(4):274-279.
34. Sperber A, Hamberg P, Karlsson J, Sward L, Wredmark T. Comparison of an arthroscopic and an open procedure for posttraumatic instability of the shoulder: a prospective, randomized multicenter study. *J Shoulder Elbow Surg.* 2001;10(2):105-108.
35. Tischer T, Vogt S, Imhoff AB. Arthroscopic stabilization of the shoulder with suture anchors with special reference to the deep anterior-inferior portal (5.30 o'clock) [in German]. *Oper Orthop Traumatol.* 2007;19(2):133-154.
36. Yiannakopoulos CK, Mataragas E, Antonogiannakis E. A comparison of the spectrum of intra-articular lesions in acute and chronic anterior shoulder instability. *Arthroscopy.* 2007;23(9):985-990.