

# Author's response to the letter of the editor regarding the "Review of surgical techniques and guide for decision making in the treatment of benign parotid tumors"

Georgios Psychogios<sup>1,11</sup> · Christopher Bohr<sup>2</sup> · Jannis Constantinidis<sup>3</sup> · Martin Canis<sup>4</sup> · Vincent Vander Poorten<sup>5,11</sup>  
Jan Plzak<sup>6</sup> · Andreas Knopf<sup>7</sup> · Christian Betz<sup>8</sup> · Orlando Guntinas-Lichius<sup>9,11</sup> · Johannes Zenk<sup>10,11</sup>

Dear Editor,

We would like to thank Tretiakow and Skorek for their interesting comments. As we stated in our article, extracapsular dissection (ECD) is a surgical technique that has advantages and limitations and is only one of many options in benign parotid surgery [1]. We agree that main indications are parotid tumors located at the caudal part or the tail of the parotid gland (PG). Experienced surgeons can expand the indications to tumors of the cranial part of the PG as shown in Figures 2 and 5 of our manuscript [1].

Furthermore, we agree that pleomorphic adenoma (PLA) should be treated with extra caution. If PLA is preoperatively suspected, ECD can be applied, but surgeons have to make sure not to injure the capsule of the tumor and if possible, preserve some millimeters of healthy tissue around the tumor. If a surgeon is not confident with ECD, he or she should prefer (partial) superficial parotidectomy in such cases. Nevertheless, many studies have shown that at centers with high expertise in ECD, recurrence rates of PLA did not increase [2].

We disagree with Tretiakow and Skorek that MRI (including diffusion-weighted sequences) is superior to ultrasound in the diagnosis of parotid tumors. As we could show in previous studies, multimodal ultrasound with elastography is a very promising method to help differentiate between benign

✉ Georgios Psychogios  
gpsychogios@uoi.gr  
<http://www.msgs.international>  
  
Vincent Vander Poorten  
<http://www.msgs.international>  
  
Orlando Guntinas-Lichius  
<http://www.msgs.international>  
  
Johannes Zenk  
<http://www.msgs.international>

<sup>1</sup> Department of Otorhinolaryngology and Head and Neck Surgery, University Hospital Ioannina, Leof. Stavrou Niarchou, 455 00 Ioannina, Greece

<sup>2</sup> Department of Otorhinolaryngology and Head and Neck Surgery, University Hospital Regensburg, Franz-Josef-Strauss-Allee 11, D-93053 Regensburg, Germany

<sup>3</sup> 1st Department of ORL, Head and Neck Surgery, Aristotle University, AHEPA Hospital, Thessaloniki, Greece

<sup>4</sup> Department of Otorhinolaryngology and Head and Neck Surgery, LMU Klinikum, Marchioninstr. 15, 81377 Munich, Germany

<sup>5</sup> Otorhinolaryngology-Head and Neck Surgery and Department of Oncology, Section Head and Neck Oncology, University Hospitals Leuven, KU Leuven, Leuven, Belgium

<sup>6</sup> Department of Otorhinolaryngology and Head and Neck Surgery, 1st Faculty of Medicine, Charles University, Motol University Hospital, V Uvalu 84, 150 06 Prague 5, Czech Republic

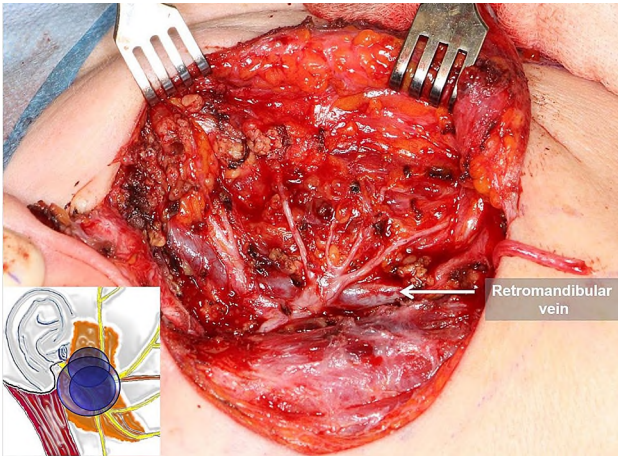
<sup>7</sup> Department of Otorhinolaryngology/Head and Neck Surgery, Faculty of Medicine, University of Freiburg, Freiburg, Germany

<sup>8</sup> Department of Otorhinolaryngology, Universitätsklinikum Hamburg-Eppendorf, Martinistr. 52, 20246 Hamburg, Germany

<sup>9</sup> Department of Otorhinolaryngology—Head and Neck, Surgery, Jena University Hospital, Jena, Germany

<sup>10</sup> Department of Otorhinolaryngology and Head and Neck Surgery, University Hospital Augsburg, Sauerbruchstraße 6, 86179 Augsburg, Germany

<sup>11</sup> Multidisciplinary Salivary Gland Society, Geneva, Switzerland



**Fig. 1** The correlation of the branches of the facial nerve to the retromandibular vein (RMV) can be seen. Graph showing typical indications of superficial parotidectomy (SP) and figure showing surgical site after SP of the right PG

and malignant PG tumors and cervical lymph nodes [3–5]. Usually, ultrasound is faster and easier to perform and is more widely available. Furthermore, ultrasound can be used to successfully correlate the PG tumor to the retromandibular vein and indirectly predict the relationship to the route of the facial nerve (Fig. 1) and, therefore, can greatly assist surgeons in choosing the most appropriate surgical technique [6]. The main advantage of MRI compared to ultrasound is the proper imaging of deep lobe PG tumors and tumors located behind the mandible. Admittedly, diffusion MRI seems to be promising and should be further investigated [7].

Finally, we agree that all parotid surgeons offering extracapsular dissection should be highly experienced in all surgical techniques of PG surgery (especially superficial and total parotidectomy) and be able to safely identify the main trunk of the facial nerve, otherwise wrong indications and increased complications are inevitable.

**Acknowledgements** All figures of the review article and this response article are from the personal archive of Prof. Psychogios and all graphs are made by himself.

**Funding** This work had no specific funding. The authors indicate that they have no financial disclosures.

## Compliance with ethical standards

**Conflict of interest** The authors declare that they have no conflict of interest.

## References

1. Psychogios G, et al (2020) Review of surgical techniques and guide for decision making in the treatment of benign parotid tumors. *Eur Arch Otorhinolaryngol*
2. Iro H, Zenk J (2014) Role of extracapsular dissection in surgical management of benign parotid tumors. *JAMA Otolaryngol Head Neck Surg* 140(8):768–769
3. Ruger H et al (2020) Multimodal ultrasound including virtual touch imaging quantification for differentiating cervical lymph nodes. *Ultrasound Med Biol* 46(10):2677–2682
4. Mansour N et al (2017) Multimodal ultrasonographic pathway of parotid gland lesions. *Ultraschall Med* 38(2):166–173
5. Klintworth N et al (2012) Sonoelastography of parotid gland tumours: initial experience and identification of characteristic patterns. *EurRadiol* 22(5):947–956
6. Psychogios G et al (2019) Ultrasound can help to indirectly predict contact of parotid tumors to the facial nerve, correct intraglandular localization, and appropriate surgical technique. *Head Neck* 41(9):3211–3218
7. Mikaszewski B et al (2020) Clinical and demographic data improve diagnostic accuracy of dynamic contrast-enhanced and diffusion-weighted MRI in differential diagnostics of parotid gland tumors. *Oral Oncol* 111:104932