

Pyoderma gangrenosum and concomitant hidradenitis suppurativa - rapid response to canakinumab (anti-IL-1 β)

Teresa Jaeger, Christian Andres, Martine Grosber, Michael Zirbs, Rüdiger Hein, Johannes Ring, Claudia Traidl-Hoffmann

Angaben zur Veröffentlichung / Publication details:

Jaeger, Teresa, Christian Andres, Martine Grosber, Michael Zirbs, Rüdiger Hein, Johannes Ring, and Claudia Traidl-Hoffmann. 2013. "Pyoderma gangrenosum and concomitant hidradenitis suppurativa - rapid response to canakinumab (anti-IL-1 β)." *European Journal of Dermatology* 23 (3): 408-10.
<https://doi.org/10.1684/ejd.2013.2018>.

Nutzungsbedingungen / Terms of use:

licgercopyright

Dieses Dokument wird unter folgenden Bedingungen zur Verfügung gestellt: / This document is made available under the following conditions:

Deutsches Urheberrecht

Weitere Informationen finden Sie unter: / For more information see:

<https://www.uni-augsburg.de/de/organisation/bibliothek/publizieren-zitieren-archivieren/publizieren>



Pyoderma gangrenosum and concomitant hidradenitis suppurativa – rapid response to canakinumab (anti-IL-1 β)

A classic ulcerative pyoderma gangrenosum (PG) lesion most commonly presents on the lower extremities as a painful nodule or pustule which evolves into an enlarging ulcer with a raised, undermined border. About 50% of patients with PG have associated systemic diseases e.g. inflammatory bowel disease (IBD) [1]. Diagnosis can be difficult and is made by excluding other causes of cutaneous ulcers through biopsy, culture and clinical appearance.

Hidradenitis suppurativa (HS) typically presents in the intertriginous sites, has no specific histologic findings (mixed inflammatory infiltrate including neutrophils) and therapy is often complex [2].

Currently there is no gold standard of treatment for PG. Systemic treatment options are corticosteroids, immunosuppressive drugs, TNF α receptor antagonists, intravenous

immunoglobulin, thalidomide, dapsone and ustekinumab [3, 4].

Since a significant contribution of IL-1 to the pathogenesis has been confirmed, PG and HS can be regarded as autoinflammatory diseases. Thus, the interleukin (IL)-1 receptor antagonist anakinra represents a therapeutic option in PG [5]. However, to our knowledge, there are no reports to date on canakinumab, a humanized mAb against IL-1 β .

A 27-year-old, obese, Caucasian male patient presented in our dermatology department. He complained about a two year history of erythematous, ulcerative skin lesions on the lower extremities (*figure 1A*). Additionally, moderate acne-like lesions were present in the axillary and inguinal region (*figure 1B*). There were no other comorbidities. A skin biopsy revealed perifolliculitis and neutrophils in the dermis, compatible with early stage PG (*figure 1C*). After excluding other causes of cutaneous ulcers, PG was recommended as the diagnosis. Initially, the patient was treated with systemic steroids (1 mg/kg KG), with poor response. Subsequently, he received immunosuppressive therapy with azathioprine (100 mg daily, for about one year) in combination with various local therapies/dressings. Under this therapy, a stable disease was achieved: the ulcers did not expand but no healing tendency was observed. Equally, acne inversa was therapy-refractory. At that point we decided to perform a systemic targeted monotherapy with canakinumab (anti-IL-1 β). Notably, after 4 injections of canakinumab (150 mg every 3-6 weeks, total 8 injections) combined with local therapy with tacrolimus 0.1%, the ulcers healed in 4 months with a complete remission after 1 year (*figure 1A*).

PG and HS are regarded as autoinflammatory diseases, in which a significant contribution of IL-1 to the pathogenesis has been confirmed [6]. A macromolecular complex, the

inflammasome, cleaves IL-1 from its biologically inactive precursor form [7].

The coexistence of HS and PG in the same patient is rarely reported. Hsiao *et al.* gave a short review (31 cases), listing possible therapy options. However, canakinumab (anti-IL1 β) has not been mentioned so far, only anakinra (IL-1Ra) has been applied [8]. PG and HS can also be features of the Pyoderma gangrenosum, Acne, Pyogenic Arthritis syndrome (PAPA), which is characterized by an overexpression of IL-1 β . Successful treatment with anakinra has been described [5]. The clinical triad of pyoderma gangrenosum, acne vulgaris, and suppurative hidradenitis represents a new disease entity within the spectrum of autoinflammatory syndromes, similar to PAPA. For this disease, Braun Falco M *et al.* propose the acronym PASH syndrome, which may also respond to IL-1 blockade with anakinra [9]. So in PG refractory to corticosteroids, immunosuppressives and anti TNF α , anti-IL-1 therapy seems to be a promising modality.

Anakinra is a recombinant non-glycosylated homologue of human IL-1Ra that competitively inhibits binding of the key pro-inflammatory cytokines IL-1 α and IL-1 β . Canakinumab represents a humanized mAb towards IL-1 β . It is applied subcutaneously once every 1-2 months. Anakinra, a recombinant IL-1 receptor antagonist, has to be given daily [10]. IL-1 targeted therapy with riloncept, a recombinant fusion protein including IL-1 receptor and IL-1 receptor accessory protein (IL-1 TRAP), requires weekly injections [10]. Thus, canakinumab represents an advantage for patients with PG, especially with respect to the positive pathergy phenomenon.

We here observed a very rapid response of therapy-refractory PG to canakinumab (anti IL-1 β). HS healed after the first injection, ulcers within 4 months, with complete remission after 1 year.

To our knowledge this is the first case of PG with concomitant HS successfully treated with canakinumab. Further controlled studies in PG and HS patients should be performed to evaluate the efficiency of anti-IL-1 β in these diseases. ■

Disclosure. *Acknowledgment:* Supported by Christine Kühne – Center for Allergy Research and Education of (CK-Care). *Financial support:* none. *Conflict of interest:* none.

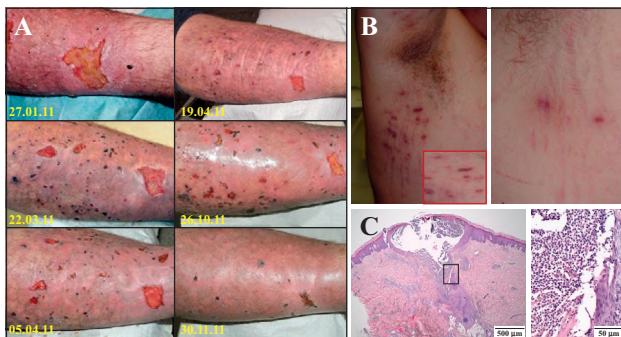


Figure 1. A: Clinical inspection (before and after anti-IL-1 β therapy). The physical examination revealed irregular ulcers (about 7 cm \times 9 cm) with elevated margins, blue undermined borders and a surrounding rim of erythema on the lower extremities. Multiple similar smaller ulcers were seen in the surrounding areas. Skin eruptions improved rapidly after injections of canakinumab once every 3-6 weeks. The first picture was taken 4 weeks after the first injection of canakinumab. **B) Clinical inspection (before and after anti-IL-1 β therapy).** In this case we could see a very rapid response to canakinumab. The moderate hidradenitis suppurativa healed after the first injection of canakinumab. **C) Histopathology** The skin biopsy showed perifolliculitis and fulminant folliculitis with neutrophilic inflammation in the dermis, compatible with the early stage of pyoderma gangraenosum. There is no evidence for bacteria or fungi.

¹ Department of Dermatology and Allergy Biederstein, Technische Universität München, Biedersteiner Str. 29, 80802 München, Germany

² Center of Allergy and Environment (ZAUM), Technische Universität München and Helmholtz Center, Munich, Germany <Traidl-Hoffmann@lrz.tu-muenchen.de>

Teresa JAEGER^{1,2}
Christian ANDRES¹
Martine GROSBER¹
Michael ZIRBS¹
Rüdiger HEIN¹
Johannes RING¹
Claudia TRAILD-HOFFMANN^{1,2}

1. Al Ghazal P, Körber A, Klode J, Dissemond J. Investigation of new co-factors in 49 patients with pyoderma gangrenosum. *J Dtsch Dermatol Ges* 2011; 10: 251-7.

2. Jemec GB, Hansen U. Histology of hidradenitis suppurativa. *J Am Acad Dermatol* 1996; 34: 994-9.

- 3.** Miller J, Yentzer BA, Clark A, Jorizzo JL, Feldman SR. Pyoderma gangrenosum: a review and update on new therapies. *J Am Acad Dermatol* 2010; 62: 646-54.
- 4.** Guenova E, Teske A, Fehrenbacher B, et al. Interleukin 23 Expression in Pyoderma Gangrenosum and Targeted Therapy With Ustekinumab. *Arch Dermatol* 2011; 147: 1203-5.
- 5.** Brenner M, Ruzicka T, Plewig G, Thomas P, Herzer P. Targeted treatment of pyoderma gangrenosum in PAPA (pyogenic arthritis, pyoderma gangrenosum and acne) syndrome with the recombinant human interleukin-1 receptor antagonist anakinra. *Br J Dermatol* 2009; 161: 1199-201.
- 6.** Löhner R, Eming R, Wolfrum N, Krieg T, Eming SA. Autoinflammatory diseases as cause of wound healing defects. *Hautarzt* 2011; 62: 524-33.
- 7.** Goldbach-Mansky R, Kastner DL. Autoinflammation: the prominent role of IL-1 in monogenic autoinflammatory diseases and implications for common illnesses. *J Allergy Clin Immunol* 2009 Dec; 124: 1141-9.
- 8.** Hsiao JL, Antaya RJ, Berger T, Maurer T, Shinkai K, Leslie KS. Hidradenitis suppurativa and concomitant pyoderma gangrenosum: a case series and literature review. *Arch Dermatol* 2010 Nov; 146: 1265-70.
- 9.** Braun-Falco M, Kovnerysty O, Lohse P, Ruzicka T. Pyoderma gangrenosum, acne, and suppurative hidradenitis (PASH) - a new autoinflammatory syndrome distinct from PAPA syndrome. *J Am Acad Dermatol* 2011; 66: 409-15.
- 10.** Hoffman HM. Therapy of autoinflammatory syndromes. *J Allergy Clin Immunol* 2009; 124: 1129-38.