

## **Optic nerve sheath diameter assessment by neurosonology: a review of methodologic discrepancies**

**Raoul R. F. Stevens, Erik D. Gommer, Marcel J.H. Aries, Michael Ertl, Werner H. Mess, Wouter Huberts, Tammo Delhaas**

### **Angaben zur Veröffentlichung / Publication details:**

Stevens, Raoul R. F., Erik D. Gommer, Marcel J.H. Aries, Michael Ertl, Werner H. Mess, Wouter Huberts, and Tammo Delhaas. 2021. "Optic nerve sheath diameter assessment by neurosonology: a review of methodologic discrepancies." *Journal of Neuroimaging* 31 (5): 814-25. <https://doi.org/10.1111/jon.12906>.



## VIEWS AND REVIEWS

# Optic nerve sheath diameter assessment by neurosonology: A review of methodologic discrepancies

Raoul R. F. Stevens<sup>1</sup>  | Erik D. Gommer<sup>2</sup>  | Marcel J.H. Aries<sup>3</sup>  | Michael Ertl<sup>4</sup>  |  
 Werner H. Mess<sup>2</sup>  | Wouter Huberts<sup>5,6</sup>  | Tammo Delhaas<sup>5</sup> 

<sup>1</sup> Department of Biomedical Engineering, MHeNS School for Mental Health and Neuroscience, Maastricht University, Maastricht, Netherlands

<sup>2</sup> Department of Clinical Neurophysiology, Maastricht University Medical Centre, Maastricht, Netherlands

<sup>3</sup> Department of Intensive Care, MHeNS School for Mental Health and Neuroscience, Maastricht University Medical Centre, Maastricht, Netherlands

<sup>4</sup> Department of Neurology and Clinical Neurophysiology, University Hospital Augsburg, Augsburg, Germany

<sup>5</sup> Department of Biomedical Engineering, CARIM School for Cardiovascular Diseases, Maastricht University, Maastricht, Netherlands

<sup>6</sup> Department of Biomedical Engineering, Eindhoven University of Technology, Eindhoven, Netherlands

### Correspondence

Tammo Delhaas, Department of Biomedical Engineering, CARIM School for Cardiovascular Diseases, Maastricht University, Universiteitssingel 50, room 3.366, 6229 ER Maastricht, The Netherlands.  
 Email: [tammo.delhaas@maastrichtuniversity.nl](mailto:tammo.delhaas@maastrichtuniversity.nl)

[Correction added on 21 February 2022, after first online publication: The copyright line was changed.]

### Abstract

**Background and Purpose:** Reported cutoff values of the optic nerve sheath diameter (ONSD) for the diagnosis of elevated intracranial pressure (ICP) are inconsistent. This hampers ONSD as a possible noninvasive bedside monitoring tool for ICP. Because the influence of methodological differences on variations in cutoff values is unknown, we performed a narrative review to identify discrepancies in ONSD assessment methodologies and to investigate their effect on reported ONSD values.

**Methods:** We used a structured and quantitative approach in which each ONSD methodology found in the reviewed articles was categorized based on the characteristic appearance of the ultrasound images and ultrasound marker placement. Subsequently, we investigated the influence of the different methodologies on ONSD values by organizing the ONSDs with respect to these categories.

**Results:** In a total of 63 eligible articles, we could determine the applied ONSD assessment methodology. Reported ultrasound images either showed the optic nerve and its sheath as a dark region with hyperechoic striped band at its edges or as a single dark region surrounded by lighter retrobulbar fat. Four different ultrasound marker positions were used to delineate the optic nerve sheath, which resulted in different ONSD values and more importantly, different sensitivities to changes in ICP.

**Conclusions:** Based on our observations, we recommend to place ultrasound markers at the outer edges of the hyperechoic striped bands or at the transitions from the single dark region to the hyperechoic retrobulbar fat because these locations yielded the highest sensitivity of ONSD measurements for increased ICP.

### KEYWORDS

intracranial pressure, optic nerve sheath diameter, review, ultrasound

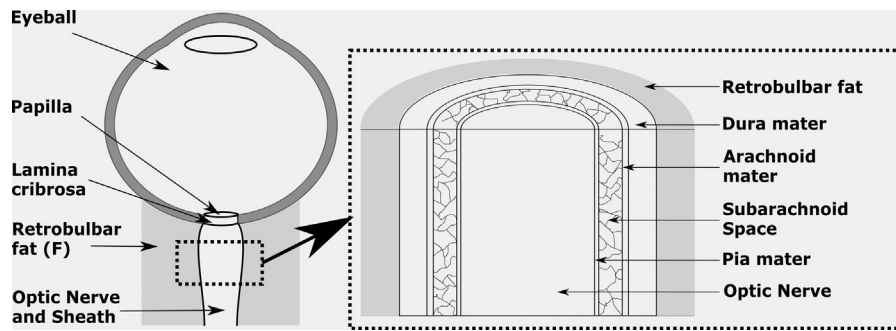
## INTRODUCTION

The subarachnoid space, located between the optic nerve and the optic nerve sheath, contains cerebrospinal fluid. When the hydrostatic intracranial pressure (ICP) increases, the optic nerve sheath can expand. Because this sheath expansion is considered to be a surrogate

parameter for noninvasive ICP estimation<sup>1,2</sup> the optic nerve sheath diameter (ONSD) is often measured in clinical practice. Although intra- and interobserver agreement of ONSD estimation is high within individual studies,<sup>3,4</sup> ONSD cutoff values for the diagnosis of elevated ICP (>15 mmHg) vary between studies<sup>5-7</sup> and thereby limit the application of ONSD assessment as a noninvasive surrogate marker for ICP

This is an open access article under the terms of the [Creative Commons Attribution-NonCommercial](https://creativecommons.org/licenses/by-nc/4.0/) License, which permits use, distribution and reproduction in any medium, provided the original work is properly cited and is not used for commercial purposes.

© 2021 The Authors. *Journal of Neuroimaging* published by Wiley Periodicals LLC on behalf of American Society of Neuroimaging



**FIGURE 1** Left: Schematic overview of the anatomy of the eyeball and optic nerve. The nerve and its sheath are surrounded by retrobulbar fat tissue. Right: A detailed drawing of the different layers of the optic nerve sheath. The nerve is surrounded by the pia mater, subarachnoid space, arachnoid mater, and the dura mater

monitoring. It is hence of utmost importance to identify and resolve sources of these variations in cutoff values. Although differences between patient populations studied might explain part of these variations, the role of discrepancies in ONSD assessment methodologies still needs to be determined. Methodological aspects, such as ultrasound machine settings, transducer placement, and ONSD delineation, probably differ between clinical centers and research groups and might hence contribute to the diversity in ONSD cutoff values.

In this study, we perform a narrative literature review in which we identify and categorize the reported ONSD assessment methodologies and investigate the effect of differences found on the measured ONSD values. Hereby, we focus on (1) the characteristic appearances of reported ultrasound images, (2) how the visible structures are interpreted with respect to the retrobulbar anatomy, (3) how these interpretations guide placement of the ultrasound markers used to calculate the ONSD, and (4) the relationship between ONSD values and assessment methodology.

## METHODS

### Eligibility criteria and search strategy

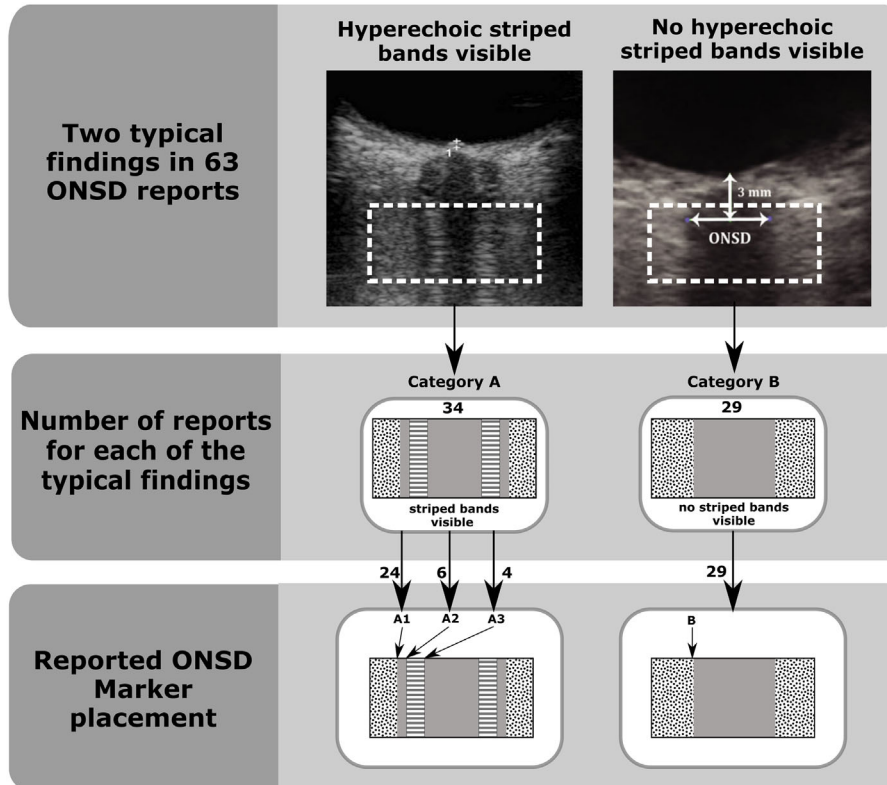
In December 2019, a PubMed search was performed using the following search strategy: (“optic nerve sheath” AND “diameter” [(Medical Subject Headings) MeSH Terms]) AND (“elevated icp intracranial pressure” [MeSH Terms]). Titles and abstracts of the search results were evaluated and articles were selected for full text review based on the following criteria: (1) articles were written in English, (2) ONSD was manually assessed from ultrasound images, and (3) articles did not involve fetus, animal, or in vitro studies. Consecutive full text review was performed to select articles according to the following criteria: (4) articles did report ultrasound images, (5) reported ultrasound images were of such quality that the borders between darker and lighter regions could be distinguished, (6) ultrasound markers were visible within the images, and (7) there was no ambiguity in reported ultrasound images with respect to patterns of lighter and darker regions. Criteria 5 and 6 were applied because our interest is in the specific characteristics of the ultrasound images, that is, the lighter and darker regions of the images, the structural interpretation of

these regions, and the corresponding ultrasound marker placement. Images of inferior quality would prevent us from extracting this information from the articles. We applied criterion 7 because articles with ambiguous images would prevent us from assigning them to one of the branches in the structured and quantitative approach that was applied to analyze the selected articles and will be described in the “Structured and quantitative approach” section.

### Optic nerve anatomy

To facilitate referring to different retrobulbar structures in the remainder of the manuscript, we first describe the anatomy of the optic nerve and the optic nerve sheath (see Figure 1). The optic nerve runs from the eyeball to the chiasm and can be divided into four parts, that is, an intraocular part (1 mm long), intra-orbital part (30 mm long), intracanalicular part (6–10 mm long), and intracranial part (10–16 mm long).<sup>8</sup> Nerve fibers originate from the retinal ganglion cells and join at the optic disc, which is commonly referred to as “the blind spot.” From here, the bundled unmyelinated optic nerve fibers run approximately 1 mm through the globe before penetrating the sclera through the lamina cribrosa. Once the optic nerve enters the intra-orbital space, it is surrounded by the optic nerve sheath. Besides the optic nerve and its sheath, the region immediately behind the globe also contains extraocular muscles and fat tissue.

The optic nerve itself has a diameter of approximately 3 mm, whereas the optic nerve sheath has a thickness of approximately 1 mm.<sup>9</sup> From in to out, the sheath consists of the pia mater, the subarachnoid space, the arachnoid mater, and the dura mater.<sup>10</sup> The pia mater and the arachnoid mater have a thickness of 0.09–0.15 mm,<sup>11,12</sup> whereas the subarachnoid space and the dura have a thickness of 0.1–0.29 and 0.3–0.5 mm,<sup>9,11,12</sup> respectively. The subarachnoid space features a complex structure formed by trabeculae, septa, and pillars immersed in the cerebral spinal fluid. The composition of these structures within the subarachnoid space changes along the nerve.<sup>13</sup> The anterior part of the subarachnoid space mainly contains trabeculae, which are 5–7  $\mu\text{m}$  in diameter. The midsection of the sheath displays both septa that divide this space into small communicating chambers, as well as pillars with a diameter of 10–30  $\mu\text{m}$ .<sup>13</sup> In the posterior part, where the sheath crosses the optic canal, both pillars and trabeculae are present.



**FIGURE 2** Structured and Quantitative approach used to label the optic nerve sheath diameter (ONSD) methodologies based on the ultrasound image characteristics and marker placement. Top: Two types of typical findings in ONSD reports, that is, ultrasound images show hyperechoic striped bands in between the hyperechoic retrobulbar fat, and ultrasound images show no hyperechoic striped bands. Ultrasound images adopted from refs. 25 and 26. Middle: Characterization of the typical findings in to Category A and Category B. Schematic representations of the ultrasound images are depicted in the figures given within each category. Bottom: Standardized marker positions based on the transitions from lighter to darker regions

## Structured and quantitative approach

To investigate the effect of different methodologies on ONSD values, we assigned a “code” to the ONSD assessment methodology used in each reviewed article. This classification was based on the criteria discussed below.

## Characteristics of retrobulbar ultrasound images

Two groups of retrobulbar ultrasound images with different patterns of echoic characteristics were found in the reviewed articles. Both groups clearly showed a dark (hypoechoic) circular structure representing the eyeball. In addition, lighter (hyperechoic) structures were present behind the globe representing the retrobulbar fat and ocular muscles. The optic nerve was represented by a linear dark structure perpendicular to the globe. Although one group of images only showed a single dark linear structure surrounded by lighter retrobulbar fat behind the eyeball, the other group displayed two lighter (hyperechoic) striped “bands” within this dark region (Figure 2, top panel).

In order to denote these echoic appearances of the reported ultrasound images in our quantitative analysis, we labeled images with

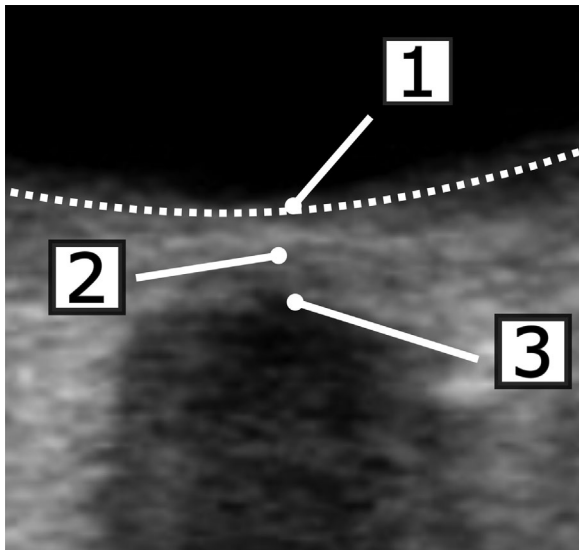
striped bands “Category A,” and images without these dark bands “Category B” (Figure 2, mid panel).

## Marker placement for sheath assessment

To quantify placement of ultrasound markers used to delineate the optic nerve sheath, possible locations of ultrasound markers were labeled. In the presence of hyperechoic striped bands, possible marker positions from outside to inside were located at (A1) transition from hyperechoic retrobulbar fat region to hypoechoic line, (A2) transition from hypoechoic line to hyperechoic striped band, and (A3) transition from hyperechoic striped band to hypoechoic region. In images without striped bands, marker placement is only possible at the transition from the hyperechoic region to the hypoechoic region and this location was denoted with letter B.

## Marker placement for depth assessment

Three possible positions for ultrasound depth markers were defined and used to label the depth marker placement within the articles



**FIGURE 3** Definition of the three depth marker positions found in literature: (1) at the level of the retina, (2) at the level of the lamina cribrosa, and (3) at the top of the hypoechoic (black) optic nerve. The white dotted line denotes the retina

(Figure 3): (1) location where imaginary nerve midline intersects contour of the retina, (2) hyperechoic reflection corresponding to the lamina cribrosa, and (3) top of the dark linear structure corresponding to the optic nerve. In case no marker was placed within the reported image, the article was labeled with “marker position not presented.” In addition, the terminology used to describe the chosen anatomical landmark was extracted. If no landmark was specified, it was denoted with “not reported.”

### Discrepancy between reported and performed methodology

Besides the categorization of the performed ONSD assessment methodology (based on the marker position in the exemplary ultrasound images), we also assessed if the performed ONSD assessment corresponded with the reported ONSD assessment methodology (as described in the method sections of the reviewed articles).

### Structural interpretation

We also classified how echoic properties of the optic nerve and its sheath were described and how structures as seen on the ultrasound images were interpreted. Moreover, we examined if the interpretation of the ultrasound images was similar across studies.

### Ultrasound settings

Transducer frequency, imaging plane (transverse or sagittal), and mechanical index (MI) were extracted from the articles to investigate

whether image acquisition characteristics were related to the ONSD values.

### Influence of methodology on measured ONSD values

Clinical relevance of an ONSD methodology depends on its ability to detect changes in ICP. Therefore, we assessed for each of the different ONSD measurement methodologies how the corresponding ONSD values changed with increasing ICP.

ONSD values for subjects with normal (low) and with pathologically elevated (high) ICPs were extracted from the selected articles. It is to be noted that low-ICP subjects were reported in the reviewed articles as healthy persons, as age-matched controls, or as patients with normal ICP ( $ICP_{norm}$ ).

Extracted ONSD values were separated based on the assessment methodology described in Section C, that is, A1, A2, A3, and B (see Figure 2). ONSD values obtained with the different methods were compared within each of the four different subject groups. Subsequently, differences in ONSD values between these subject groups were investigated for each of the four methodologies to assess their sensitivity for ICP elevation.

We also investigated the influence of variations in ultrasound depth marker placement on the ONSD values.

## RESULTS

### Search results

We identified 191 citations based on our PubMed search criteria. After screening the abstracts of these studies, 67 studies were excluded because they involved animal, fetus, or in vitro studies ( $n = 8$ ); assessed ONSD from CT/MRI images ( $n = 21$ ); were comments on other articles ( $n = 23$ ); were not written in English ( $n = 8$ ); were not available ( $n = 3$ ); or other ( $n = 4$ ). The remaining 124 articles were selected for full text review. From this set, an additional 30 articles were excluded because they assessed ONSD from MRI ( $n = 1$ ), were comments on other articles ( $n = 1$ ), were not written in English ( $n = 1$ ), were not available ( $n = 1$ ), were review articles without an ONSD methodology section ( $n = 17$ ), showed unclear exemplary ultrasound images ( $n = 3$ ), showed no ultrasound markers within the image ( $n = 2$ ), showed ultrasound images with conflicting characteristic appearance ( $n = 2$ ), or other ( $n = 2$ ). After omitting all papers that did not present any ultrasound image at all ( $n = 31$ ), a total of 63 articles remained for analysis in our review (Table 2).

### Structured and quantitative approach

#### Image characteristics

The number of articles corresponding to each of the typical ultrasound findings is indicated in the middle of Figure 2. Approximately half



( $n = 34$ ) of the articles showed images corresponding to Category A, that is, depicting hyperechoic striped bands within the hypoechoic region between the retrobulbar fat. The other half ( $n = 29$ ) reported images corresponding to Category B displaying no striped bands in the dark region between the retrobulbar fat.

### Marker placement for sheath assessment

The marker position for the sheath delineation (A1, A2, A3, and B) was determined in all 63 articles (Figure 2). In the majority of articles within Category A, the marker was placed at the most outer transition from hyperechoic to the hypoechoic region, that is, Location A1. For the articles showing images corresponding to Category B, the marker was by definition set at position B.

### Marker placement for depth assessment

A total of 60 out of 63 articles reported the depth at which the ONSD was determined. Although all of these 60 articles reported that the ONSD was determined 3 mm posterior to an anatomical landmark, we encountered three different anatomical landmark positions for which nine different names were used with no clear distinction between them.

### Discrepancy between reported and performed methodology

In 22 out of 63 articles, no description of the ONSD assessment methodology was given. In addition, 17 articles provided a description of the ultrasound marker placement that was inconclusive or cited (multiple) other studies in which the methodological approach was inconclusive. This made it impossible in these 17 articles to compare the textual method description with the methodology depicted in the provided ultrasound images. In contrast, a description of the ONSD assessment could be determined in 24 articles, either directly from the reviewed paper or via the provided references. Out of these 24 papers, only two papers showed a “mismatch” between the description of the ultrasound marker placement and the placement of the markers in the provided ultrasound images.

### Structural interpretation

Detailed perceptions about the echogenic properties of the different retrobulbar structures and the corresponding structural interpretations of the ultrasound images were found in eight articles. Although all eight articles stated that the optic nerve does not reflect ultrasound waves and appears as a dark structure radiating away from the globe, the opinions on the echoic properties of the different layers of the optic

nerve sheath differed. Based on the latter differences, the structural interpretations could be divided into two groups (see Figure 4).

In the first interpretation, reported in six articles,<sup>14–19</sup> it was assumed that the pia mater and the dura mater do not reflect ultrasound waves and that the subarachnoid space and the retrobulbar fat are hyperechoic. Hence, the pia mater was thought to appear as a dark structure fused with the also dark optic nerve, the subarachnoid space was appointed to the two hyperechoic striped bands, and the dura mater was thought to appear as a dark line in-between the white retrobulbar fat and the hyperechoic striped bands.

In the second interpretation, described in two articles,<sup>1,20</sup> it was assumed that the subarachnoid space does not reflect ultrasound waves and that the pia mater, the dura mater, and the retrobulbar fat are hyperechoic. Hence, it was stated that the pia mater corresponds with the hyperechoic striped bands present within the dark region and that the subarachnoid space is represented by the thin hypoechoic lines in between the striped bands and the surrounding white tissue. Moreover, the dura mater and retrobulbar fat are thought to cause acoustic reflections and therefore appear as hyperechoic structures that cannot be distinguished from each other.

### Ultrasound settings

#### Transducer frequency

A total of 60 out of 63 articles did report the transducers used. Although all transducers were linear, their frequencies ranged from 3 to 25 MHz, with 7.5 MHz being the most used frequency ( $n = 13$ ).

#### Mechanical index

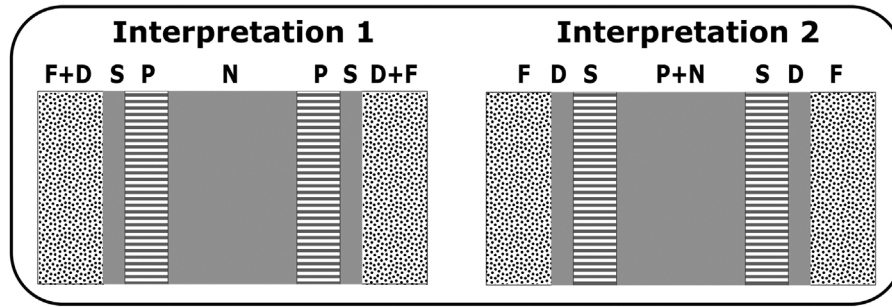
MI settings were reported in 19 out of 63 articles. Values lower than 0.3 were reported in 13 articles, the “As Low As Reasonable Achievable” (ALARA) principle was reported in five articles, whereas one article reported to have used an MI that was “low.”

#### Imaging plane

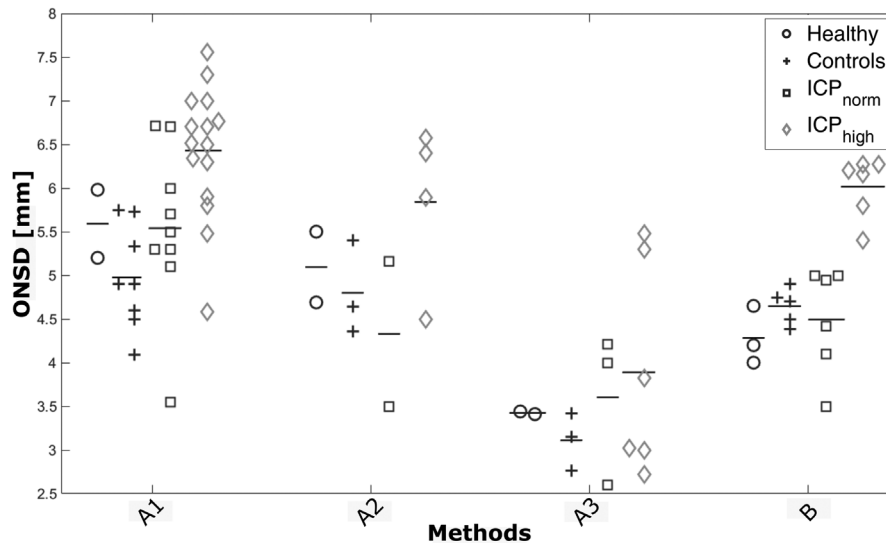
The imaging plane was reported in 49 out of 63 articles. In the majority of cases ( $n = 40$ ), a transverse plane was applied, either solely ( $n = 37$ ) or in combination with the sagittal plane ( $n = 3$ ). Nine studies reported on solely using the sagittal plane.

### Relation between ultrasound settings and image characteristics

Distributions of transducer frequencies and imaging planes were similar for articles appointed to Category A and articles appointed to



**FIGURE 4** The two different structural interpretations of ultrasound images found in literature. The darker and lighter regions within the schematic depictions of the ultrasound images are labeled with optic nerve (N), pia mater (P), subarachnoid space (S), dura mater (D), and retrobulbar fat tissue (F) following the description of the echoic fingerprint of the optic nerve and its sheath as described in literature



**FIGURE 5** Optic nerve sheath diameter (ONSD) values for healthy people, age-matched controls, patients with Normal intracranial pressure ( $ICP_{norm}$ ), and elevated intracranial pressure ( $ICP_{high}$ ) reported by the reviewed articles. The ONSD values are classified into assessment Methodologies A1, A2, A3, or B. The lines denote the mean values for each assessment methodology

Category B indicating that the presence of hyperechoic striped bands is not related to transducer frequency or image plane used.

### Influence of methodology on the ONSD

ONSD values for the four subject groups are plotted for each assessment method (A1, A2, A3, and B) in Figure 5. In addition, mean ONSD values per assessment method for each of the four subject groups are given in Table 1. Assuming that both the healthy group and the age-matched control group have normal ICPs, we pooled the ONSD values of both groups because only a few observations were available for the healthy population. Moreover, Table 1 shows mean differences between ONSD values of the various subject groups.

From Figure 5 and Table 1, the following trend can be observed: averaged over the four subject groups, ONSD values determined with Method A1 are 0.67 (0.2–1.2) mm larger than ONSD values determined

with Method A2. In turn, these A2-derived ONSD values are 1.43 (0.7–1.9) mm larger than the ONSD values obtained with A3. The ONSD values determined with Method B are similar to the values obtained with Method A2.

It is evident from Table 1 that the difference in ONSD values between patients with  $ICP_{norm}$  ( $n = 21$ ) and patients with  $ICP_{high}$  ( $n = 31$ ) is on average at least three times larger for Methods A1, A2, and B in comparison with Method A3, that is, 0.9, 1.5, 1.5, and 0.3 mm, respectively.

We did not find differences in ONSD values due to variations in depth marker positioning.

### DISCUSSION

We performed a narrative literature review to identify possible methodological differences in ONSD determination by means of

**TABLE 1** Optic nerve sheath diameters (ONSDs) categorized in study population and methodologies used to determine ONSDs

Population	Methodological categories			
	A1(n = 10;10;15)	A2(n = 6;2;4)	A3(n = 5;3;6)	B(n = 8;6;6)
Healthy and controls(H + C)	5.1	4.9	3.2	4.5
Normal ICP(ICP <sub>norm</sub> )	5.5	4.3	3.6	4.5
Elevated ICP(ICP <sub>high</sub> )	6.4	5.8	3.9	6.0
ICP <sub>norm</sub> - (H + C)	0.4	0.6	0.4	0
ICP <sub>high</sub> - (H + C)	1.3	0.9	0.7	1.5
ICP <sub>high</sub> - ICP <sub>norm</sub>	0.9	1.5	0.3	1.5

Note: Upper part—mean ONSDs categorized in study population and methodologies. The study population is divided into Healthy and controls, Normal intracranial pressure (ICP), and Elevated ICP, which are denoted by H + C, ICP<sub>norm</sub>, and ICP<sub>high</sub>, respectively. The methodologies used to determine the ONSDs are labeled as either A1, A2, A3, or B. Moreover, the number of ONSD values (n) is shown between brackets. Lower part—the difference in ONSDs between study populations for each of the methodologies (bottom).

ultrasound and to evaluate whether such differences affect the ONSD values within and between groups of patients with normal and pathologically elevated ICP. Hereto, we used a structured and quantitative approach to label the different ONSD methods and to link the reported ONSD values to these methods.

## Major findings

We identified four different ultrasound marker positions used to measure the ONSD, which resulted in varying ONSD values. Moreover, not all marker positions were equally sensitive to changes in ICP between subjects with elevated and those with normal ICP. Three of the marker positions were located within images with hyperechoic striped bands (ie, A1, A2, and A3), whereas the other position was pinpointed in images without hyperechoic bands (ie, B). The three marker positions identified within images with striped bands resulted in different ONSD values. Placing the markers at the transition from the hyperechoic retrobulbar fat to the dark region behind the globe in both image types (respectively, A1 and B) did on average not yield similar ONSD values. However, ONSD values obtained when ultrasound markers were placed at the outer edges of the striped bands (A2) were comparable to the ones derived with marker location B.

Clinically most interesting is the ability of the different methods to distinguish between patients with ICP<sub>norm</sub> and patients with ICP<sub>high</sub>. Our results showed that placement of the markers at the most inner edges of the hyperechoic striped bands (A3) was far less sensitive to changes in ICP than the other marker positions.

Besides the four different ultrasound marker positions within the two types of ultrasound images, we also encountered poor reporting of ONSD methodologies within a large portion of the analyzed articles as well as discrepancies in ONSD assessment methodologies (vide infra). Moreover, a detailed interpretation of the echoic signature of the optic nerve sheath was only reported in eight out of the 63 articles. Within these eight articles, two different, very conflicting interpretations of the echoic signature were found.

Anatomical landmarks used to calculate the ONSD assessment depth also varied between studies, resulting in different depth marker positions. Moreover, the terminology used to describe these landmarks was inconsistent and identical anatomical terms were sometimes used to describe different landmarks.

Ultrasound transducer frequencies were reported in almost every article and their range varied widely. Reported imaging planes also varied between studies, with studies using only a transverse plane or both the transverse and sagittal plane, whereas one third of the articles did not report the imaging plane at all.

## Considerations

Differences in ultrasound marker placement between studies have already been observed,<sup>21</sup> and the lack of agreement on the echoic signature of the optic nerve sheath is most likely the cause for these variations in ultrasound marker placement. Although there is no ambiguity that the optic nerve is represented by the hypoechoic longitudinal structure, the appearance of the pia mater, the subarachnoid space, and the dura mater seems to be much less agreed upon, which becomes apparent from the much larger heterogeneity in ONSD values compared to optic nerve diameter values presented in the meta-analysis of Schroeder et al.<sup>21</sup> Studies of Topcuoglu et al.<sup>20</sup> and Geeraerts et al.<sup>1</sup> dedicate the hyperechoic striped bands to the pia mater. Pichamuthu et al.,<sup>7</sup> on the other hand, interpret the striped bands as being both the pia and dura mater, with the subarachnoid space only appearing in the middle of these bands in patients with elevated ICP. Others assume that these bands represent the subarachnoid space<sup>14,15,18,21,22</sup> that reflects ultrasound waves because of the complex structure of trabeculae and pillars.<sup>23</sup> A study of Steinborn et al.<sup>15</sup> even describes the formation of a cyst like structure within the subarachnoid space in patients with elevated ICP due to the stretching of the trabeculae. Another study reports that these striped bands are only visible in patients with elevated ICP,<sup>24</sup> indicating that these bands represent the subarachnoid space and that these bands only become apparent on ultrasound images when the subarachnoid space is enlarged.

**TABLE 2** Overview of the 63 articles that were included in our analysis

#	Citation
1	Ballantyne J, Hollman AS, Hamilton R, et al. Transorbital optic nerve sheath ultrasonography in normal children. <i>Clin Radiol</i> 1999;54:740-2.
2	Bäuerle J, Nedelmann M, Bauerle J, Nedelmann M, Bäuerle J, Nedelmann M. Sonographic assessment of the optic nerve sheath in idiopathic intracranial hypertension. <i>J Neurol</i> 2011;258:2014-9.
3	Beare NAV, Kampondeni S, Glover SJ, et al. Detection of raised intracranial pressure by ultrasound measurement of optic nerve sheath diameter in African children. <i>Trop Med Int Heal</i> 2008;13:1400-4.
4	Bergmann KR, Milner DM, Voulgaropoulos C, Cutler GJ, Kharbanda AB. Optic nerve sheath diameter measurement during diabetic ketoacidosis: a pilot study. <i>West J Emerg Med</i> 2016;17:531-41.
5	Betcher J, Becker TK, Stoyanoff P, Cranford J, Theyyuni N. Military trainees can accurately measure optic nerve sheath diameter after a brief training session. <i>Mil Med Res</i> 2018;5:42.
6	Blaivas M, Theodoro D, Sierzenski PR. Elevated intracranial pressure detected by bedside emergency ultrasonography of the optic nerve sheath. <i>Acad Emerg Med</i> 2003;10:376-81.
7	Bolesch S, von Wegner F, Senft C, Lorenz MW. Transcranial ultrasound to detect elevated intracranial pressure: comparison of septum pellucidum undulations and optic nerve sheath diameter. <i>Ultrasound Med Biol</i> 2015;41:1233-40.
8	Chen Q, Chen W, Wang M, et al. High-resolution transbulbar ultrasonography helping differentiate intracranial hypertension in bilateral optic disc oedema patients. <i>Acta Ophthalmol</i> 2017;95:e481-e5.
9	Choi S-HH, Min K-TT, Park E-KK, Kim M-SS, Jung J-HH, Kim H. Ultrasonography of the optic nerve sheath to assess intracranial pressure changes after ventriculo-peritoneal shunt surgery in children with hydrocephalus: a prospective observational study. <i>Anaesthesia</i> 2015;70:1268-73.
10	del Saz-Saucedo P, Redondo-Gonzalez O, Mateu-Mateu A, Huertas-Arroyo R, Garcia-Ruiz R, Botia-Paniagua E. Sonographic assessment of the optic nerve sheath diameter in the diagnosis of idiopathic intracranial hypertension. <i>J Neurol Sci</i> 2016;361:122-7.
11	Dinsmore M, Han JS, Fisher JA, Chan VWSS, Venkatraghavan L. Effects of acute controlled changes in end-tidal carbon dioxide on the diameter of the optic nerve sheath: a transorbital ultrasonographic study in healthy volunteers. <i>Anaesthesia</i> 2017;72:618-23.
12	Driessen C, Bannink N, Lequin M, et al. Are ultrasonography measurements of optic nerve sheath diameter an alternative to fundoscopy in children with syndromic craniosynostosis? Clinical article. <i>J Neurosurg Pediatr</i> 2011;8:329-34.
13	Driessen C, Van Veelen M-LLCLC, Lequin M, Joosten KFMM, Mathijssen IMJJ. Nocturnal ultrasound measurements of optic nerve sheath diameter correlate with intracranial pressure in children with craniosynostosis. <i>Plast Reconstr Surg</i> 2012;130:448-51.
14	Ertl M, Barinka F, Torka E, et al. Ocular color-coded sonography – a promising tool for neurologists and intensive care physicians Die okuläre Farbduplexsonografie – Ungenutztes Potential für Neurologen und Intensivmediziner. <i>Ultraschall Med</i> 2014;35:422-31.
15	Fagenholz PJ, Gutman JA, Murray AF, Noble VE, Camargo CAJ, Harris NS. Evidence for increased intracranial pressure in high altitude pulmonary edema. <i>High Alt Med Biol</i> 2007;8:331-6.
16	Gao Y, Li Q, Wu C, Liu S, Zhang M. Diagnostic and prognostic value of the optic nerve sheath diameter with respect to the intracranial pressure and neurological outcome of patients following hemispherectomy. <i>BMC Neurol</i> 2018;18:1-7.
17	Geeraerts T, Launey Y, Martin L, et al. Ultrasonography of the optic nerve sheath may be useful for detecting raised intracranial pressure after severe brain injury. <i>Intensive Care Med</i> 2007;33:1704-11.
18	Geeraerts T, Merceron S, Benhamou D, et al. Non-invasive assessment of intracranial pressure using ocular sonography in neurocritical care patients. <i>Intensive Care Med</i> 2008;34:2062-7.
19	Goel RS, Goyal NK, Dharap SB, Kumar M, Gore MA. Utility of optic nerve ultrasonography in head injury. <i>Injury</i> 2008;39:519-24.
20	Hall MK, Spiro DM, Sabbaj A, Moore CL, Hopkins KL, Meckler GD. Bedside optic nerve sheath diameter ultrasound for the evaluation of suspected pediatric ventriculoperitoneal shunt failure in the emergency department. <i>Childs Nerv Syst</i> 2013;29:2275-80.
21	Hansen G, Sellers EAC, Beer DL, Vallance JK, Clark I. Optic nerve sheath diameter ultrasonography in pediatric patients with diabetic ketoacidosis. <i>Can J Diabetes</i> 2016;40:126-30.
22	Hassen GW, Bruck I, Donahue J, et al. Accuracy of optic nerve sheath diameter measurement by emergency physicians using bedside ultrasound. <i>J Emerg Med</i> 2015;48:450-7.
23	Hassen GW, Nazeer O, Manizate F, Patel N, Kalantari H. The role of bedside ultrasound in pretherapeutic and posttherapeutic lumbar puncture in patient with idiopathic intracranial hypertension. <i>Am J Emerg Med</i> 2014;32:1298.e3-e4.
24	Helmke K, Hansen HC. Fundamentals of transorbital sonographic evaluation of optic nerve sheath expansion under intracranial hypertension. II. Patient study. <i>Pediatr Radiol</i> 1996;26:706-10.
25	Jeon JP, Lee SU, Kim S-EE, et al. Correlation of optic nerve sheath diameter with directly measured intracranial pressure in Korean adults using bedside ultrasonography. <i>PLoS ONE</i> 2017;12:e0183170.

(Continues)



TABLE 2 (Continued)

#	Citation
26	Jun I-JJ, Kim M, Lee J, et al. Effect of mannitol on ultrasonographically measured optic nerve sheath diameter as a surrogate for intracranial pressure during robot-assisted laparoscopic prostatectomy with pneumoperitoneum and the trendelenburg position. <i>J Endourol</i> 2018;32:608-13.
27	Kazdal H, Kanat A, Findik H, et al. Transorbital ultrasonographic measurement of optic nerve sheath diameter for intracranial midline shift in patients with head trauma. <i>World Neurosurg</i> 2016;85:292-7.
28	Keyes LE, Paterson R, Boatright D, Browne V, Leadbetter G, Hackett P. Optic nerve sheath diameter and acute mountain sickness. <i>Wilderness Environ Med</i> 2013;24:105-11.
29	Kim M-SS, Bai S-JJ, Lee J-RR, Choi YD, Kim YJ, Choi SH. Increase in intracranial pressure during carbon dioxide pneumoperitoneum with steep trendelenburg positioning proven by ultrasonographic measurement of optic nerve sheath diameter. <i>J Endourol</i> 2014;28:801-6.
30	Kim M-SS, Yoon KB, Yoon DM, Kim D-HH. Effect of cervical sympathetic block on optic nerve sheath diameter measured by ultrasonography. <i>Ultrasound Med Biol</i> 2015;41:1599-1604.
31	Kishk NA, Ebraheim AM, Ashour AS, Badr NM, Eshra MA. Optic nerve sonographic examination to predict raised intracranial pressure in idiopathic intracranial hypertension: the cut-off points. <i>Neuroradiol J</i> 2018;31:490-5.
32	Kitano T, Nezu T, Mukai T, Uemura J, Wada Y, Yagita Y. A case of hypertensive encephalopathy with enlarged optic nerve sheath measured by transorbital sonography. <i>J Stroke Cerebrovasc Dis</i> 2017;26:e20-e1.
33	Komut E, Kozaci N, Sonmez BM, et al. Bedside sonographic measurement of optic nerve sheath diameter as a predictor of intracranial pressure in ED. <i>Am J Emerg Med</i> 2016;34:963-7.
34	Le A, Hoehn ME, Smith ME, Spentzas T, Schlappy D, Pershad J. Bedside sonographic measurement of optic nerve sheath diameter as a predictor of increased intracranial pressure in children. <i>Ann Emerg Med</i> 2009;53:785-91.
35	Lee SU, Jeon JP, Lee H, et al. Optic nerve sheath diameter threshold by ocular ultrasonography for detection of increased intracranial pressure in Korean adult patients with brain lesions. <i>Med</i> 2016;95:1-5.
36	Lochner P, Brigo F, Zedde ML, et al. Feasibility and usefulness of ultrasonography in idiopathic intracranial hypertension or secondary intracranial hypertension. <i>BMC Neurol</i> 2016;16:85.
37	Lochner P, Falla M, Brigo F, Pohl M, Strapazon G. Ultrasonography of the optic nerve sheath diameter for diagnosis and monitoring of acute mountain sickness: a systematic review. <i>High Alt Med Biol</i> 2015;16:195-203.
38	Lochner P, Fassbender K, Lesmeister M, et al. Ocular ultrasound for monitoring pseudotumor cerebri syndrome. <i>J Neurol</i> 2018;265:356-61.
39	Lochner P, Nardone R, Tezzon F, Coppo L, Brigo F. Optic nerve sonography to monitor treatment efficacy in idiopathic intracranial hypertension: a case report. <i>J Neuroimaging</i> 2013;23:533-4.
40	Maissan IM, Ketelaars R, Vlottes B, Hoeks SE, Den Hartog D, Stolker RJ. Increase in intracranial pressure by application of a rigid cervical collar: a pilot study in healthy volunteers. <i>Eur J Emerg Med</i> 2018;25:e24-e8.
41	Min JY, Lee J-R, Oh J-T, Kim M-S, Jun E-K, An J. Ultrasonographic assessment of optic nerve sheath diameter during pediatric laparoscopy. <i>Ultrasound Med Biol</i> 2015;41:1241-6.
42	Moretti R, Pizzi B. Optic nerve ultrasound for detection of intracranial hypertension in intracranial hemorrhage patients. <i>J Neurosurg Anesthesiol</i> 2009;21:16-20.
43	Moretti R, Pizzi B, Cassini F, Vivaldi N. Reliability of optic nerve ultrasound for the evaluation of patients with spontaneous intracranial hemorrhage. <i>Neurocrit Care</i> 2009;11:406-10.
44	Rajajee V, Fletcher JJ, Rochlen LR, Jacobs TL. Comparison of accuracy of optic nerve ultrasound for the detection of intracranial hypertension in the setting of acutely fluctuating vs stable intracranial pressure: post-hoc analysis of data from a prospective, blinded single center study. <i>Crit Care</i> 2012;16:R79.
45	Rajajee V, Vanaman M, Fletcher JJ, Jacobs TL. Optic nerve ultrasound for the detection of raised intracranial pressure. <i>Neurocrit Care</i> 2011;15:506-15.
46	Rajajee V, Williamson CA, Fontana RJ, Courey AJ, Patil PG. Noninvasive intracranial pressure assessment in acute liver failure. <i>Neurocrit Care</i> 2018;29:280-90.
47	Rehman Siddiqui NU, Haque A, Abbas Q, Jurair H, Salam B, Sayani R. Ultrasonographic optic nerve sheath diameter Measurement for raised intracranial pressure in a Tertiary care centre of a developing country. <i>J Ayub Med Coll Abbottabad</i> 2018;30:495-500.
48	Robba C, Bacigaluppi S, Cardim D, et al. Intraoperative non invasive intracranial pressure monitoring during pneumoperitoneum: a case report and a review of the published cases and case report series. <i>J Clin Monit Comput</i> 2016;30:527-38.
49	Roque PJ, Wu TS, Barth L, et al. Optic nerve ultrasound for the detection of elevated intracranial pressure in the hypertensive patient. <i>Am J Emerg Med</i> 2012;30:1357-63.

(Continues)



TABLE 2 (Continued)

#	Citation
50	Salahuddin N, Mohamed A, Alharbi N, et al. The incidence of increased ICP in ICU patients with non-traumatic coma as diagnosed by ONSD and CT: a prospective cohort study. <i>BMC Anesthesiol</i> 2016;16:106.
51	Singleton J, Dagan A, Edlow JA, Hoffmann B. Real-time optic nerve sheath diameter reduction measured with bedside ultrasound after therapeutic lumbar puncture in a patient with idiopathic intracranial hypertension. <i>Am J Emerg Med</i> 2015;33:860.e5-e7.
52	Školoudík D, Herzig R, Fadrná T, et al. Distal enlargement of the optic nerve sheath in the hyperacute stage of intracerebral haemorrhage. <i>Br J Ophthalmol</i> 2011;95:217-21.
53	Soldatos T, Chatzimichail K, Papathanasiou M, Gouliamos A. Optic nerve sonography: a new window for the non-invasive evaluation of intracranial pressure in brain injury. <i>Emerg Med J</i> 2009;26:630-4.
54	Steinborn M, Friedmann M, Makowski C, Hahn H, Hapfelmeier A, Juenger H. High resolution transbulbar sonography in children with suspicion of increased intracranial pressure. <i>Childs Nerv Syst</i> 2016;32:655-60.
55	Tarzamni MK, Derakhshan B, Meshkini A, et al. The diagnostic performance of ultrasonographic optic nerve sheath diameter and color Doppler indices of the ophthalmic arteries in detecting elevated intracranial pressure. <i>Clin Neurol Neurosurg</i> 2016;141:82-8.
56	Tayal VS, Neulander M, Norton HJ, Foster T, Saunders T, Blaivas M. Emergency department sonographic measurement of optic nerve sheath diameter to detect findings of increased intracranial pressure in adult head injury patients. <i>Ann Emerg Med</i> 2007;49:508-14.
57	Topcuoglu MA, Arsava EM, Bas DF, Kozak HH. Transorbital ultrasonographic measurement of optic nerve sheath diameter in brain death. <i>J Neuroimaging</i> 2015;25:906-9.
58	Toscano M, Spadetta G, Pulitano P, et al. Optic nerve sheath diameter ultrasound evaluation in intensive care unit: possible role and clinical aspects in neurological critical patients' daily monitoring. <i>Biomed Res Int</i> 2017;2017:1621428.
59	Wang L-JJ, Chen L-MM, Chen Y, et al. Ultrasonography assessments of optic nerve sheath diameter as a noninvasive and dynamic method of detecting changes in intracranial pressure. <i>JAMA Ophthalmol</i> 2018;136:250-6.
60	Wang L-JJ, Yao Y, Feng L-SS, et al. Noninvasive and quantitative intracranial pressure estimation using ultrasonographic measurement of optic nerve sheath diameter. <i>Sci Rep</i> 2017;7:1-7.
61	Wang L, Feng L, Yao Y, et al. Optimal optic nerve sheath diameter threshold for the identification of elevated opening pressure on lumbar puncture in a Chinese population. <i>PLoS ONE</i> 2015;10:1-10.
62	Whiteley JR, Taylor J, Henry M, Epperson TI, Hand WR. Detection of elevated intracranial pressure in robot-assisted laparoscopic radical prostatectomy using ultrasonography of optic nerve sheath diameter. <i>J Neurosurg Anesthesiol</i> 2015;27:155-9.
63	Yu J, Park J-Y, Kim D-H, et al. Dexmedetomidine attenuates the increase of ultrasonographic optic nerve sheath diameter as a surrogate for intracranial pressure in patients undergoing robot-assisted laparoscopic prostatectomy. <i>Medicine</i> 2019;98:e16772.

Besides the different interpretations of the echoic fingerprint of the optic nerve sheath, the duality in echoic characteristic patterns of the ultrasound images (Category A and Category B) needs to be considered. Although our data did not show an association between appearance of hyperechoic striped bands and ultrasound frequency or imaging plane, a recent study from Pichamuthu et al.<sup>7</sup> points out that ultrasound images might be dependent on the transducer frequency used because high-frequency transducers allow imaging of smaller structures in comparison with lower frequency probes. Moreover, the usage of higher frequency probes makes the ONSD assessment possibly less susceptible to edge artifacts because the true outlines of the optic nerve sheath are more clearly visible.<sup>7</sup>

It cannot be excluded that patient characteristics such as gender or age also play a role whether hyperechoic striped bands appear on retrobulbar ultrasound images.

The marker placement used to determine the assessment depth of 3 mm also appears to be an enigma as becomes apparent by the variation in terms used to annotate a specific anatomical landmark and the use of the same term for different anatomical landmarks. However, these discrepancies did not affect ONSD values, most likely, because the distance between the different anatomical landmarks used is less than

1 mm resulting in comparable ONSD values. Nevertheless, the usage of a singular landmark and corresponding terminology could avoid confusion.

For all groups, that is, healthy subjects and age-matched controls as well as patients with ICP<sub>norm</sub> and ICP<sub>high</sub>, we found ONSD values determined with Method A1 to be larger than values determined with A2, which in turn were larger than values obtained with Methodology A3. This finding is trivial because the markers for Position 1, 2, and 3 are located from outside to inside on the ultrasound image. However, the difference in ONSD values between Methods A2 and A3 was twice as large as the difference between ONSD values assessed with Methods A1 and A2. The difference in ONSD values between healthy/controls and patients with ICP<sub>norm</sub> and ICP<sub>high</sub> showed that Method A3 was the only method that did not allow a clear distinction between the high- and low-ICP groups, making Method A3 clinically not useful. Moreover, the small difference in ONSD values between ICP<sub>norm</sub> and ICP<sub>high</sub> for Method A3 is a clear indication that this method does not measure the subarachnoid space because the subarachnoid space is the only structure that expands when ICP increases. In addition, ONSD values determined with A3 were mostly in the order of 3 mm, which is approximately the diameter of the optic nerve itself. Therefore, marker



position A3 corresponds with the outline of the optic nerve. This, in combination with the fact that ONSD values assessed with position A2 do become significantly larger in patient with ICP<sub>high</sub>, is a clear indication that marker position A2 incorporates the subarachnoid space. This makes it very likely that marker position A2 corresponds to the outer edge of the subarachnoid space that appears as the hyperechoic striped bands. Consequently, marker placements as described in Method A1 and B both correspond to the outer edges of the dura mater.

Placing the markers at the positions of Method A2 and B yields similar ONSD values, and both methods are found to be equally sensitive to changes in ICP. In clinical practice, it does therefore not matter whether either ultrasound images with hyperechoic bands in combination with Method A2 or ultrasound images without hyperechoic bands in combination with Method B are used for ONSD assessment.

## Limitations

One limitation of our study is that we did only categorize the articles based on the exemplary ultrasound images and that we did not incorporate the methodological descriptions. However, as demonstrated in our analysis, methodological descriptions were often not reported or inconclusive, which would make categorization impossible. Nevertheless, this observation further highlights our conclusions regarding the urgent need for ONSD standardization and improved documentation.

Although articles were categorized based on their reported exemplary ultrasound image, ONSD assessment might have been performed differently. Moreover, in some cases it was hard to differentiate whether ultrasound marker placement was at position A1 or A2 because the dark lines between hyperechoic striped bands and hyperechoic retrobulbar fat were often very narrow. Because only 63 articles could be included for our analysis, we had limited number of ONSD values for each of the four groups.

## Recommendations

Our results showed not only a large variety in ONSD assessment methodology, but also that ONSD values depend on the methodologies used. This variety in measurement approaches could be an explanation for the discrepancies in the threshold values for elevated ICP reported in literature. Based on our findings, we provide the following crucial instructions for reliable and apparent ONSD measurements:

1. Place ultrasound markers at the outer edges of the hyperechoic striped bands or at the transitions from the single dark region to the hyperechoic retrobulbar fat.
2. Use the papilla as a reference point for the 3-mm depth assessment.
3. MI has to be kept at values smaller than or equal to 0.3 to ensure patient safety. The thermal index, on the contrary, is not relevant for this examination.

4. Although adequate ONSD measurements can be performed with almost any linear transducer available, we suggest the usage of linear transducers with the highest possible frequency to optimize resolution.

## CONCLUSION

In this study, we performed a literature review on ONSD methodologies and examined their effect on ONSD values. We found discrepancies in ultrasound machine settings, characteristic appearances of ultrasound images, structural interpretation of these images, and ultrasound marker placement. More importantly, our results showed that ONSD values depend on the methodologies used. Based on our findings, we propose a set of recommendations for ultrasound imaging of the optic nerve sheath, choice of anatomical landmark used to determine ONSD assessment depth, as well as choice of marker positions that annotate the optic nerve sheath. These recommendations will decrease the variation in ONSD values due to assessment discrepancies and possibly improve the accuracy of noninvasive bedside ICP monitoring.

## ACKNOWLEDGEMENTS AND DISCLOSURE

The authors declare no conflict of interest.

## ORCID

Raoul R. F. Stevens <https://orcid.org/0000-0003-1860-2846>

Erik D. Gommer <https://orcid.org/0000-0003-1054-2682>

Marcel J.H. Aries <https://orcid.org/0000-0002-5872-113X>

Michael Ertl <https://orcid.org/0000-0001-5271-4898>

Werner H. Mess <https://orcid.org/0000-0002-9736-9941>

Wouter Huberts <https://orcid.org/0000-0002-0779-4785>

Tammo Delhaas <https://orcid.org/0000-0001-6897-9700>

## REFERENCES

1. Geeraerts T, Merceron S, Benhamou D, et al. Non-invasive assessment of intracranial pressure using ocular sonography in neurocritical care patients. *Intensive Care Med* 2008;34:2062-7.
2. Toscano M, Spadetta G, Pulitano P, et al. Optic nerve sheath diameter ultrasound evaluation in intensive care unit: possible role and clinical aspects in neurological critical patients' daily monitoring. *Biomed Res Int* 2017;2017:1621428.
3. Bäuerle J, Lochner P, Kaps M, et al. Intra- and interobserver reliability of sonographic assessment of the optic nerve sheath diameter in healthy adults. *J Neuroimaging* 2012;22:42-5.
4. Lochner P, Coppo L, Cantello R, et al. Intra- and interobserver reliability of transorbital sonographic assessment of the optic nerve sheath diameter and optic nerve diameter in healthy adults. *J Ultrasound* 2016;19:41-5.
5. Dubourg J, Javouhey E, Geeraerts T, et al. Ultrasonography of optic nerve sheath diameter for detection of raised intracranial pressure: a systematic review and meta-analysis. *Intensive Care Med* 2011;37:1059-68.
6. Wang L-JJ, Yao Y, Feng L-SS, et al. Noninvasive and quantitative intracranial pressure estimation using ultrasonographic measurement of optic nerve sheath diameter. *Sci Rep* 2017;7:1-7.



7. Pichamuthu KK, Prithishkumar IJ. Appearance of the optic nerve sheath diameter (ONSD) using higher frequency linear probes in detection and monitoring of raised intracranial pressures-a cadaveric study. *J Clin diagnostic Res* 2019;13:10-3.
8. Remington LA, Goodwin D. *Clinical Anatomy of the Visual System*. Oxford, UK: Butterworth-Heinemann; 2004.
9. Liu D, Kahn M. Measurement and relationship of subarachnoid pressure of the optic nerve to intracranial pressures in fresh cadavers. *Am J Ophthalmol* 1993;116:548-56.
10. Helmke K, Hansen HC. Fundamentals of transorbital sonographic evaluation of optic nerve sheath expansion under intracranial hypertension. I. Experimental study. *Pediatr Radiol* 1996;26:706-10.
11. Pache M, Meyer P. Morphological changes of the retrobulbar optic nerve and its meningeal sheaths in glaucoma. *Ophthalmologica* 2006;220:393-6.
12. Lang J. *Clinical Anatomy of the Head*. Würzburg, Germany: Springer-Verlag; 1983.
13. Killer HE, Laeng HR, Flammer J, et al. Architecture of arachnoid trabeculae, pillars, and septa in the subarachnoid space of the human optic nerve: anatomy and clinical considerations. *Br J Ophthalmol* 2003;87:777-81.
14. Ertl M, Barinka F, Torka E, et al. Ocular color-coded sonography – a promising tool for neurologists and intensive care physicians die okuläre farbduplexsonografie – ungenutztes potential für neurologen und intensivmediziner. *Ultraschall Med* 2014;35:422-31.
15. Steinborn M, Friedmann M, Makowski C, et al. High resolution transbulbar sonography in children with suspicion of increased intracranial pressure. *Childs Nerv Syst* 2016;32:655-60.
16. del Saz-Saucedo P, Redondo-Gonzalez O, Mateu-Mateu A, et al. Sonographic assessment of the optic nerve sheath diameter in the diagnosis of idiopathic intracranial hypertension. *J Neurol Sci* 2016;361:122-7.
17. Lochner P, Falla M, Brigo F, et al. Ultrasonography of the optic nerve sheath diameter for diagnosis and monitoring of acute mountain sickness: a systematic review. *High Alt Med Biol* 2015;16:195-203.
18. Bäuerle J, Nedelmann M, Bauerle J, et al. Sonographic assessment of the optic nerve sheath in idiopathic intracranial hypertension. *J Neurol* 2011;258:2014-9.
19. Kishk NA, Ebraheim AM, Ashour AS, et al. Optic nerve sonographic examination to predict raised intracranial pressure in idiopathic intracranial hypertension: the cut-off points. *Neuroradiol J* 2018;31:490-5.
20. Topcuoglu MA, Arsava EM, Bas DF, et al. Transorbital ultrasonographic measurement of optic nerve sheath diameter in brain death. *J Neuroimaging* 2015;25:906-9.
21. Schroeder C, Katsanos AH, Richter D, et al. Quantification of optic nerve and sheath diameter by transorbital sonography: a systematic review and metanalysis. *J Neuroimaging* 2020;30:165-74.
22. Chen Q, Chen W, Wang M, et al. High-resolution transbulbar ultrasonography helping differentiate intracranial hypertension in bilateral optic disc oedema patients. *Acta Ophthalmol* 2017;95:e481-e5.
23. Hansen HC, Helmke K. The subarachnoid space surrounding the optic nerves. An ultrasound study of the optic nerve sheath. *Surg Radiol Anat* 1996;18:32328.
24. Liu D, Li Z, Zhang X, et al. Assessment of intracranial pressure with ultrasonographic retrobulbar optic nerve sheath diameter measurement. *BMC Neuro* 2017;17:188.
25. Dinsmore M, Han JS, Fisher JA, et al. Effects of acute controlled changes in end-tidal carbon dioxide on the diameter of the optic nerve sheath: a transorbital ultrasonographic study in healthy volunteers. *Anaesthesia* 2017;72:618-23.
26. Lochner P, Brigo F, Zedde ML, et al. Feasibility and usefulness of ultrasonography in idiopathic intracranial hypertension or secondary intracranial hypertension. *BMC Neurol* 2016;16:85.

**How to cite this article:** Raoul R.F. Stevens, Erik D. Gommer, Marcel Aries, Michael Ertl, Werner H. Mess, Wouter Huberts, Tammo Delhaas. Optic nerve sheath diameter assessment by neurosonology: A review of methodologic discrepancies. *J Neuroimaging*. 2021;31:814–825.  
<https://doi.org/10.1111/jon.12906>