

## ROLE OF ULTRASONOGRAPHY IN THE DETECTION OF A SUBPERIOSTEAL ABSCESS SECONDARY TO MASTOIDITIS IN PEDIATRIC PATIENTS

KONSTANTINOS MANTSOPOULOS,\* JOCHEN WURM,\* HEINRICH IRO,\* and JOHANNES ZENK†

\*Department of Otorhinolaryngology, Head and Neck Surgery, University of Erlangen–Nuremberg, Erlangen, Germany; and

†Department of Otorhinolaryngology, Head and Neck Surgery, Hospital Augsburg, Augsburg, Germany

### INTRODUCTION

The incidence of acute mastoiditis secondary to acute otitis media has decreased significantly in the antibiotic era (Alper et al. 2004). However, inadequate or delayed treatment of otitis media predisposes to the development of this and other more serious, life-threatening complications (Shanley and Murphy 1992). Among other things, acute mastoiditis can lead to a subperiosteal abscess, as purulent material coming from the mastoid seeps into the potential space beneath the bone and the outer periosteum. The infection spreads by traveling through pre-existing bony dehiscence or bone erosion or along small vessels. The periosteum of the temporal bone is detached by the progressing abscess, but its progression is limited inferiorly by the muscle attachments (Nadol and McKenna 2005). In children, large subperiosteal mastoid abscesses can easily form because the periosteum is loosely attached to the surface of the temporal bone

(Vinay et al. 2007). According to the relevant literature, the most common localization of a subperiosteal abscess is the suprameatal triangle (or MacEwen's triangle): In this region, the cortical bone is particularly thin and small vessels are present, making a preferred hematogenic route of subperiosteal abscess formation, secondary to coalescent mastoiditis (Alper et al. 2004).

It is well known that high-resolution computed tomography (HRCT) of the temporal bone is the examination of choice for evaluating the complications of acute otitis media. This imaging method offers high-resolution images that allow good visualization of the fine anatomy of the temporal bone, ossicles and inner ear (Savic et al. 1987). On the other hand, the issue of ionizing radiation and the need for sedation in many pediatric cases can be seen as limitations of this method. These aspects are even more important if we consider that such complications can easily occur in the sensitive population of pediatric patients (Nadol and McKenna 2005).

In a preliminary report, Mann (1978) described the potential use of A-scan ultrasonography with a 4-MHz focused transducer in detecting the presence of fluid in the antrum and the mastoid in young children: The swollen mucosa and the fluid retention within the mastoid made ultrasound transmission possible, whereas in the case of

---

Address correspondence to: Konstantinos Mantsopoulos, Department of Otorhinolaryngology, Head and Neck Surgery, University of Erlangen–Nuremberg, Waldstrasse 1, 91054 Erlangen, Germany. E-mail: [konstantinos.mantsopoulos@uk-erlangen.de](mailto:konstantinos.mantsopoulos@uk-erlangen.de)

Konstantinos Mantsopoulos and Jochen Wurm contributed equally to the present study.

normal air content of the mastoid, all ultrasound energy was reflected at the bone–air interface and no medial wall echo was obtainable. Interestingly, the first report on the possible role of B-mode ultrasonography in the diagnostic approach to a subperiosteal abscess secondary to mastoiditis was published as recently as 2005, when [Grant and Piotto \(2005\)](#) recommended its use based on the case of a 3-mo-old boy. Since then, to our knowledge, there have been no data in the literature on the value of ultrasound in the diagnostic imaging of the temporal bone.

The purpose of this study was to present and evaluate our experience in a single academic tertiary center in the use of ultrasound as a first imaging tool in the pre-operative diagnostic approach to subperiosteal abscess secondary to mastoiditis. An additional purpose of our study was to obtain additional imaging information on the possible importance of ultrasound in the differential diagnosis of the pathologies of the retro-auricular region. This may be of practical importance for optimization of the diagnostic and therapeutic ap-

proaches to these patients and may minimize the need for further diagnostic examinations (HRCT), urgent decision making or unnecessary surgical interventions.

## METHODS

This retrospective case series study was conducted at a single academic tertiary referral center specialized in ultrasound diagnostics of the head and neck region (Department of Otorhinolaryngology, Head and Neck Surgery, University of Erlangen–Nuremberg, Germany). The ultrasound findings of all patients presenting between 2004 and 2012 with clinical symptoms compatible with otomastoiditis were examined. Patients with insufficient imaging data were excluded from this study. Over a 9-y period, 10 consecutive cases in which an ultrasound examination of the retro-auricular region was performed for suspicion of mastoiditis were identified; these cases included five female and five male patients (mean age: 6 y, range: 18 mo–13 y). In the presence of a

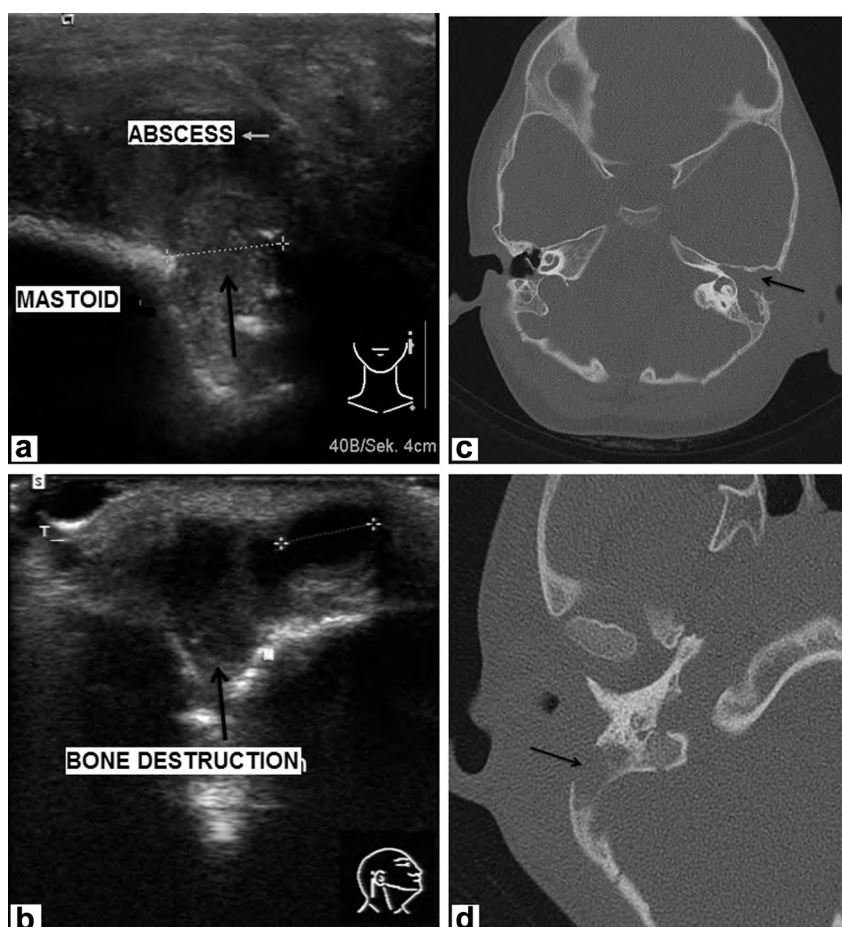


Fig. 1. (a, b) Ultrasound findings: Poorly demarcated, inhomogeneous, irregular lesion in the retro-auricular region with disruption of the continuity of the mastoid bone and defect of the external cortex. (c, d) Corresponding computed tomography findings: Delineation of a bony defect of the outer cortex of the temporal bone (*arrows*).

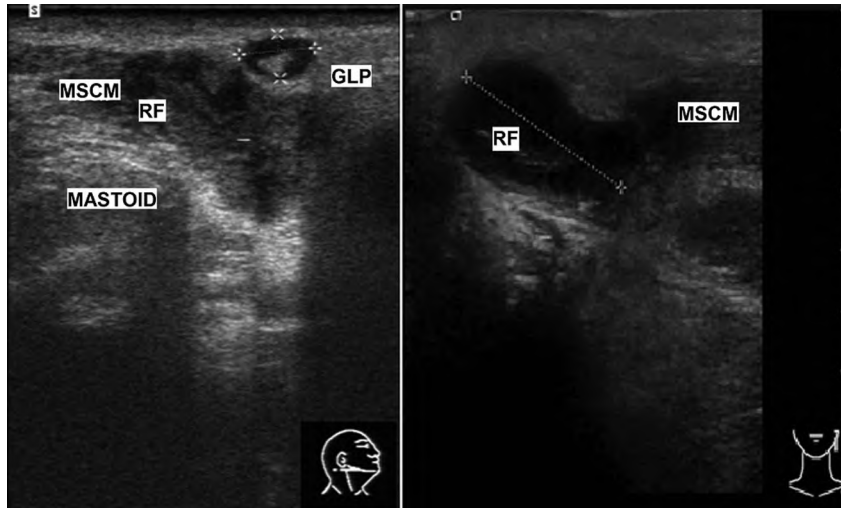


Fig. 2. Additional invasion of the insertion of the sternocleidomastoid muscle on the mastoid process of the temporal bone and its superior part raised the suspicion of Bezold mastoiditis. MSCM = sternocleidomastoid muscle; RF = abscess; GLP = parotid gland.

subcutaneous painful retro-auricular mass with clinical signs of inflammation and suspected acute mastoiditis, B-mode and color duplex sonography (ACUSON S2000, Siemens Healthcare, Erlangen, Germany, 9 MHz) of the temporal bone was performed with a 9 L4 transducer before high HRCT. Approval was obtained from the institutional review board of our hospital. Informed consent for use of the patient data was waived by our institutional review board.

## RESULTS

In nine cases, the ultrasound finding was that of a poorly demarcated, inhomogeneous, irregular, poorly (or not at all) perfused lesion abutting the outer table of the cranial vault, with a clearly delineated defect of the cortical layer of the mastoid bone, elevation of the outer periosteum, a vascular periphery in the retro-auricular region and signs of intracranial extension *via* this external cortex defect (Fig. 1a, 1b). All of these ultrasound findings were perfectly consistent with the computed tomography and intra-operative findings (Fig. 1c, 1d). In one of the nine cases, additional invasion of the insertion of the sternocleidomastoid muscle on the mastoid process of the temporal bone and its superior part raised the suspicion of Bezold mastoiditis (Fig. 2), which was confirmed intra-operatively. In one patient, ultrasound revealed a well-defined, homogeneous lesion with strongly perfused hilum signs, and the primary diagnosis of retro-auricular lymphadenitis was rendered (Fig. 3). In this case, ultrasound-guided diagnosis helped in avoiding further diagnostic imaging, and conservative treatment led to complete resolution of the symptoms.

## DISCUSSION

At present, high-resolution computed tomography is considered to be the imaging method of choice for patients with temporal bone pathology. This method can best display the fine bony detail and the resorption of the air cell partition of the mastoid process. However, according to the literature, even with low-dose scan protocols, the effective dose of HRCT of the temporal bone appears to be not lower than 0.25–0.3 mSv (Nauer et al. 2011).

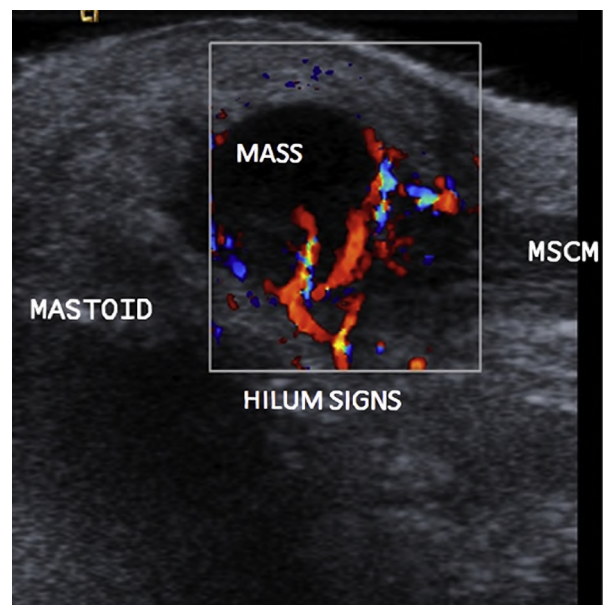


Fig. 3. Color duplex sonography image of an inflamed retro-auricular lymph node. MSCM = sternocleidomastoid muscle.

According to the [German Federal Office for Radiation Protection \(2015\)](#), this dose is somewhat higher than the radiation exposure during a transatlantic flight. Furthermore, when performed using conventional sequential direct axial and coronal methods, parallel to the glabellomeatal or orbitomeatal line, the patient's eyes are exposed to direct radiation ([Alper et al. 2004](#)). This is an issue of major concern if we consider that the lens is one of the most radiosensitive organs in the human body, especially in children, in whom the risk of developing lens opacities (e.g., cataracts) might be higher because of cumulative lifetime doses ([Alper et al. 2004](#)). Thus, the need for an imaging procedure without ionizing radiation in the sensitive patient group of children and pregnant women brings the aspect of the applicability of other imaging modalities in the diagnostics of the temporal bone into the discussion. Ultrasound has numerous advantages in this respect: it is readily accessible, can be performed with minimal discomfort to the patient, has a lower cost, constitutes a real-time imaging procedure and is useful in patients in whom magnetic resonance imaging is contraindicated ([Pineda et al. 2009](#)).

According to the relevant orthopedic literature, ultrasound represents a non-invasive, reliable diagnostic method in evaluating the soft tissues and cortical bone involved in cases of osteomyelitis and may provide guidance for diagnostic or therapeutic aspiration, drainage or tissue biopsy. In comparison to plain radiographs, this method is able to identify signs of an osteomyelitic infection in pediatric patients several days earlier and does not require sedation ([Pineda et al. 2009](#)). On ultrasound, acute osteomyelitis is recognized through the elevation of the periosteum by a hypoechoic underlying layer of purulent material between the periosteum and cortex. Additionally, erosions of the bone cortex can become easily and sufficiently apparent ([Pineda et al. 2006](#)). Furthermore, application of color duplex sonography may be useful in identifying an inflammation-related hyperemia around the periosteum and surrounding soft tissue abscesses ([Chao et al. 1999](#); [Collado et al. 2008](#); [Klauser et al. 2006](#)).

With the help of these data from the literature, one may assume that this method can be successfully applied in the primary diagnosis of inflammatory (osteomyelitic) pathologies of the temporal bone. This is clearly shown by our study: Although destruction of the outer cortex and formation of a subperiosteal abscess are known to

be best demarcated with HRCT ([Nadol and McKenna 2005](#)), our experience indicates that ultrasound may be a useful adjunct as a first imaging tool before temporal bone CT, as it can precisely delineate a bony defect of the outer cortex of the temporal bone. Additionally, extension into the sternocleidomastoid muscle was also perfectly detected on ultrasound. Furthermore, sonographic exclusion of temporal bone erosion may be useful in differentiating an inflammatory mastoid process from retro-auricular erysipelas, a retro-auricular lymph node or a dermoid cyst with local signs of inflammation. To this extent, ultrasound may help in selecting patients for further imaging and might spare radiation therapy, especially in sensitive patient groups such as children and pregnant women, if a bony defect can be excluded with certainty.

## REFERENCES

- Alper C, Bluestone C, Casselbrant M, Dohar J, Mandel E. *Advanced therapy of otitis media*. Hamilton, ON: BC Decker; 2004.
- Chao HC, Lin SJ, Huang YC, Lin TY. Color Doppler ultrasonographic evaluation of osteomyelitis in children. *J Ultrasound Med* 1999;18:729–734. quiz 735–736.
- Collado P, Naredo E, Calvo C, Crespo M. Role of power Doppler sonography in early diagnosis of osteomyelitis in children. *J Clin Ultrasound* 2008;36:251–253.
- German Federal Office for Radiation Protection. Radiation exposure of airline passengers. Available at: <http://www.bfs.de/en/ion/anthrop/fluggassagiere.html>. Accessed January 13, 2015.
- Grant RL, Piotto L. Ultrasound detection of a subperiosteal abscess secondary to coalescent otomastoiditis. *Australas Radiol* 2005;49:312–314.
- Klauser AS, Moriggl B, Duftner C, Smekal V, Pallwein L, Mur E, Schirmer M. Sonography of synovial and erosive inflammatory changes. *Radiologe* 2006;46:365–375.
- Mann W. Echography of the infantile mastoid. *Arch Otorhinolaryngol* 1978;220:291–294.
- Nadol J, McKenna M. *Surgery of the ear and temporal bone*. Philadelphia: Lippincott Williams & Wilkins; 2005.
- Nauer CB, Rieke A, Zubler C, Candreira C, Arnold A, Senn P. Low-dose temporal bone CT in infants and young children: Effective dose and image quality. *AJNR Am J Neuroradiol* 2011;32:1375–1380.
- Pineda C, Espinosa R, Pena A. Radiographic imaging in osteomyelitis: The role of plain radiography, computed tomography, ultrasonography, magnetic resonance imaging, and scintigraphy. *Semin Plast Surg* 2009;23:80–89.
- Pineda C, Vargas A, Rodriguez AV. Imaging of osteomyelitis: current concepts. *Infect Dis Clin North Am* 2006;20:789–825.
- Savic D, Jasovic A, Djerić D. The value of computerized tomography (CT) in the evaluation of the anatomic structure of the attic. *J Laryngol Otol* 1987;101:1118–1124.
- Shanley DJ, Murphy TF. Intracranial and extracranial complications of acute mastoiditis: Evaluation with computed tomography. *J Am Osteopath Assoc* 1992;92:131–134.
- Vinay K, Abul AK, Nelson F, Richard MN. *Robbins basic pathology*. Philadelphia: Elsevier Health Sciences; 2007.