

Evolution and Changing Trends in Surgery for Benign Parotid Tumors

Konstantinos Mantsopoulos, PhD, MD; Michael Koch, PhD, MD; Nils Klintworth, PhD, MD;
Johannes Zenk, PhD, MD; Heinrich Iro, PhD, MD

Objective/Hypothesis: The ideal extent of surgical intervention for benign parotid tumors remains a matter of controversy. The aim of the study was to trace the development of surgical therapy in a large cohort, explore its changes in a single institution specializing in salivary gland pathologies over the last 12 years, and determine the extent to which a possible shift in the surgical therapy of parotid benign tumors toward less radical methods was correlated with a change in the incidence of facial palsy and Frey's syndrome.

Study Design: Retrospective clinical study.

Methods: A retrospective evaluation of the records for all patients treated for benign parotid tumors between 2000 and 2012 at a tertiary referral center was carried out. Surgical methods were classified into four groups: extracapsular dissection, partial superficial parotidectomy, superficial parotidectomy, and complete parotidectomy.

Results: A total of 1,624 patients were included in the study. Our analysis demonstrated an increase in the total number of parotidectomies for benign lesions from 71 (2000) to 184 (2012), mostly due to the increase in extracapsular dissections (from 9 to 123). Increased performance of less radical surgery was associated with a significantly decreased incidence of temporary and permanent facial palsies (from 22.8% to 9% and 9.8% to 5.9%, respectively) and Frey's syndrome (from 11.3% to 1.6%).

Conclusions: One of the most controversial issues in the treatment of benign parotid tumors is the best therapeutic approach to be taken in such patients. Our study showed that increased performance of less radical surgery was associated with better functional outcomes.

Key Words: Parotid gland, benign tumors, extracapsular dissection, partial parotidectomy, facial palsy, Frey's syndrome.

Level of Evidence: 2b.

INTRODUCTION

In the first half of the 20th century, a common surgical treatment for benign parotid tumors was the intracapsular enucleation of the tumor (i.e., the opening of the tumor capsule after tumor exposure and resection of the tumor tissue out of the capsule in its entirety).¹⁻³ In the middle of the last century, the technique and philosophy of parotidectomy for benign parotid lesions was reviewed and refined in two directions. First, surgical therapy became a little more radical in the sense of resection of the tumor capsule with surrounding healthy glandular tissue. Second, attention was paid to the standard and complete dissection of the facial nerve in an antegrade or retrograde manner.^{4,5} Standard and

obligatory dissection of the facial nerve and thus a resulting superficial or complete parotidectomy remains the traditional standard of surgical philosophy and care for benign parotid lesions in many centers. Nevertheless, it is beyond doubt that the desirable extent of surgical therapy for benign parotid tumors is still a matter of controversy. For example, supporters of the minimally invasive concept claim, among things, that a dissection of the facial nerve brings the risk of intraoperative nerve damage and makes a revision in this region far more difficult because of postoperative scarring.⁶⁻⁹

In this context, extracapsular dissection has been proposed as an alternative surgical modality method to minimize the morbidity of parotidectomy. The main principle of this method lies in the meticulous dissection around the tumor capsule, without the intention of pre-identification or exposure of the main trunk or branches of the facial nerve.^{10,11} Among other things, supporters of this surgical procedure claim that primary extracapsular dissection offers better conditions for the facial nerve in revision cases, because the nerve is not exposed during the primary operation and thus not bound up in scar tissue.¹² Extracapsular dissection as a definitive surgical treatment for benign tumors of the parotid gland has been performed in our department since 1999. The aim of this study was to explore the changes in parotid surgery in a single department over the past

From the Department of Otorhinolaryngology, Head and Neck Surgery (K.M., M.K., N.K., H.I.), University of Erlangen-Nuremberg, Erlangen, Germany; and the Department of Otorhinolaryngology, Head and Neck Surgery (J.Z.), Augsburg Hospital, Augsburg, Germany.

The authors have no funding, financial relationships, or conflicts of interest to disclose.

Send correspondence to Konstantinos Mantsopoulos, PhD, MD, Department of Otorhinolaryngology, Head and Neck Surgery, University of Erlangen-Nuremberg, Waldstrasse 1, 91054 Erlangen, Germany. E-mail: konstantinos.mantsopoulos@uk-erlangen.de

TABLE I.
Total Number of Surgeries in Each Surgical Modality in the Years 2000 to 2012.

Surgery Type	2000	2001	2002	2003	2004	2005	2006	2007	2008	2009	2010	2011	2012	Total (%)
Extracapsular dissection	9	19	29	29	44	55	64	66	78	72	98	110	123	796 (49)
Partial superficial parotidectomy	7	2	9	9	14	6	14	38	23	28	21	26	20	217 (13.4)
Superficial parotidectomy	14	17	38	25	20	10	15	21	11	12	12	16	10	221 (13.6)
Complete parotidectomy	41	37	35	26	25	33	33	30	25	24	28	22	31	390 (24)
Total	71	75	111	89	103	104	126	155	137	136	159	174	184	1,624

years, with progressive development of knowledge about the behavior of benign parotid tumors and improvement of imaging techniques and surgical expertise. Our study also aimed to determine whether a change in the philosophy of the surgical management of benign parotid tumors correlated with a change in the incidence of post-operative complications (temporary and permanent facial palsy, Frey's syndrome).

MATERIALS AND METHODS

This retrospective study was conducted at an academic tertiary referral center specializing in salivary gland pathologies (Department of Otorhinolaryngology, Head and Neck Surgery, University of Erlangen–Nuremberg, Erlangen, Germany). The records of all patients treated for benign tumors of the parotid gland between 2000 and 2012 were evaluated. Patients with insufficient data, as well as histologic findings other than a benign tumor of the parotid gland or primary surgical revisions of external surgeries, were excluded from this study.

All patients were evaluated preoperatively with a clinical examination, ultrasonography of the head and neck with particular attention to the parotid region, and in some cases computed tomography or magnetic resonance imaging. Preoperatively, the function of the facial nerve was assessed clinically using the House-Brackmann grading system¹³ and by electromyography of the facial nerve.

Surgical modalities for all study patients were classified into four groups: extracapsular dissection, partial superficial parotidectomy, superficial (or lateral) parotidectomy, and complete parotidectomy. Because the descriptions of the different surgical techniques of parotidectomy vary greatly in the relevant literature,³ this classification system was based on the (intention of) exposure of the main facial nerve trunk and the extent of resection of the parotid gland, as proposed by relevant literature reports.^{3,9} An extracapsular dissection was defined as removal of a tumor, preserving its capsule without exposure of the main trunk of the facial nerve. This modality was indicated in cases of a single and mobile lesion with preoperative clinical and imaging signs of a benign tumor and a location within the lateral lobe of the parotid gland. Furthermore, it was performed via an extended submandibular incision, in rare cases of tumors arising from the pharyngeal prolongation of the parotid gland and location in the deep parapharyngeal space, after sectioning of the posterior belly of the digastric muscle in most cases. If the main trunk was deliberately exposed before tumor dissection, the procedure was designated as a partial superficial parotidectomy, because parts of the superficial lobe were left in place. Removal of the entire superficial lobe was defined as a

superficial (or lateral) parotidectomy, whereas extirpation of the entire gland was referred to as a total parotidectomy.¹¹ In all cases, neuromonitoring was performed to identify and protect the main trunk or the branches of the facial nerve. This consisted of an electrical stimulation probe and two electrodes for conducting the action potentials of the orbicularis oculi and orbicularis oris muscles. In the beginning, stimulation was carried out with a maximum current of 5 mA. As soon as a branch of the facial nerve was identified by positive stimulation, the stimulating current was reduced to 2 mA. After exposure of a branch of the facial nerve, the current was reduced further to 1 mA or less.

Statistical analysis was performed using the χ^2 test with 95% confidence intervals (CIs). The software SPSS version 21 for Windows (SPSS, Inc., Chicago, IL) was used for the analysis. A *P* value of <.05 was considered statistically significant.

RESULTS

A total of 1,624 patients were included in the study (873 men, 751 women; male:female ratio, 1.16:1). Their mean age was 54 years (range, 1–90 years). The distribution of the different surgical modalities in the total population and the development of different procedures over time are shown in Table I. Information on tumor pathology is shown in Table II. The biggest solitary lesion in our sample was 6 cm. Figure 1 shows the development of surgical modalities over time, and Figure 2 shows the progression of the total number of parotidectomies in relation to the number of extracapsular dissections. The incidences of facial palsy (temporary or permanent) and Frey's syndrome over time are shown in Figures 3 and 4, respectively. The incidence of permanent facial palsies and Frey's syndrome, broken down according to extracapsular dissections and other surgical modalities, are shown in Figures 5 and 6, respectively. Statistical analysis of our data revealed a statistically significantly higher risk of development of permanent facial palsy (9.8% by the nonextracapsular dissection cases, 1.9% by extracapsular dissections; odds ratio [OR]: 5.723, 95% CI: 3.271-10.014, *P*<.001) and Frey's syndrome (OR: 9.186, 95% CI: 3.929-21.476, *P*<.001) as a result of the more invasive surgical modalities (partial superficial parotidectomy, superficial parotidectomy, complete parotidectomy) compared with the extracapsular dissections. An analysis of the 217 cases with partial superficial parotidectomy revealed a permanent facial

TABLE II.

Total Number of Different Tumor Pathologies in Our Study Sample.

Pathology	No.
Pleomorphic adenoma	591
Adenolymphoma (Warthin)	562
Parotid cyst	114
Basal cell adenoma	69
Parotid lymph node	64
Lipoma	59
Circumscribed chronic parotitis	56
Oncocytoma	26
Hämangioma	9
Myoepithelioma	9
Neurinoma	5
Monomorphic adenoma	4
Schwannoma	2
Rare entities (e.g., canalicular adenoma)	54
Total	1,624

nerve palsy incidence of 2.7%, not statistically significantly higher in comparison to the extracapsular dissections (1.9%, $P = .422$). From the 15 patients with permanent facial palsy after extracapsular dissection over the 12 years of our study, 14 had a grade II (House-Brackmann classification) and one grade III.

DISCUSSION

A review of the relevant literature and historical data from the 1960s to 1970s from our department leads to the conclusion that the surgical approach of choice for parotid benign lesions demonstrates a sinusoid course over time. An upward shift can be seen from the no longer acceptable tumor enucleation to the surgical minimum of standard and obligatory facial nerve dissection,

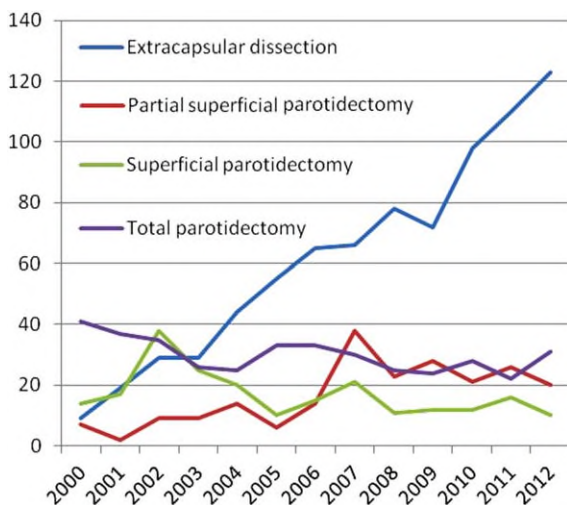


Fig. 1. Progression of each surgical modality over the years. [Color figure can be viewed in the online issue, which is available at www.laryngoscope.com.] [Color figure can be viewed in the online issue, which is available at www.laryngoscope.com.]

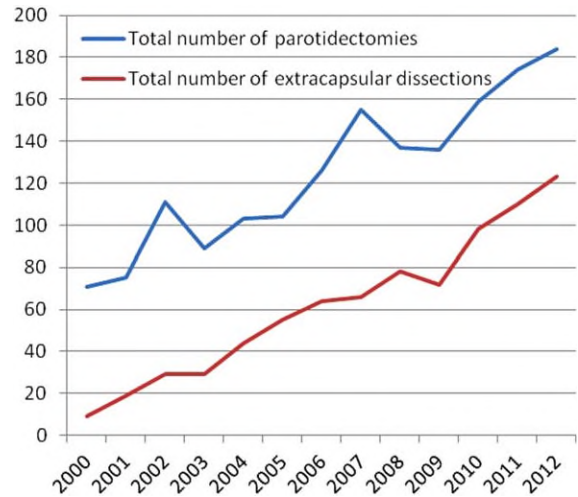


Fig. 2. Progression of total number of parotidectomies and extracapsular dissections over the years. [Color figure can be viewed in the online issue, which is available at www.laryngoscope.com.]

balancing out today on the level of extracapsular dissection, with the concept of a minimally invasive but still oncologically safe procedure. Several issues dealing with a wish for a more cosmetically appealing result, such as the retroauricular facelift incision (rhytidectomy incision)^{14–16} and modifications in the intraparotidial approach to the tumor, such as the cruciate incision of the parotid fascia,¹⁷ have been proposed. Furthermore, several opinions as to the acceptable thickness of the tissue layer around the tumor or the allowed percentage of capsule exposure of the tumor in extracapsular dissections, especially in pleomorphic adenomas,¹⁸ have been mentioned. In each case, as extracapsular dissection is not defined from the facial nerve as a landmark but is indicated on the basis of the individual clinical

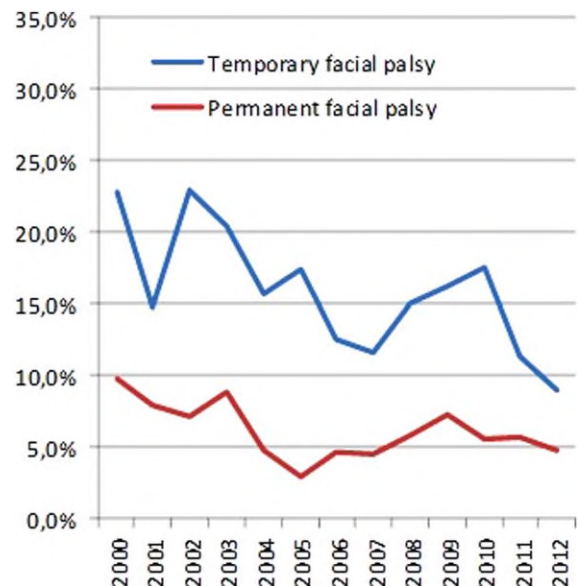


Fig. 3. Incidence of temporary and permanent facial palsy over the years. [Color figure can be viewed in the online issue, which is available at www.laryngoscope.com.]

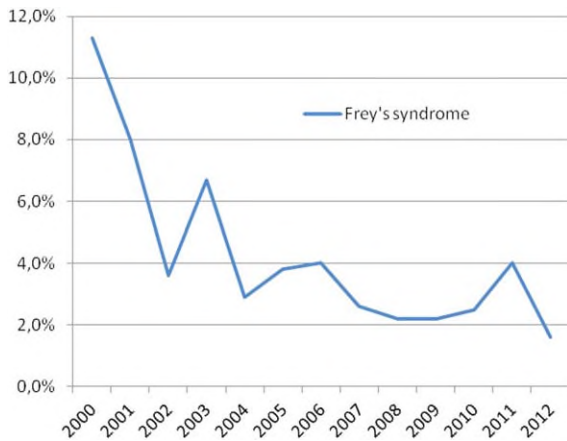


Fig. 4. Incidence of Frey's syndrome over the years. [Color figure can be viewed in the online issue, which is available at www.laryngoscope.com.]

(unilocularity, location, depth, motility) and radiologic tumor entities (lack of suspicion of malignancy), this modality conforms to the philosophy of individualized surgery and to the model of personalized medicine.

The descriptive analysis of our data demonstrates an impressive increase in the total number of parotidectomies for benign lesions from 71 surgeries (2000) to 184 (2012), which may be attributed to the improvement of diagnostic imaging tools (ultrasound), the introduction of ultrasound diagnostics in our routine practice, and the growing experience and expertise in minimally invasive surgical modalities in our department (Table I). It can also be seen that the increase in the total number of surgeries is mostly due to the increase in the number of extracapsular dissections (from 9 to 123, from 71 to 184; Fig. 2) that were referred to our department. Logically, increasing experience with extracapsular dissection brought a rapid expansion of its spectrum of indications over time and a progressively rarer intraoperative switch to more radical procedures, which was also technically facilitated by the possibility of intraoperative use of a portable ultrasound system in our department.¹⁹

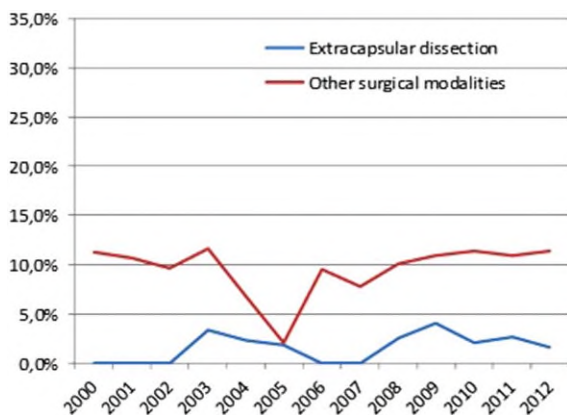


Fig. 5. Incidence of permanent facial palsies by extracapsular dissections and other surgical modalities over the years. [Color figure can be viewed in the online issue, which is available at www.laryngoscope.com.]

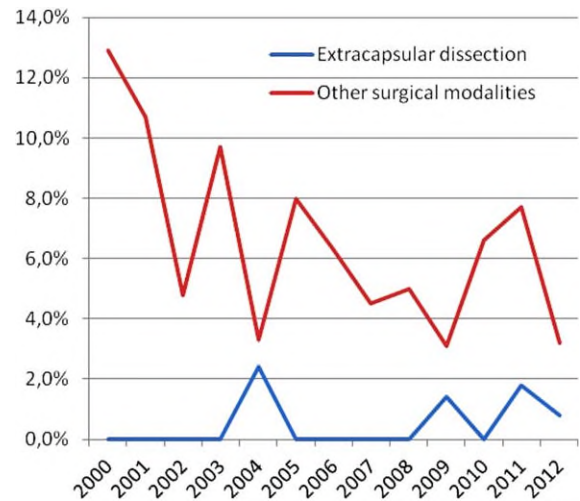


Fig. 6. Incidence of Frey's syndrome by extracapsular dissections and other surgical modalities over the years. [Color figure can be viewed in the online issue, which is available at www.laryngoscope.com.]

In detail, the number of less radical tumor-defined modalities (extracapsular dissection and partial superficial parotidectomy) rose from 16/71 (22.5%) to 143/184 (77.7%). This three-fold percentage increase in minimally invasive procedures is indicative of the impressive change in the philosophy and the strategy concerning the therapeutic approach to benign parotid tumors. Interestingly, total parotidectomies showed a slightly decreasing tendency, but in total remained stable over 12% of the total number of surgeries each year. The latter could be explained by the fact that a total parotidectomy has an established status and solid indications in cases of benign parotid lesions. In our department, it was considered as the modality of choice for multilobar adenolymphomas as well as benign tumors of the deep lobe of the parotid gland. As a result, total parotid gland resection retained its position in our therapeutic concept over the years.

Undoubtedly, the most significant complication in the surgical treatment of benign parotid tumors is postoperative facial palsy, with a severe negative impact on the postoperative functional outcome.²⁰ According to the relevant literature, the rate of temporary postoperative facial nerve paresis is reported to be as high as 15% to 25% after superficial parotidectomy and 20% to 50% after total parotidectomy, whereas the overall rate of permanent facial nerve paresis is reported as 5% to 10%.^{3,21-23} Our descriptive analysis showed that increasing performance of less radical surgical procedures over the years is associated with a significantly decreasing incidence of temporary and permanent facial palsies (22.8% to 9% and 9.8% to 5.9%, respectively). Interestingly, statistical analysis of our data revealed a statistically significant more than 5 times higher risk of development of a permanent facial palsy as a result of the other surgical modalities. It therefore appears that a dissection of the tumor instead of primary dissection of the facial nerve leads to significantly less facial nerve

morbidity, with an essential benefit for the patients' postoperative quality of life.

Among the most serious sequelae of parotidectomy with significant potential negative social and psychological implications is Frey's syndrome.²⁴ One of the most recognized risk factors for postoperative development of this syndrome is the amount of parotid gland tissue removed.^{24,25} Following the department's philosophy, it was always our goal to minimize the parotid wound bed and the extent of parotidectomy to prevent Frey's syndrome. Furthermore, every case involved sub-superficial musculoaponeurotic system elevation of the skin flap and formation of a thick skin flap. No other adjunctive techniques were used, and this allowed further analysis of this issue (use of adjunctive techniques in only some cases would have possibly affected the possibility/risk of Frey's syndrome and would therefore have interfered with our results). Reports of lower rates after partial superficial parotidectomy or extracapsular dissection point to the same conclusion.²⁶⁻²⁸ Descriptive analysis of our study was in line with the literature reports: increasing performance of (and increasing expertise in) less radical procedures led to an almost 10 times lower incidence of Frey's syndrome over the years, from 8/71 (11.3%) in 2000 to 3/184 (1.6%) in 2012. Interestingly, according to the present analysis, a patient undergoing a more radical surgical modality (partial superficial parotidectomy, superficial parotidectomy, complete parotidectomy) is greater than nine times more likely to develop Frey's syndrome postoperatively compared with an extracapsular dissection. It is possible that the more residual glandular tissue there is, the higher the barrier is between regenerating postganglionic parasympathetic nerve fibers in the skin and in the parotid gland parenchyma. This is consistent with literature reports that adequate removal of the pathology with minimization of the parotid wound bed (as in extracapsular or partial superficial parotidectomy) may prevent Frey's syndrome.^{24,29}

It should be underlined that our descriptive study results may be influenced by factors such as the surgeons' experience and preferences and the patients' wishes. Our data review showed that over half of our extracapsular dissections were performed in the period 2009 to 2012. This finding may certainly lie in a possible learning curve associated with the technique, although it seems that in our total parotidectomy cases, certain tumor-related reasons rather than surgeon's preferences or inadequate expertise precluded an extracapsular approach. These possible selection biases should be taken into account when considering our observations. As mentioned above, an extracapsular dissection may be applied only in cases of a superficially located mobile lesion or in rare cases of pleomorphic adenomas arising from the pharyngeal prolongation of the parotid gland and location in the deep parapharyngeal space after sectioning of the digastric muscle (transcervical approach).³⁰ If we accept that the cases in which an extracapsular approach could be applied were distributed regularly over the years, we clearly see a change in philosophy, with a shift toward less radical surgical modalities over the years, with over 55% of extracapsular

dissections consistently being performed in the last 3 years of the study. Logically, this is clearly attributable to a strategic change rather than an increase in the incidence of the easier cases in the last years. This increase in the number of less-radical modalities should be considered as a result of progressively greater experience and knowledge in the behavior and biology of benign parotid tumors, as we believe that the same lesions as 12 years ago can now be treated adequately with far less radical surgery.

Our study shows that the rapidly increasing number of less-invasive modalities over time is associated with a significant improvement in the functional outcome of the patients. Additionally, in most of the cases, less-invasive procedures were proven to be comparatively less time consuming. In our view, an extracapsular dissection should be considered as an advanced modality, as it is an individualized, successive dissection in the parotid parenchyma around the tumor, under electromyographic monitoring of the facial nerve with the intention of not exposing and thus protecting the facial nerve, and without the help of any anatomic landmarks. In our experience, it can be very demanding intraoperatively. Consequently, the increase in extracapsular surgery should be considered to be the result of growing expertise in parotid surgery. In our opinion, one should be able to switch to a more radical procedure requiring dissection of the facial nerve and its branches if, for example, malignancy is detected in frozen sections of an extracapsular specimen. Interestingly, almost 3% of the nonextracapsular dissections in our study sample began as intended extracapsular dissections. Therefore, less radical modalities should be performed by surgeons who are able to find, recognize, and dissect the facial nerve if required.

CONCLUSION

One of the most controversial issues in otolaryngology lies in the question of which therapeutic approach is best in patients with benign tumors of the parotid gland. Our retrospective study indicates that an individualized treatment modality is justified, rather than a standardized surgical procedure. The choice of surgical approach can often be made in the operating room. Our study shows a clear shift toward less-invasive surgical procedures, without compromises in patient safety, functional outcome, or postoperative surgical complications. Increasing performance of extracapsular surgery should be seen as the result of rising expertise in parotid surgery, rather than an attempt to save operative time and costs. However, expertise in parotid surgery is insufficient without the ability to dissect the facial nerve.

Acknowledgments

The authors thank Mrs. Petra Güthlein for her valuable assistance in the collection and analysis of the data.

BIBLIOGRAPHY

1. Benedict E. Tumors of the parotid gland: a study of two hundred and twenty-five cases with complete end-results in eighty cases. *Surg Gynecol Obstet* 1930;51:626-647.

2. Rawson AJ, Howard JM, Royster HP, Horn RCJ. Tumors of the salivary glands: a clinicopathological study of 160 cases. *Cancer* 1950;3:445–458.
3. Klintworth N, Zenk J, Koch M, Iro H. Postoperative complications after extracapsular dissection of benign parotid lesions with particular reference to facial nerve function. *Laryngoscope* 2010;120:484–490.
4. Patey D, Thackray A. The treatment of parotid tumours in the light of a pathological study of parotidectomy material. *Br J Surg* 1958;45:477–487.
5. Janes R. The treatment of tumors of the salivary gland by radical excision. *Can Med Assoc J* 1940;43:554–559.
6. Rehberg E, Schroeder H, Kleinsasser O. Surgery in benign parotid tumors: individually adapted or standardized radical interventions [in German]? *Laryngorhinootologie* 1998;77:283–288.
7. Roh J, Kim H, Park C. Randomized clinical trial comparing partial parotidectomy versus superficial or total parotidectomy. *Br J Surg* 2007;94:1081–1087.
8. Renehan A, Gleave EN, McGurk M. An analysis of the treatment of 114 patients with recurrent pleomorphic adenomas of the parotid gland. *Am J Surg* 1996;172:710–714.
9. George KS, McGurk M. Extracapsular dissection—minimal resection for benign parotid tumours. *Br J Oral Maxillofac Surg* 2011;49:451–454.
10. Albergotti WG, Nguyen SA, Zenk J, Gillespie MB. Extracapsular dissection for benign parotid tumors: a meta-analysis. *Laryngoscope* 2012;122:1954–1960.
11. Iro H, Zenk J, Koch M, Klintworth N. Follow-up of parotid pleomorphic adenomas treated by extracapsular dissection. *Head Neck* 2013;35:788–793.
12. McGurk M, Combes J. *Controversies in the Management of Salivary Gland Disease*. Oxford, UK: Oxford University Press; 2012.
13. House JW, Brackmann DE. Facial nerve grading system. *Otolaryngol Head Neck Surg* 1985;93:146–147.
14. Upile T, Jerjes WK, Nouraei SA, et al. Further anatomical approaches to parotid surgery. *Eur Arch Otorhinolaryngol* 2010;267:793–800.
15. Nouraei SA, Al-Yaghchi C, Ahmed J, et al. An anatomical comparison of Blair and facelift incisions for parotid surgery. *Clin Otolaryngol* 2006;31:531–534.
16. Grover N, D'Souza A. Facelift approach for parotidectomy: an evolving aesthetic technique. *Otolaryngol Head Neck Surg* 2013;148:548–556.
17. Kanatas A, Perisanidis C, Fabbioni G. Parotid extracapsular dissection—a modification of the cruciate parotid fascia incision. *Br J Oral Maxillofac Surg* 2013;51:570–571.
18. Makeieff M, Pelliccia P, Letois F, et al. Recurrent pleomorphic adenoma: results of surgical treatment. *Ann Surg Oncol* 2010;17:3308–3313.
19. Angerer F, Zenk J, Iro H, Bozzato A. Use of a portable ultrasound system in the perisurgical assessment of head and neck patients [in German]. *HNO* 2013;61:866–871.
20. Nitzan D, Kronenberg J, Horowitz Z, et al. Quality of life following parotidectomy for malignant and benign disease. *Plast Reconstr Surg* 2004;114:1060–1067.
21. Zernial O, Springer IN, Warnke P, Harle F, Risick C, Wiltfang J. Long-term recurrence rate of pleomorphic adenoma and postoperative facial nerve paresis (in parotid surgery). *J Craniomaxillofac Surg* 2007;35:189–192.
22. McGurk M, Renehan A, Gleave EN, Hancock BD. Clinical significance of the tumour capsule in the treatment of parotid pleomorphic adenomas. *Br J Surg* 1996;83:1747–1749.
23. Guntinas-Lichius O, Klussmann JP, Wittekindt C, Stennert E. Parotidectomy for benign parotid disease at a university teaching hospital: outcome of 963 operations. *Laryngoscope* 2006;116:534–540.
24. de Bree R, van der Waal I, Leemans CR. Management of Frey syndrome. *Head Neck* 2007;29:773–778.
25. Koch M, Zenk J, Iro H. Long-term results of morbidity after parotid gland surgery in benign disease. *Laryngoscope* 2010;120:724–730.
26. Witt RL. Minimally invasive surgery for parotid pleomorphic adenoma. *Ear Nose Throat J* 2005;84:308, 310–301.
27. McGurk M, Thomas BL, Renehan AG. Extracapsular dissection for clinically benign parotid lumps: reduced morbidity without oncological compromise. *Br J Cancer* 2003;89:1610–1613.
28. Smith SL, Komisar A. Limited parotidectomy: the role of extracapsular dissection in parotid gland neoplasms. *Laryngoscope* 2007;117:1163–1167.
29. Witt RL. The significance of the margin in parotid surgery for pleomorphic adenoma. *Laryngoscope* 2002;112:2141–2154.
30. Mendelsohn AH, Bhuta S, Calcaterra TC, Shih HB, Abemayor E, St John MA. Parapharyngeal space pleomorphic adenoma: a 30-year review. *Laryngoscope* 2009;119:2170–2174.