

# Thyroglossal duct cysts: 20 years' experience (1992–2011)

Julie de Tristan · Johannes Zenk · Julian Künzel ·  
Georgios Psychogios · Heinrich Iro

**Abstract** The objective of the present study is to report on the clinical course and management of thyroglossal duct cysts. Retrospective review of all patients who underwent surgery for thyroglossal duct cysts between 2000 and 2013 at a tertiary referral center was carried out. The operations were performed using a modification of the Sistrunk operation: transcervical cystectomy, partial dissection of the hyoid bone, and dissection of all tracts identified during surgery. A total of 352 patients (176 men, 176 women) underwent surgery for a cyst ( $n = 282$ ) or discharging sinus ( $n = 70$ ). The mean age for the incidence of cysts was 26 years. Four of the patients (1.4 %) had a papillary thyroid carcinoma in the epithelium of the cyst. The follow-up period ranged from 7 months to 10 years. The overall recurrence rate was 4.5 %. Resection is often regarded as an elective surgical procedure in patients with thyroglossal duct cysts, but surgery should always be considered. Papillary thyroid carcinoma in the epithelium of the cyst is a rare but possible differential diagnosis. Dissection of all tracts found is recommended and partial dissection of the hyoid bone is mandatory. Dissection of the foramen cecum is not imperative. The recurrence rates with this approach are comparable to more extensive methods such as those described by Sistrunk.

**Keywords** Thyroglossal duct cyst · Fistula · Discharging sinus · Sistrunk · Neck abnormalities · Congenital neck mass · Ultrasound · Thyroid carcinoma

## Introduction

Thyroglossal duct cysts are the most common congenital anomalies in the neck. They arise from epithelial remnants of the thyroglossal duct [1]. There are two common theories concerning the embryology of the lesions. In the traditional theory, the cyst is regarded as a remnant of the thyroglossal duct. The thyroid originates in the third week of fetal life at the level of the foramen cecum and descends in the neck, passing anterior to the hyoid bone. As the gland moves caudally, a tubular structure—the thyroglossal tract—is left behind. This duct normally regresses by gestational week 10 [2–4]. A persistent duct can lead to a cervical cyst. Otto considered that physiological rupture of the thyroglossal tract may occur as the thyroid ascends from the thorax into the neck. Due to local intraepithelial adhesion, proliferation of a specific cell type occurs. Rupture of the tract can lead to ectopic thyroid tissue, an epithelial cyst, or goiter of the tongue base, depending on the cell type induced [5].

Discharging sinuses are considered a secondary feature after spontaneous drainage or incomplete surgical removal of a thyroglossal cyst [6, 7]. The term “thyroglossal fistula” is often incorrectly used to refer to the sinus, although there is no fistulous tract connecting the base of tongue with the surface of the skin [6]. Although the embryological entity is the same as in thyroglossal cyst, these are described as sinuses because the clinical presentation differs.

Thyroglossal duct cysts commonly present as painless structures located in the midline, on or slightly below the

---

J. de Tristan (✉) · J. Zenk · J. Künzel · G. Psychogios · H. Iro  
Department of Otorhinolaryngology, Head and Neck Surgery,  
University of Erlangen–Nuremberg Medical School,  
Waldstrasse 1, 91054 Erlangen, Germany  
e-mail: julie.detristan@uk-erlangen.de

hyoid bone. They can also be found along the former course of the embryological thyroid duct.

Preoperative imaging with ultrasound, computed tomography (CT), or scintigraphy is recommended in order to evaluate the cyst itself, the thyroid gland, and possible ectopic thyroid tissue [8]. Open surgical excision is the treatment of choice. Sistrunk was the first to provide a systematic description of a surgical technique for thyroglossal duct cysts, in 1928 [9]. The procedure consists of transcervical cystectomy, resection of the central part of the hyoid bone, and resection of the foramen cecum. Alternative methods, such as endoscope-assisted intraoral resection of the thyroglossal duct cyst, have also been described [10]. The aim of the various surgical techniques is to remove pathological structures completely and prevent recurrences.

This retrospective study describes experience at our institution with the treatment of thyroglossal duct cysts and analyzes several outcome measures such as recurrence rates, complications, and the long-term follow-up. The relevant literature is reviewed.

## Patients and methods

All patients who underwent surgery for a thyroglossal duct cyst in the university otorhinolaryngology department between January 1, 1992 and December 31, 2011 were included in the analysis. Both children and adults are treated in the department. Only patients in whom a thyroglossal duct cyst was confirmed histologically were included. A total of 352 patients were identified retrospectively, and the data used in the study were derived from patients' records. A structured data extraction form was used to retrieve demographic characteristics, clinical presentation, and preoperative diagnostic findings. The characteristics of the operation, postoperative course, and histopathologic findings were analyzed. Patients were contacted in July 2012 by phone and questionnaires were used to obtain follow-up information (e.g., about complications, postoperative disorders, and recurrences). Standard preoperative diagnostic procedures included a clinical ear, nose, and throat (ENT) examination and an ultrasound examination. Operations were performed using a modification of the Sistrunk procedure [9]. This includes transcervical cystectomy under general anesthesia. The cysts were dissected cranially to the hyoid bone. The hyoid bone was exposed, and the central third excised. The hyoid was usually the superior limit of the dissection, but all tracts identified during surgery were dissected. Only in case of a visible tract toward the foramen cecum did the excision include any part of the surrounding muscles.

From the data obtained in the survey, a computer database was generated using Microsoft Excel 2007 and was used for descriptive statistical analysis.

## Results

A total of 352 patients (176 men, 176 women) were identified who had undergone surgery for a thyroglossal duct cyst ( $n = 282$ ) or discharging sinus ( $n = 70$ ). The mean age for the occurrence of cysts was 29 years (range 1–78, median 27) and the mean age for the development of a discharging sinus was 14 years (range 0–64 years, median 7 years) (Fig. 1). The mean ages at surgery were 31 years (median 22) for cysts and 17.5 years (median 12) for discharging sinuses. Twenty-one percent of the patients had undergone surgery elsewhere before presenting at our department with recurrences, and they had experienced between one and four recurrences (Fig. 2).

Seventy-two percent of the cysts were located in the midline; 12 % of the lesions were in paramedian right locations and 16 % were in paramedian left locations. The structure was located caudal to the hyoid bone in 42 % of the patients, at the same level as the hyoid in 28 %, and cranial to it in 26 %. Three percent of the lesions were located cranial to the thyroid gland. Three cysts were located cranial to the upper sternum.

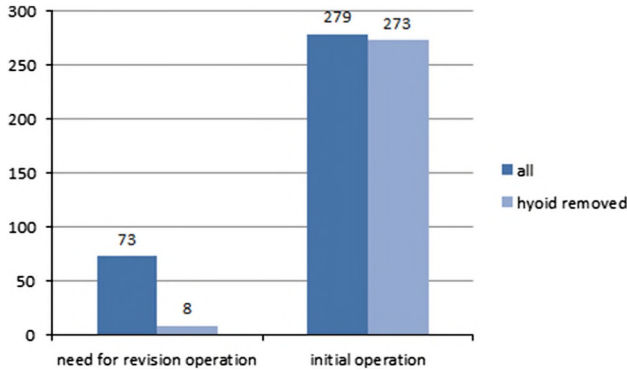
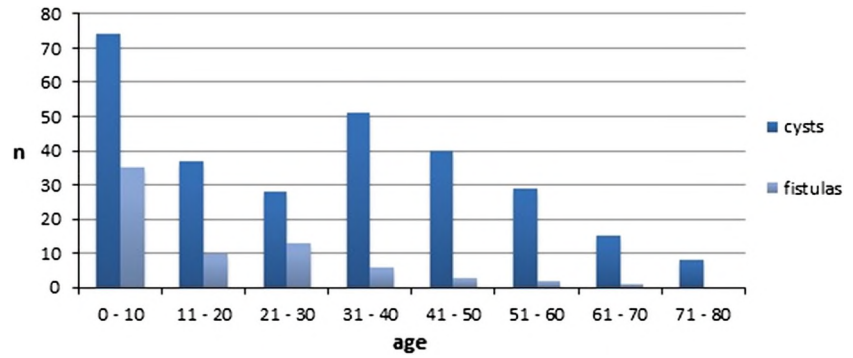
The discharging sinuses were congenital in 7 % of cases ( $n = 5$ ), spontaneous in 7 % ( $n = 5$ ), and arose from an infected cyst in 7 % ( $n = 5$ ). The discharging sinus developed iatrogenically after interventions for a cyst such as puncture or biopsy in 59 % of the cases ( $n = 41$ ). One patient had a family history suggestive of thyroglossal duct cyst. Fifteen percent of the patients reported that the cyst first appeared concurrently with an infection of the upper airways (10 %) or other infections such as measles, scarlet fever, toxoplasmosis, and Epstein–Barr virus (5 %). Common symptoms and clinical manifestations at the time of presentation in our department are presented in Tables 1 and 2. The most common symptoms were swelling and infection with drainage.

A preoperative ultrasound examination was performed in 97 % of the patients. Definitive diagnosis of a thyroglossal duct cyst was made in 89 % of the patients using ultrasound as the only imaging method. Ultrasound examinations were also carried out to exclude an atypical location or agenesis of the thyroid gland. These were not found in any of the patients.

Fifty-nine patients had supplementary examinations performed before presenting at the department: scintigraphy ( $n = 20$ ), magnetic resonance imaging (MRI,  $n = 12$ ), and CT ( $n = 8$ ). Additional diagnostic investigations were performed in the department in 4 % of the patients to exclude malignant causes of the cysts: CT in five patients, MRI in one patient, and scintigraphy in six patients.

Local infection was treated with antibiotics in 80 % of cases. Puncture of the cyst or immediate surgery was

**Fig. 1** Age of incidence of thyroglossal cysts



**Fig. 2** Initial vs. revision operation

**Table 1** Clinical symptoms of thyroglossal cysts

	Cysts		Discharging sinuses	
	n	%	n	%
Swelling	280	99.0	57	81.0
Constant	142	50.4	28	40.0
Growing	72	25.5	4	5.7
Intermittent	66	23.4	25	35.7
Feeling of pressure	103	36.5	13	18.6
Pain	85	30.1	15	21.4
Infection	58	20.6	34	49.0
Drainage	1	0.4	53	75.7
Dysphagia	66	23.4	5	7.1
Dysphonia	4	1.4	2	2.9
Dyspnea	1	0.4	0	–
No symptoms	2	0.7	0	–

performed in 11 %. Perioperative infection was present in 5.7 % of the cysts and 20 % of the discharging sinuses.

Surgery was performed a mean of 11.5 weeks after the patient's first appointment in the hospital in the case of cysts and after 22 weeks in the case of discharging sinuses. Neonates presenting with uninfected discharging sinuses did not undergo surgery within the first 12 months.

**Table 2** Clinical manifestations of thyroglossal cysts

	Cysts		Discharging sinuses	
	n	%	n	%
Moves cephalad with swallowing	59	21	16	37
Freely mobile	187	66	13	19
Tenderness on palpation	54	19	15	21
Firm on palpation	187	66	22	31
Acute infection	30	11	21	30

Partial dissection of the hyoid bone is an essential step in the operation. The hyoid had been removed previously in 11 % of the patients with prior surgery. In the remaining patients, the central part of the hyoid bone was included in the excision in 98.3 % of cases (Fig. 2).

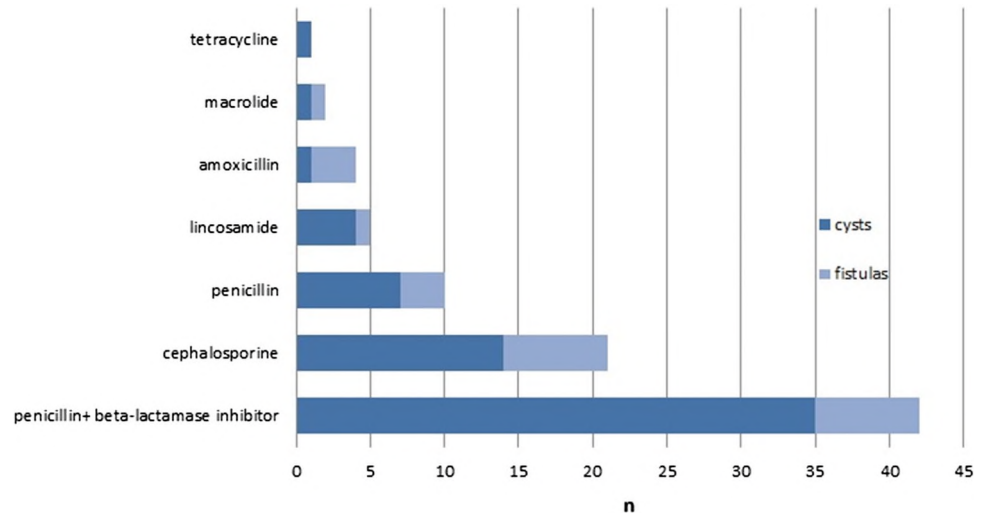
A duct-like structure was found in 89.4 % of the cysts ( $n = 252$ ). Eighty percent of the structures were in direct anatomic contact with the hyoid bone. Attachment of the thyroglossal duct to the foramen cecum was observed in 14 % of cases, and 12 % of the cysts were located near the thyroid gland. A blind terminal duct was seen in 5 %. Only 1 % of the cysts were located in the submental region.

Thirty-two percent of the cysts were opened accidentally, or in order to reduce their volume during the operation. Perforation of the pharynx occurred in one patient, who received a nasogastric tube for 48 h. A surgical drain was placed during the operation in 99 % of the patients.

Perioperative antibiotic prophylaxis was administered in patients who had acute infections or were at risk of pharyngeal perforation. Detailed results are shown in Fig. 3.

Eight percent of the patients developed postoperative seroma or hematoma. Postoperative bleeding occurred in three patients. Wound infection was reported in 16 patients. One patient developed septicemia during the in-patient stay. Nine patients (2.6 %) required revision surgery due to the complications. An emergency tracheotomy was performed in one patient due to a pharyngeal hematoma. No complications were observed in 303 patients (86.1 %). There was no correlation between the recurrence rate and complications.

**Fig. 3** Perioperative antibiotics



**Table 3** Detailed histopathological examination

	Cysts		Discharging sinuses		All (%)
	n	%	n	%	
Acute inflammation	29	10.3	11	15.7	11.4
Chronic inflammation	174	61.7	40	57.0	60.8
Columnar epithelium	93	33.0	30	43.0	34.0
Squamous epithelium	80	28.4	27	38.6	30.4
Ciliated epithelium	62	22.0	7	10.0	19.6
Not classified	82	29.0	17	24.3	28.1
Thyroid tissue	108	38.3	14	20.0	34.7
Papillary thyroid carcinoma	4	1.4	0	–	–
Thyroid adenoma	1	0.4	0	–	–

All of the excised cysts were sent for histopathologic examination. The wall was usually lined with columnar and squamous epithelium, and ciliated epithelium was found in 19.6 %. Thyroid tissue was found in 34.7 %. Findings showing chronic inflammation were seen in 60.8 % of the patients and acute inflammation was noted in 11.4 %. Detailed results are shown in Table 3. Four of the patients with cysts (1.4 %) were found to have papillary thyroid carcinomas in the epithelium:

- A 37-year-old woman with a swelling in the midline that had been painless for 12 months but was growing. Ultrasound showed an inhomogeneous cystic lesion. Total thyroidectomy was performed, and there was no further carcinoma.
- A 59-year-old woman with a left paramedian swelling that had been painless for 3 months but was growing. She had previously been treated for Hashimoto's thyroiditis. Ultrasound showed an inhomogeneous cystic lesion and a hypotrophic thyroid gland. Total

thyroidectomy was not performed due to the hypotrophic thyroid gland.

- A 31-year-old woman with a swelling in the midline that had been painless for 12 months. Ultrasound showed an inhomogeneous cystic lesion. Total thyroidectomy was performed in another hospital, and there was no further carcinoma.
- A 56-year-old healthy man, with a left paramedian submandibular swelling that had been painless for 12 months. Ultrasound showed an inhomogeneous cystic lesion. In a second step, total thyroidectomy was carried out (with no carcinoma) and radioiodine therapy was administered.

The follow-up period in the department ranged from 7 months to 10 years. Sixty percent of the patients were contacted by phone. The overall recurrence rate was 4.5 % (cysts 3.6 %, discharging sinus 8.6 %). All recurrences were operated on a second time. Further operations were not necessary. Nine of the recurrent cysts (90 %) were associated with opening of the cyst during the first operation, and two of the patients (20 %) had no excision of the central part of the hyoid bone. All of the patients with recurrent discharging sinuses had undergone excision of the hyoid, and two of them (33 %) had an intraoperative infection of the discharging sinus. None of the patients with papillary carcinoma in the cyst had any recurrences (with 100 % follow-up). None of the patients with a discharging sinus had a fistulous tract connecting the base of tongue and the skin surface.

## Discussion

Thyroglossal duct cysts are common benign lesions of the neck. In the present study, the ratio of cysts to discharging

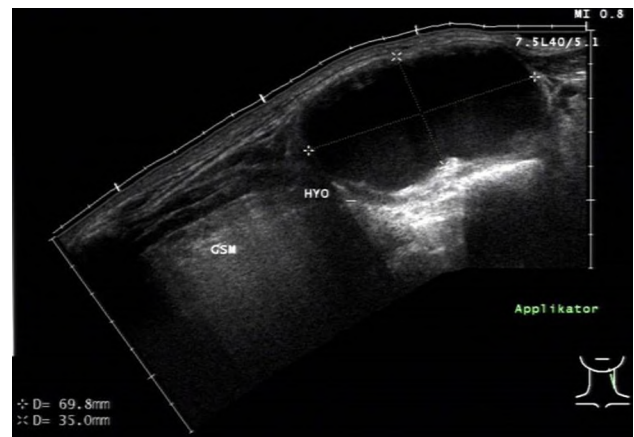
sinuses was 1:4. This corresponds to the figures given in the literature review by Allard [11]. The gender ratio was balanced (1:1). The mean age for the incidence of cysts was 29 years. Only 23 % of the patients reported having had symptoms before the age of 18 years. The onset of symptoms was after the age of 30 in half of the patients and even after the age of 50 in 18.4 %. This demonstrates that thyroglossal duct cervical cysts do not exclusively affect a pediatric population [12]. However, 50 % of the patients with discharging sinuses were under the age of 19, 70 % were younger than 18, and their mean age was 14 years.

Seventy-two percent of the cysts were located in the midline, 12 % on the paramedian right, and 16 % paramedian left.

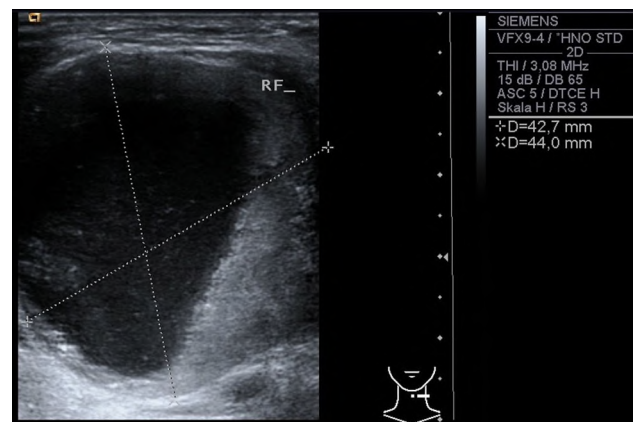
Two cervical cysts occurred within a single family. A review of the literature shows that worldwide, a total of 21 patients with hereditary thyroglossal duct cysts in seven families have been reported [13]. In the present authors' view, the two cases occurring in one family represent a coincidence rather than a family trend.

The discharging sinuses developed iatrogenically secondary to cyst interventions such as puncture or biopsy in 59 % of the patients. This finding has frequently been described in the literature [9, 14]. Puncture should therefore be avoided. Seven percent of the cases of discharging sinus in the present study were considered to be congenital. This is in contrast to the opinions of some authors, who have stated that discharging sinus cannot be explained embryologically, as the thyroglossal duct does not have any contact with the ectoderm [11, 15, 16].

Ultrasound is an inexpensive tool available to ENT surgeons [8, 17]. Preoperative ultrasound examinations were carried out in 97 % of the patients in this study. The primary goals of the examination were to confirm the suspected diagnosis and assess any malignancy and the anatomic relationship of the cyst to the hyoid bone (Fig. 4). The diagnosis of a thyroglossal duct cyst was not definitively confirmed after ultrasound in only 11 % of cases. Another goal with ultrasound was to assess the location of the thyroid gland and ectopic thyroid tissue. No agenesis of the thyroid gland was found in any of the patients. This shows that there is a need for discussion regarding the imaging method to be employed. Preoperative imaging and assessment of the thyroid are generally recommended in the literature, but there is no consensus regarding the method of choice [8, 16–20]. Ultrasound is one of the most sensitive techniques for identifying the thyroid gland [21]. In the present authors' view, clinical criteria for determining the risk of malignancy such as calcification, inhomogeneities, and wall thickening can also be displayed on ultrasound (Fig. 5), which is therefore the best choice for preoperative examinations. Further investigations are needed to determine whether or not ultrasound is more



**Fig. 4** Typical ultrasound image of a thyroglossal duct cyst



**Fig. 5** Ultrasound image of a “thyroglossal cyst.” The histopathologic examination revealed a papillary thyroid carcinoma

sensitive or specific than other imaging methods such as CT or MRI [8].

The central part of the hyoid bone was included in the excision of the epithelium in 96 % of the patients. A duct-like structure was found in 89.4 % of the cysts. All ducts that were identified during surgery were resected, with a modification of the Sistrunk technique. The foramen cecum was only excised as well if there was a tract coursing toward it. In the classic Sistrunk operation, cysts with a duct coursing toward the thyroid gland would not have been completely removed. This finding was also seen by Patel et al. [21], who dissected supplementary tissue between the hyoid and thyroid. Sistrunk [9] and others [12, 22, 23] criticized this method for being associated with a greater risk of rupture and nondissemination of microscopic ducts. In view of the recurrence rate of 4.5 % in the present study, the outcome with the technique used is comparable with that of the classical Sistrunk operation described in the literature (Table 4) [23–26]. Intraoperative opening of the cyst occurred during the first

**Table 4** Literature review

References	Year	Cysts ( <i>n</i> )	Operation	Hyoid bone resection	Recurrence rate (%)	Preoperative evaluation
Bennett [24]	1986	37	Sistrunk	Yes	2.7	–
Bennett [24]	1986	20	Modified Sistrunk <sup>a</sup>	Yes	0	–
Bennett [24]	1986	7	Cystectomy	No	33.0	–
Hoffman [25]	1988	90	Sistrunk	Yes	8.8	
Ducic [23]	1998	108	Sistrunk	Yes	11.1	–
Brousseau [26]	2003	62	Sistrunk	Yes	3.2	CT and US
Present study	2013	352	Modified Sistrunk <sup>a</sup>	Yes	4.5	US

CT computed tomography, US ultrasonography

<sup>a</sup> Resection of the cyst, infrahyoid tract, and mid-portion of the hyoid bone

operation in 90 % of the recurrent cysts. This may be an indicator of a difficult intraoperative site and residual tissue. Care should be taken not to rupture the cyst, as this may lead to incomplete removal [27].

Revision surgery was needed in 2.6 % of the patients due to complications such as hematoma, bleeding, and wound infection. Severe complications are rare [28].

A detailed histopathologic examination should always be performed. The results in the present study were consistent with those in the literature. Thyroid tissue is a frequent component of the cyst, but its absence does not exclude a diagnosis of thyroglossal duct cyst [1, 11, 28–30]. Chronic or acute inflammation was found in 72.2 % of cases. Von Bismarck and Höllwarth [31] reported that they found chronic inflammation in 45 % of noninfected cysts. This may be explained by subclinical infections.

In four patients (1.4 %), a papillary thyroid carcinoma was found in the thyroglossal duct cervical cyst. Case reports have been published describing squamous cell carcinoma, follicular carcinoma, and papillary follicular carcinoma [1, 11, 15, 32]. One patient had a thyroid adenoma inside the cyst. Other authors have also confirmed that it is challenging to differentiate between benign and malignant cervical cysts, as the symptoms are identical [24, 32–35]. On the basis of the 1.4 % rate of papillary carcinoma found in the cysts, particular attention should be given to elderly female patients and patients with fast-growing cysts and palpable lymph nodes. Total thyroidectomy was performed in three of the four patients with these findings, but a second papillary carcinoma was not found inside the thyroid gland in any of them. It might be argued that total thyroidectomy was performed unnecessarily in these cases, and the issue needs to be discussed with each patient.

## Conclusion

Thyroglossal duct cysts typically present in the pediatric age group, but most of the patients in the present study

were adults—showing that this clinical picture also needs to be included in the differential diagnosis in adults. Ultrasound is the method of choice for preoperative examination. Biopsies frequently lead to discharging sinuses and should be avoided. Resection of thyroglossal duct cysts is often considered to be an elective surgical procedure, but since it is always possible for thyroid carcinoma to be found in the cyst on histopathologic analysis, surgery should be considered generally, not only when there are symptoms. A detailed histopathologic analysis is indispensable. Dissection of all tracts found and also partial dissection of the hyoid bone are recommended. On the basis of the clinical follow-up and in comparison with the literature data, dissection of the foramen cecum is not imperative. Recurrence rates when this approach is used are comparable to those with more extensive methods.

**Conflict of interest** The authors hereby declare that there are no conflicts of interest.

## References

- Kelley DJ, Myer CM (1997) Congenital anomalies of the neck. In: Tewfik TL, Der Kaloustian VM (eds) Congenital anomalies of the ear, nose, and throat. Oxford University Press, New York, pp 331–360
- Moore KL, Persaud TVN, Torchia MG (2013) The developing human: clinically oriented embryology, 9th edn. Saunders/Elsevier, Philadelphia
- Sadler TW, Langman J (2012) Langman's medical embryology, 12th edn. Wolters Kluwer Health/Lippincott Williams & Wilkins, Philadelphia
- Reede DL, Bergeron RT, Som PM (1985) CT of thyroglossal duct cysts. *Radiology* 157:121–125
- Otto HD (1994) Teratogenic and clinical aspects of abnormalities of the head and neck region. *Eur Arch Otorhinolaryngol Suppl* 1:15–100
- Foley DS, Fallat ME (2006) Thyroglossal duct and other congenital midline cervical anomalies. *Semin Pediatr Surg* 15:70–75
- Sattar AK, McRae R, Mangray S, Hansen K, Luks FI (2004) Core excision of the foramen cecum for recurrent thyroglossal duct cyst after Sistrunk operation. *J Pediatr Surg* 39:e3–e5

8. Ahuja AT, Wong KT, King AD, Yuen EH (2005) Imaging for thyroglossal duct cyst: the bare essentials. *Clin Radiol* 60:141–148
9. Sistrunk WE (1920) The surgical treatment of cysts of the thyroglossal tract. *Ann Surg* 71:121–122
10. So YK, Jeong JI, Youm HY, Jeong HS (2011) Endoscope-assisted intra-oral resection of the external thyroglossal duct cyst. *Am J Otolaryngol* 32:71–74
11. Allard RH (1982) The thyroglossal cyst. *Head Neck Surg* 5:134–146
12. Marianowski R, Ait Amer JL, Morisseau-Durand MP, Manach Y, Rassi S (2003) Risk factors for thyroglossal duct remnants after Sistrunk procedure in a pediatric population. *Int J Pediatr Otorhinolaryngol* 67:19–23
13. Schader I, Robertson S, Maoate K, Beasley S (2005) Hereditary thyroglossal duct cysts. *Pediatr Surg Int* 21:593–594
14. Radkowski D, Arnold J, Healy GB, McGill T, Treves ST, Paltiel H, Friedman EM (1991) Thyroglossal duct remnants. Preoperative evaluation and management. *Arch Otolaryngol Head Neck Surg* 117:1378–1381
15. Organ GM, Organ CH Jr (2000) Thyroid gland and surgery of the thyroglossal duct: exercise in applied embryology. *World J Surg* 24:886–890
16. Guarisco JL (1991) Congenital head and neck masses in infants and children. Part I. *Ear Nose Throat J* 70:40–47
17. Ahuja AT, King AD, Metreweli C (2000) Sonographic evaluation of thyroglossal duct cysts in children. *Clin Radiol* 55:770–774
18. Brewis C, Mahadevan M, Bailey CM, Drake DP (2000) Investigation and treatment of thyroglossal cysts in children. *J R Soc Med* 93:18–21
19. Dedititis RA, Camargo DL, Peixoto GL, Weissman L, Guimarães AV (2002) Thyroglossal duct: a review of 55 cases. *J Am Coll Surg* 194:274–277
20. Gupta P, Maddalozzo J (2001) Preoperative sonography in presumed thyroglossal duct cysts. *Arch Otolaryngol Head Neck Surg* 127:200–202
21. Patel NN, Hartley BE, Howard DJ (2003) Management of thyroglossal tract disease after failed Sistrunk's procedure. *J Laryngol Otol* 117:710–712
22. Horisawa M, Niinomi N, Nishimoto K, Matsunaga K, Ogura Y, Watanabe Y, Ando H (1999) Clinical results of the shallow core-out procedure in thyroglossal duct cyst operation. *J Pediatr Surg* 34:1589–1592
23. Ducic Y, Chou S, Drkulec J, Ouellette H, Lamothe A (1998) Recurrent thyroglossal duct cysts: a clinical and pathologic analysis. *Int J Pediatr Otorhinolaryngol* 44:47–50
24. Bennett KG, Organ CH Jr, Williams GR (1986) Is the treatment for thyroglossal duct cysts too extensive? *Am J Surg* 152:602–605
25. Hoffman MA, Schuster SR (1988) Thyroglossal duct remnants in infants and children: reevaluation of histopathology and methods for resection. *Ann Otol Rhinol Laryngol* 97:483–486
26. Brousseau VJ, Solares CA, Xu M, Krakovitz P, Koltai PJ (2003) Thyroglossal duct cysts: presentation and management in children versus adults. *Int J Pediatr Otorhinolaryngol* 67:1285–1290
27. Owen HR, Ingelby H (1927) Carcinoma of the thyroglossal duct. *Ann Surg* 85:132–136
28. deMello DE, Lima JA, Liapis H (1987) Midline cervical cysts in children. Thyroglossal anomalies. *Arch Otolaryngol Head Neck Surg* 113:418–420
29. Skurczynski W, Bruchmüller W (1968) Experiences following surgical therapy of neck fistulas and neck cysts from 1947–1966. *HNO* 16:353–359
30. Chandra RK, Maddalozzo J, Kovarik P (2001) Histological characterization of the thyroglossal tract: implications for surgical management. *Laryngoscope* 111:1002–1005
31. Von Bismarck S, Höllwarth ME (2001) Thyroglossal duct cysts in paediatric patients: early operative intervention reduces rate of complications. *Klin Padiatr* 213:295–298
32. Trail ML, Zeringue GP, Chicola JP (1977) Carcinoma in thyroglossal duct remnants. *Laryngoscope* 87:1685–1691
33. Baysungur SV, Okur E, Halezeroglu S, Atasalihi A (2002) Papillary carcinoma arising on cervico-mediastinal thyroglossal ductal cyst resected via transcervical and partial upper sternotomy incision. *Eur J Cardiothorac Surg* 22:842–844
34. Datar S, Patanakar T, Armao D, Mukherji SK (2000) Papillary carcinoma in a giant thyroglossal duct cyst. *Clin Imaging* 24:75–77
35. Naghavi SE, Jalali MM (2003) Papillary carcinoma of thyroglossal duct cyst. *Med Sci Monit* 9:CS67–CS70