

# Sialendoscopy-Assisted Microsurgical Repair of Traumatic Transection of Stensen's Duct

Michael Koch, MD, PhD; Heinrich Iro, MD; Alessandro Bozzato, MD, PhD; Johannes Zenk, MD

Sialendoscopy is established in the diagnostics and treatment of obstructive salivary gland diseases, but has not previously been reported in patients with injuries to Stensen's duct. Sialendoscopy assisted repair of a transected Stensen's duct in zone B is reported. The duct injury itself, its location, and its severity could be visualized and precisely assessed and allowed intraductal assessment of the ductal tissue. Rapid atraumatic dissection and also postoperative endoscopic follow-up examination with assessment of the anastomosis was provided by using the sialendoscope, which appears to be valuable for several reasons in the management of Stensen's duct trauma.

**Key Words:** Parotid gland, minimally invasive therapy, sialendoscopy, reconstruction, duct trauma.

## INTRODUCTION

Injuries to Stensen's duct are treated immediately or as early as possible by reconstruction of the duct. When treatment is delayed, reconstruction is more difficult and complications are more frequent. An attempt at reconstruction should be made in these cases as well, although treatment is sometimes not possible or is associated with unfavorable results.<sup>1-5</sup> Currently used diagnostic methods in ductal injuries<sup>1-5</sup> do not allow the direct visualization of the ductal system that is possible with sialendoscopy.

The precise location and extent of the ductal injury plays an important role in the planning of the surgical procedure. Treatment is dependent on the extent and location of duct damage (zone A-C). Complete transection of the main duct always necessitates early primary surgical exploration and microsurgical ductal reconstruction.<sup>1-5</sup>

Especially in zone B (the middle part crossing over the masseter muscle) ductal anastomosis and in cases of defects, reconstruction using a venous bridging graft should always be attempted. Various sutures (size 7-0 to

10-0) and various stents or catheters for temporary splinting of the duct have been used.<sup>6,7</sup> In case of severe tissue laceration, ablative treatment measures (duct ligation or parotidectomy) are the ultimate therapeutic options.

For endoscopic identification of lesions of Stensen's duct following a facelift, a successful endoscopically controlled treatment was described by Nahlieli et al.<sup>8</sup> No studies on the use of sialendoscopy in cases of traumatic injury to Stensen's duct have been published.

## CASE REPORT

Eight days after primary wound care for a laceration wound in the right cheek following trauma from a circular saw, a 33-year-old patient was referred due to salivary secretion in the wound area and persistent facial nerve paralysis in the upper lip area. A connection between the ductal system and skin surface was evident on ultrasonography, raising the suspicion of a salivary fistula (Fig. 1). Surgical exploration was carried out for a suspected traumatic transection of Stensen's duct with concomitant injury to buccal branches of the facial nerve. To investigate the duct system, a semiflexible sialendoscope with a diameter of 1.1 mm was used (Karl Storz GmbH, Tuttlingen, Germany) as described earlier.<sup>9,10</sup> Following introduction of the sialendoscope, transillumination with direct lighting led to rapid and atraumatic identification of the distal stump of the duct, and the epithelium in the ductal system was also assessed (Fig. 2). Following identification of the proximal ductal stump, the sialendoscope was also advanced in a bridging fashion into the proximal ductal system (Fig. 2). The condition of the epithelium and subsequent course of the duct were again assessed with direct visualization. Using the surgical microscope,

From the Department of Otorhinolaryngology-Head and Neck Surgery, Friedrich Alexander University of Erlangen-Nuremberg, Medical School, Erlangen, Germany.

The authors have no funding, financial relationships, or conflicts of interest to disclose.

Send correspondence to Michael Koch, MD, Hals-, Nasen-, Ohren-Klinik, Kopf- und Hals-Chirurgie, Friedrich-Alexander-Universität Erlangen-Nürnberg, Waldstrasse 1, 91054 Erlangen, Germany.  
E-mail: michael.koch@uk-erlangen.de

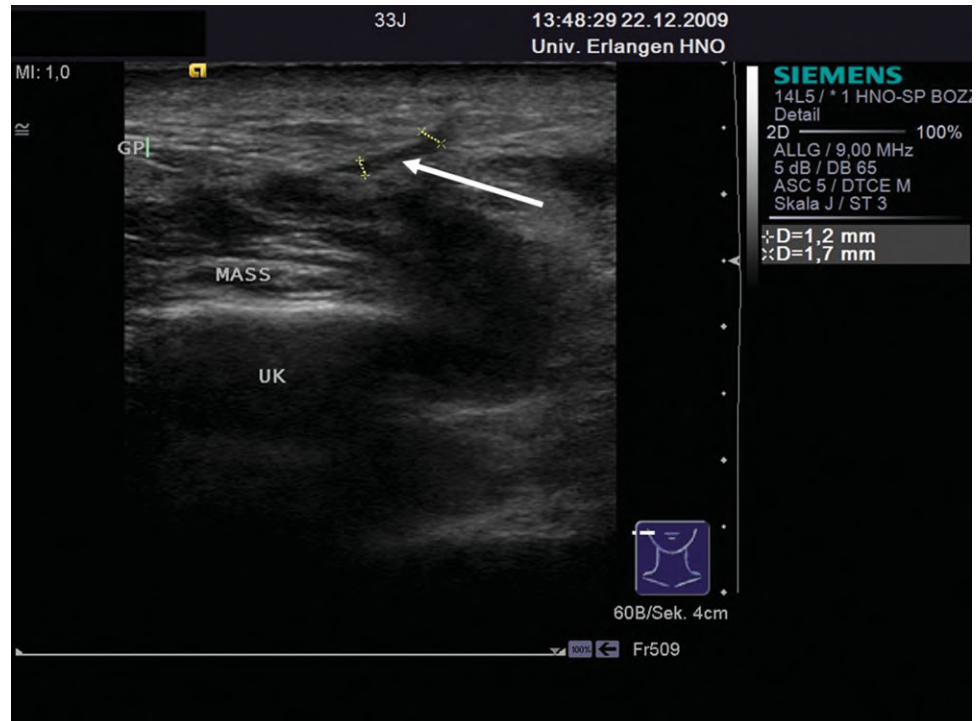


Fig. 1. High-resolution ultrasonography. There is a hypoechoic band (diameter, 1.7 mm) that extends from the ductal system to the skin level (white arrow), indicating a fistula between Stensen's duct and the skin. GP = parotid gland; MASS = masseter muscle; UK = mandible. [Color figure can be viewed in the online issue, which is available at [wileyonlinelibrary.com](http://wileyonlinelibrary.com).]

the duct was initially sutured with 7-0 nylon sutures around a 20-gauge silicone venous catheter that had been introduced (Fig. 3), and reconstruction of several buccal facial nerve rami with grafts from the great auricular nerve using Ethilon 9-0 or 10-0 sutures followed. The silicone stent was attached to the buccal mucosa using 5-0 polyglactin sutures. The subsequent course was unre-

markable, except for the development of a transient small sialocele that resolved spontaneously after 2 weeks. The stent was removed after 6 weeks, and the follow-up endoscopy showed a slight to moderate fibrous stricture in the area of the anastomosis (Fig. 4). Presently the patient is free of symptoms after 39 months and without signs of obstructive salivary gland swelling.

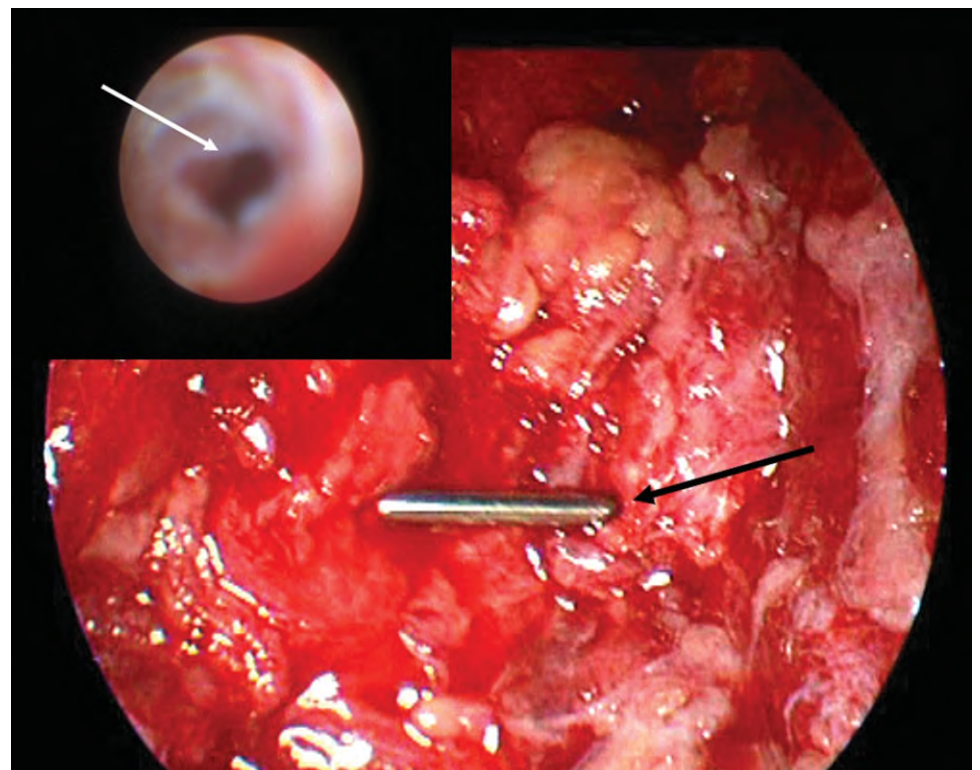


Fig. 2. Sialendoscopic view of the distal ductal stump, with the epithelial border (white arrow, inset). External view of the sialendoscope, which was advanced from the distal (black arrow) as a bridge into the proximal ductal stump. [Color figure can be viewed in the online issue, which is available at [wileyonlinelibrary.com](http://wileyonlinelibrary.com).]

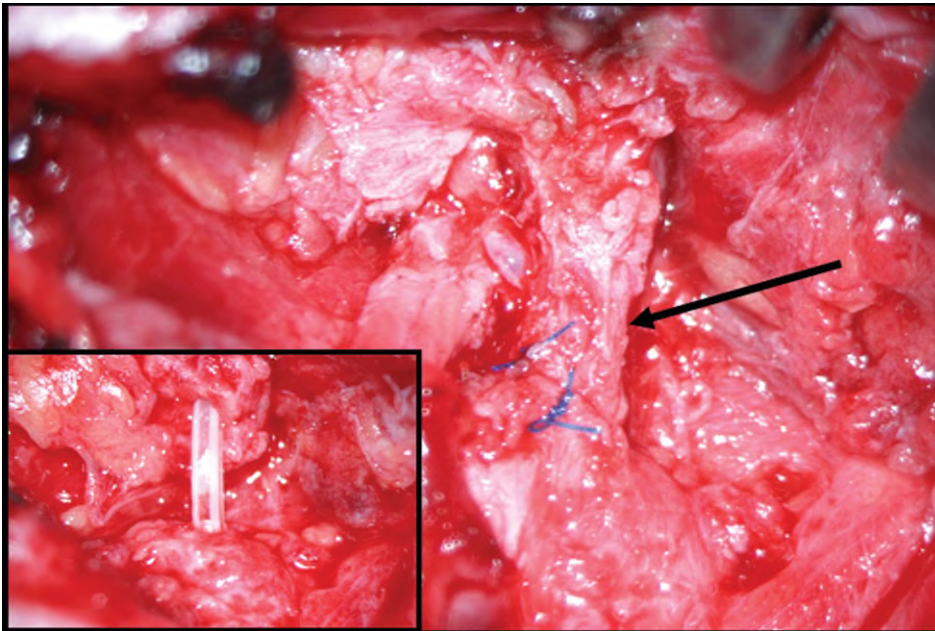


Fig. 3. View following anastomosis of the duct ends (the black arrow indicates the distal stump) around an introduced stent (silicone venous indwelling catheter, inset). [Color figure can be viewed in the online issue, which is available at [wileyonlinelibrary.com](http://wileyonlinelibrary.com).]

## DISCUSSION

In cases of injury to the parotid gland ductal system, early diagnosis and immediate surgical exploration are currently regarded as standard. When there is evidence of complete ductal transection, microsurgical reconstruction is always recommended, as there is otherwise a risk of loss of glandular function.<sup>1-5</sup> Rapid and secure diagnosis can make the decision to undertake early surgical revision easier. Direct imaging is not possible with diagnostic methods like contrast imaging and staining of the wound with methylene blue. Successful diagnostic and therapeutic use of sialendoscopy in duc-

tal lesions following facelift procedures allowed direct imaging and successful endoscopic treatment for lacerations of the ductal wall of Stensen's duct.<sup>8</sup> The present report describes successful use of a sialendoscope for traumatic complete transection of Stensen's duct. Sialendoscopy allowed atraumatic and rapid identification of the duct. Specific evaluation of the epithelium and potential branching of the duct in the two ductal stumps as well as rapid, precise, and atraumatic surgery was possible despite difficult tissue conditions. The case presented here shows that sialendoscopy allows a careful and targeted approach and can be a valuable aid in reconstructing Stensen's duct.

Use of the sialendoscope appears to be indicated in all partial ductal injuries as a sole procedure, and in cases of complete transection of the duct in combination with transcutaneous wound revision. Checking of the anastomosis can be carried out intraoperatively and in particular at follow-up examinations. If necessary, it is also possible to dilate postoperative strictures endoscopically, as this has already been done with considerable success in cases of obstructive salivary gland disease.<sup>9</sup>

Sialoceles and salivary fistulas may be the result of overlooked ductal injuries or late complications. Gland-preserving treatment here may consist of conservative measures, including treatment with botulinum toxin as well as various surgical procedures.<sup>3-5</sup> In our experience, the good results in therapy for treatment-resistant obstructive salivary gland diseases suggest that sialendoscopy can also be extremely useful in resecting fistulas or sialoceles in combination with transcutaneous access.<sup>11</sup>

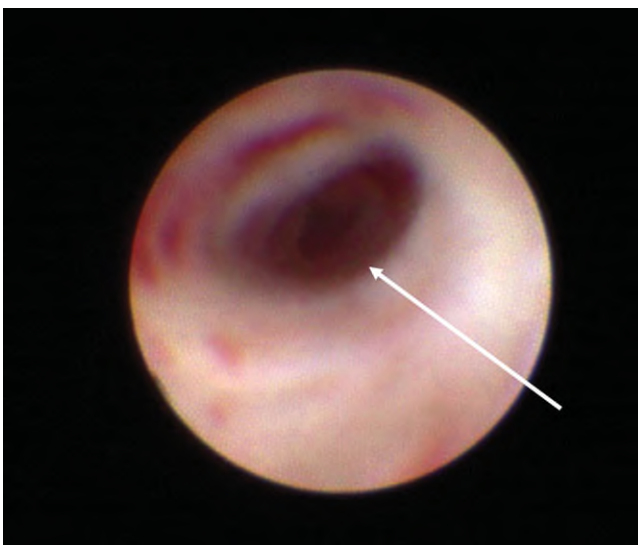


Fig. 4. Sialendoscopic examination 6 weeks postoperatively shows a mild to moderate stricture of Stensen's duct (white arrow), with no current effect on salivary flow. [Color figure can be viewed in the online issue, which is available at [wileyonlinelibrary.com](http://wileyonlinelibrary.com).]

## CONCLUSION

Sialendoscopy proved to be of value in precise localizing and assessing of the tissue damage and also in the atraumatic minimally invasive management after



complete traumatic transection of Stensen's duct. The endoscope also allowed postoperative follow up with assessment of the anastomotic region.

## BIBLIOGRAPHY

1. Stevenson JH. Parotid duct transection associated with facial trauma: experience with 10 cases. *Br J Plast Surg* 1983;36:81–82.
2. Lewkowicz AA, Hasson O, Nahlieli O. Traumatic injuries to the parotid gland and duct. *J Oral Maxillofac Surg* 2002;60:676–680.
3. Steinberg MJ, Herrera AF. Management of parotid duct injuries. *Oral Surg Oral Med Oral Pathol Oral Radiol Endod* 2005;99:136–141.
4. Van Sickels JE. Management of parotid gland and duct injuries. *Oral Maxillofac Surg Clin North Am* 2009;21:243–246.
5. Arnaud S, Batifol D, Goudot P, Yachouh J. Nonsurgical management of traumatic injuries of the parotid gland and duct using type a botulinum toxin. *Plast Reconstr Surg* 2006;117:2426–2430.
6. Hallock GG. Microsurgical repair of the parotid duct. *Microsurgery* 1992;13:243–246.
7. Heymans O, Nelissen X, Medot M, Fissette J. Microsurgical repair of Stensen's duct using an interposition vein graft. *J Reconstr Microsurg* 1999;15:105–107; discussion 107–108.
8. Nahlieli O, Abramson A, Shacham R, Puterman MB, Baruchin AM. Endoscopic treatment of salivary gland injuries due to facial rejuvenation procedures. *Laryngoscope* 2008;118:763–767.
9. Koch M, Iro H, Zenk J. Role of sialoscopy in the treatment of Stensen's duct strictures. *Ann Otol Rhinol Laryngol* 2008;117:271–278.
10. Koch M, Iro H, Zenk J. Sialendoscopy-based diagnosis and classification of parotid duct stenoses. *Laryngoscope* 2009;119:1696–1703.
11. Koch M, Bozzato A, Iro H, Zenk J. Combined endoscopic and transcutaneous approach for parotid gland sialolithiasis: indications, technique, and results. *Otolaryngol Head Neck Surg* 2010;142:98–103.