

Follow-up of parotid pleomorphic adenomas treated by extracapsular dissection

Heinrich Iro, MD, PhD*, Johannes Zenk, MD, PhD, Michael Koch, MD, PhD, Nils Klintworth, MD

Department of Otorhinolaryngology, Head and Neck Surgery, University of Erlangen-Nuremberg, Erlangen, Germany.

ABSTRACT: *Background.* This study was carried out to evaluate tumor recurrence following extracapsular dissection of pleomorphic adenomas of the parotid gland.

Methods. We conducted a retrospective evaluation and clinical follow-up of the patients who underwent extracapsular dissection of a pleomorphic adenoma as primary surgery in the otolaryngologic department of the Erlangen University Clinics during the period from 2000 to 2005.

Results. In all, 601 surgical interventions on benign parotid tumors were carried out from 2000 to 2005, 219 of which were primary operations for removal of a pleomorphic adenoma. In 76 patients (34.7%),

extracapsular dissection of a primary pleomorphic adenoma was carried out. Tumor recurrence has not been observed in any of these patients to date after an average monitoring period of 7.38 years (range, 5.05–10.52 years).

Conclusions. Extracapsular dissection is a conservative and safe surgical procedure for extirpation of pleomorphic adenomas that should be firmly established in the repertoire of parotid gland surgery. © 2012 Wiley Periodicals, Inc. *Head Neck* 35: 788–793, 2013

KEY WORDS: extracapsular dissection, pleomorphic adenoma, recurrence, parotid tumor, parotidectomy

INTRODUCTION

Although tumors of the parotid gland constitute only approximately 3% of all head and neck tumors, they do represent a significant clinical picture in ear, nose, and throat (ENT) practices.¹ Among benign parotid tumors, the pleomorphic adenoma is the histologic entity with the highest incidence at 60% to 70%, followed by cystadenolymphoma (Warthin's tumor) and other far less frequent benign histologic types.^{2,3}

The treatment of choice for pleomorphic adenoma is complete removal of the tumor.^{4,5} Besides the prospect of slow but constant tumor growth, there is also a risk of malignant degeneration into a carcinoma ex pleomorphic adenoma. The frequency of this malignant transformation is variously reported as between 3% and 15%.^{6,7} Furthermore, the supposedly benign pleomorphic adenoma can develop into a source of distant (eg, pulmonary) metastases.^{8,9}

The objective of surgical treatment is therefore complete removal of the tumor to prevent tumor recurrence.^{10–12} The required scope of surgical resection, however, has been the subject of controversial discussion for decades: proponents of the always standardized surgical techniques of superficial and total parotidectomy base their arguments mainly on a supposedly raised level of recurrence after less invasive resection procedures.^{4,12}

Those who favor extracapsular dissection and other partial parotidectomies claim a lower rate of postoperative complications for their approach, in particular a lower risk of facial nerve paresis, and point out the basically benign status of the pleomorphic adenoma.^{11,13,14} Our working group recently analyzed data from 377 patients in whom an extracapsular dissection had been performed. The analysis revealed a rate of temporary postoperative facial nerve paresis of 6.1% and 2.1% permanent paresis.¹³ Reference values from the literature for superficial and total parotidectomy range between 15% and 50% for temporary facial nerve paralysis and up to 10% for permanent paresis.^{15–17}

The fact that some literature sources report much higher recurrence rates for partial resection of pleomorphic adenomas than for superficial and total parotidectomy^{4,12,18,19} is due to an inexact differentiation of different surgical techniques, since enucleation, which was practiced during the first half of the last century, is in some cases assessed together with, or even equated with, the modern practice of extracapsular dissection. The high recurrence rates following tumor enucleations, 20% to 45%,^{20,21} result from intentional intraoperative opening of the tumor capsule followed by enucleation of the tumorous tissue, since tumor cells are disseminated and capsule structures remain in situ. This risk is not present in extracapsular dissection because the tumor is removed with a surrounding layer of healthy parenchyma and the capsule is not opened.^{11,13,22} Therefore, care has to be taken not to mix up the nomenclature of parotid surgery: the term "enucleation" must not be used anymore and should be reserved for the description of the obsolete technique described earlier. With respect to contemporary

*Corresponding author: H. Iro, Department of Otorhinolaryngology, Head and Neck Surgery, University of Erlangen-Nuremberg, Waldstrasse 1, D-91054 Erlangen, Germany. E-mail: heinrich.iro@uk-erlangen.de

parotid surgery, we suggest a 4-stage concept explained in the following text (see Materials and Methods).

Consequently, several studies have already demonstrated that the risk of recurrence of pleomorphic adenoma is not greater following extracapsular dissection compared with superficial or total parotidectomy, but is, rather, of a comparable magnitude at 2% to 5%.^{11,23,24}

The present article reports on 76 patients in whom a pleomorphic adenoma was removed by means of extracapsular dissection in our clinic as primary surgery between January 2000 and December 2005 as a contribution to the discussion of the risk of recurrence following extracapsular dissection.

MATERIALS AND METHODS

Patient collective

We carried out a retrospective analysis of all patients with a benign tumor of the parotid gland that was treated at our institution (Otorhinolaryngologic Clinic, Head and Neck Surgery, Erlangen University Clinics) between January 2000 and December 2005. The collective of patients was subdivided as well by the surgical techniques applied as by the pathohistologic results.

With regard to the aim of this study to analyze the recurrence rate of pleomorphic adenomas after extracapsular dissection, the further evaluation focused on those patients who had had a primary pleomorphic adenoma histologically proven that was removed by extracapsular dissection.

All patients gave their written informed consent to the surgical treatment and the follow-up examinations. The study was approved by the ethics review board of the Erlangen University Clinics.

Preoperative examination and selection for extracapsular dissection

All patients underwent a clinical examination including full ENT endoscopy. An ultrasound scan of the head and neck, with particular attention to the parotid glands, was carried out in all patients as primary imaging. Additional investigations such as CT and MRI are reserved for selected cases. A CT scan, for example, is carried out in case of suspected bone infiltration of the mandible, whereas MRI is the modality of choice to evaluate deep lobe involvement of a tumor. The cases reported in this study comprise only lesions that are located in the superficial part of the parotid gland so that they can be thoroughly examined sonographically. There was no suspicion of deep lobe involvement or bone infiltration preoperatively. Therefore, neither CT nor MRI scans were additionally performed in these cases because of the lack of indication.

Preoperative fine-needle aspiration cytology is not routinely performed at our institution and was not carried out in any patient of the study population.

The surgical technique to be performed in an individual case is defined in a 2-stage process. First, the preoperative clinical and sonographic findings suggest a potential approach. For example, patients were scheduled for extracapsular dissection in cases of a single and mobile tumor located superficially within the lateral lobe of the parotid gland. On the contrary, a total parotidectomy has

to be planned for a lesion lying in the deep lobe of the gland or in case of multilocality. However, the final decision about the surgical procedure and especially about preparation of the facial nerve's main trunk was made intraoperatively: a supposedly superficial mobile tumor can, for example, turn out to extend more deeply into the gland or to be located in close proximity to the facial nerve; preparation of the nerve and performance of a conventional parotidectomy is mandatory then. Thus, the surgeon had to be capable of switching between extracapsular dissection and the different forms of parotidectomies at any time of the operation.

Surgical technique and classification of parotidectomies

Because the descriptions of the different surgical techniques of parotidectomy vary greatly, we propose a 4-stage classification system based on the exposure of the main facial nerve trunk and the size of the resection as presented previously¹³: (1) an extracapsular dissection is defined as removal of a tumor from the parotid gland without exposure of the main trunk of the facial nerve; (2) if the main trunk is exposed, the procedure is designated as a partial parotidectomy because parts of the surface lobe of the gland are left in place; (3) removal of the entire surface lobe defines a superficial parotidectomy; and (4) consequently, extirpation of the entire gland is a total parotidectomy.

On no account should the term "enucleation" be used to refer to a partial resection, since this will cause confusion with the historical and obsolete technique referred to earlier (see Introduction).

The surgical preparations do not differ between extracapsular dissection and conventional parotidectomy, although the skin incision (Blair) and flap size may be adapted to size and location of the tumor. After dissection of the subcutaneous tissue, the sternocleidomastoid muscle, and the great auricular nerve, the capsule of the parotid gland is exposed (Figure 1). Before the capsule is opened the tumor is once again palpated. If the exact position of the tumor cannot be determined, an ultrasound scan can be performed intraoperatively. The parotid capsule is now incised and the dissection extended toward the tumor, although the tumor capsule itself is never opened. The dissection is now extended through the healthy glandular tissue around the tumor to gradually separate it, care being taken at all times to dissect away from the tumor. With this technique a small rim of healthy glandular tissue is left on the tumor (Figure 2), without damaging the facial nerve. After the tumor has been removed, the parotid capsule is sutured back together. A rubber drain is inserted and subcutaneous and skin sutures are applied. A pressure bandage is then applied for 3 to 5 days.

To identify and protect the branches of the facial nerve, neuromonitoring with bipolar nerve stimulation is performed mandatorily in all procedures. In the beginning, stimulation is carried out with a maximum current of 5 mA. As soon as a branch of the facial nerve is identified by positive stimulation, the stimulating current is reduced to 2 mA. After exposure of a nerve branch, the current is reduced further to ≤ 1 mA. Nerve branches are exposed only if they are situated close to the tumor and their definite identifications are considered desirable before further

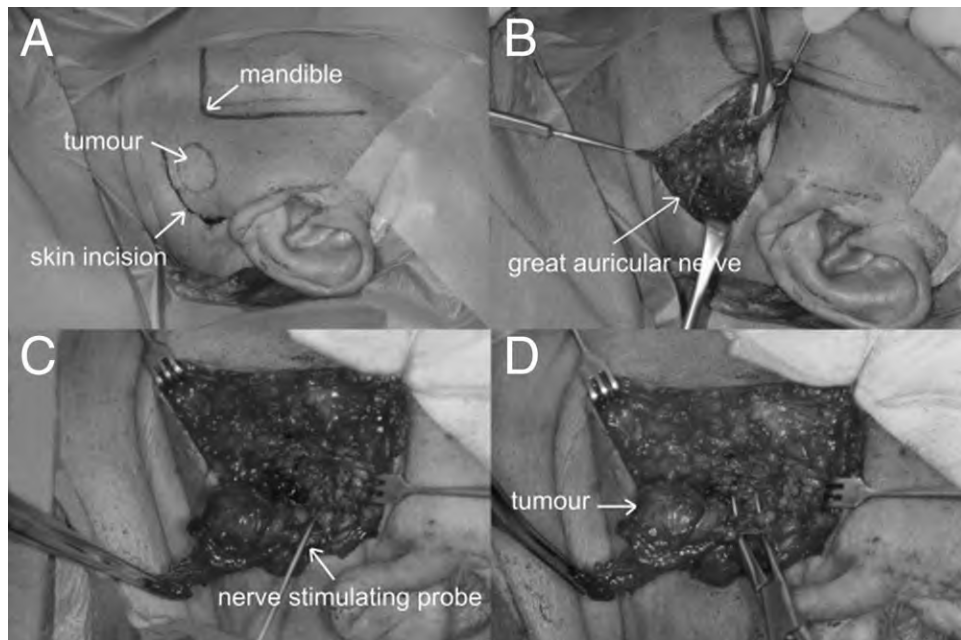


FIGURE 1. (A) marking of tumor and mandible before skin incision around the earlobe. (B) Preparation of skin flap and subcutaneous tissue with preservation of the great auricular nerve. (C) Use of facial nerve monitoring (stimulation probe) during dissection of glandular tissue. (D) Direction of preparation is always off the tumor when separating it from the gland.

dissection. The main trunk of the facial nerve, on the other hand, is not exposed during extracapsular dissection (see definition in the preceding text).

Postoperative management and follow-up examinations

All patients remained in the hospital for an average inpatient period of 3 to 6 days after the operation, for a regular check of their general condition as well as for the advance of wound healing. Thus, early postoperative complications such as bleeding, hematoma, seroma, salivary fistula, infection, and facial nerve paresis could be diagnosed at an early stage.

In the follow-up period, all patients received regular postoperative care in the form of at least annual clinical and imaging (normally sonographic) examinations.

During investigations of the given study, we contacted all patients whose last presentation in our clinic had occurred >1 year before the evaluation cutoff date and made a postoperative examination appointment, at which we then performed a clinical and ultrasonic examination of the head and neck region, inspecting, of course, in particular the operated salivary gland. For those patients who, for whatever individual reasons, were unable to present in our clinic (residence too far away, age and general condition, social factors), we arranged for a respective examination by a medical colleague with an ENT office.

The primary outcome assessed was the recurrence rate of pleomorphic adenoma and patient course after extracapsular dissection.

The cutoff date for the evaluation was December 31, 2010.

RESULTS

Patient population

Between January 1, 2000 and December 31, 2005, a total of 601 patients underwent surgery at the Otorhinolaryngologic Clinic, Head and Neck Surgery, Erlangen University Clinics for a benign tumor of the parotid gland. An extracapsular dissection was performed in 205 cases, and partial, superficial, and total parotidectomies in 52, 127, and 217 cases, respectively. After exclusion of the cases of revision surgery, 187 extracapsular dissections (34.1%), 43 partial parotidectomies (7.8%), 123 superficial parotidectomies (22.4%), and 195 total parotidectomies (35.6%) remained composing the patient population of 548 primary interventions (see Table 1).

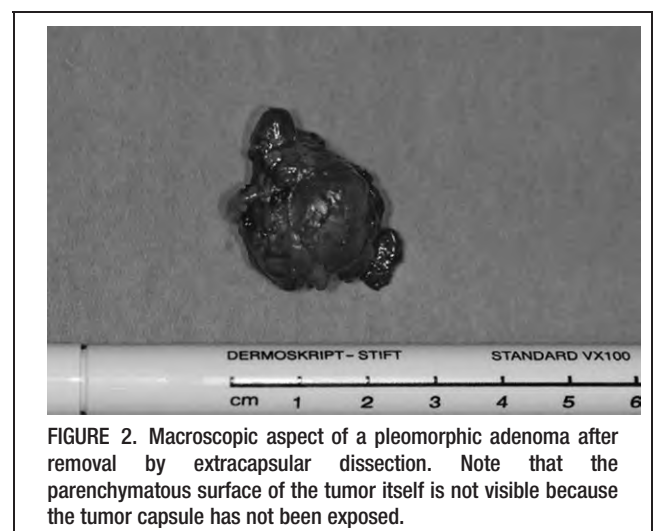


FIGURE 2. Macroscopic aspect of a pleomorphic adenoma after removal by extracapsular dissection. Note that the parenchymatous surface of the tumor itself is not visible because the tumor capsule has not been exposed.

TABLE 1. Proportions of different surgical techniques used in primary surgical procedures in the treatment of benign tumors of the parotid gland, carried out during the period from January 1, 2000 to December 31, 2005.

Surgical technique	No.	%
Extracapsular dissection	187	34.1
Partial parotidectomy	43	7.8
Superficial parotidectomy	123	22.4
Total parotidectomy	195	35.6
Total	548	100.0

The most frequent histologic type found in the postoperative pathohistologic analysis was the pleomorphic adenoma (219 = 40.0%), followed by Warthin's tumor (186 = 33.9%), other salivary benignomas (65 = 11.9%), and different nonneoplastic histologic entities such as cysts and lymph nodes (78 = 14.2%) (see Table 2).

Because we were interested in possible recurrences of pleomorphic adenomas that were primarily treated by extracapsular dissection, we focused on the 219 cases of primary pleomorphic adenomas. We performed an extracapsular dissection in 76 of these patients (34.7%). A partial parotidectomy was performed in 18 cases (8.2%), a superficial parotidectomy in 68 cases (31.1%), and a total parotidectomy in 57 cases (26.0%) (see Table 3).

The finding of pleomorphic adenoma was confirmed in all cases by the final histologic analysis; there were no signs of malignancy.

Of the 76 patients in our population, 47 were females and 29 were males. The average age when the operation was performed was 51.35 years (range, 16–86 years).

Postoperative complications

During the inpatient period the extracapsular dissection proved to be a surgical procedure with a low rate of postoperative complications: of the 76 primary extracapsular dissections of a pleomorphic adenoma, 65 patients (85.5%) did not show any complications. We saw 5 cases of formation of a seroma (6.6%) and 2 of a hematoma (2.6%), 2 salivary fistulae (2.2%), and 2 cases of secondary bleeding (2.2%).

Facial nerve function was postoperatively completely unimpaired (House–Brackmann Index [HBI] I) in 68 of these 76 cases (89.5%). Six patients (7.9%) showed a

TABLE 2. Distribution of pathohistologic entities of primary benign lesions of the parotid gland, surgically treated during the period from January 1, 2000 to December 31, 2005.

Histology	No.	%
Pleomorphic adenoma	219	40.0
Warthin's tumor	186	33.9
Other benignomas	65	11.9
Nonneoplastic histology	78	14.2
Total	548	100.0

TABLE 3. Proportions of different surgical techniques used in primary operations of pleomorphic adenomas of the parotid gland, carried out during the period from January 1, 2000 to December 31, 2005, and number of recurrences after primary treatment.

Surgical technique	No. (%)	
	All cases	Recurrences
Extracapsular dissection	76 (34.7)	0 (0.0)
Partial parotidectomy	18 (8.2)	1 (5.56)
Superficial parotidectomy	68 (31.1)	1 (1.47)
Total parotidectomy	57 (26.0)	1 (1.75)
Total	219 (100.0)	3 (1.37)

temporary paresis (HBI II and III) and 2 patients (2.6%) a permanent paresis (1 patient HBI II, 1 patient HBI III).

Thus, during this analysis the extracapsular dissection turned out to be a less invasive technique compared with conventional parotidectomies that cause fewer complications with regard to wound healing and facial nerve function in particular. We have already shown comparable results for a larger patient population—377 cases of extracapsular dissection—in a work recently published with special focus on direct postoperative complications.¹³

Follow-up examinations

The follow-up observation period averaged 7.38 years, with a minimum of 5.05 years and a maximum of 10.52 years (cutoff date: December 31, 2010).

Eighteen patients (23.7%) were unable to personally present at our department for follow-up due to different individual reasons (see preceding text). In these cases it was confirmed that the patients were seen by an experienced ENT colleague who performed both clinical and sonographic check-up. A written report on this examination was obtained in all cases.

No clinical or sonographic evidence of recurrence was found in the course of the follow-up period in any of the 76 patients in whom a pleomorphic adenoma had been removed by extracapsular dissection; that is, all of the described patients were free of recurrence as of the evaluation cutoff date (December 31, 2010). During the same period, 1 case of a recurrence was encountered in each group of the different parotidectomies, resulting in a recurrence rate of 5.56% for partial parotidectomy (1 of 18), 1.47% for superficial parotidectomy (1 of 68), and 1.75% for total parotidectomy (1 of 57), respectively.

DISCUSSION

The pleomorphic adenoma is the most frequent benign tumor of the parotid gland, optimum therapy of which is complete surgical removal. This is recommended not only to avoid tumor growth, which may make further resection more difficult, but also due to the fact that the pleomorphic adenoma may show both malignant degeneration (carcinoma ex pleomorphic adenoma) and the rare phenomenon of benign dissemination.^{6,8} Surgical revision procedures required for recurrent tumors also involve difficult preparation and higher perioperative risks due to

the previous surgical interventions and the resulting scarring.²⁵ Surgical intervention planning should also take into account the fact that the pleomorphic adenoma is a benign lesion and that, frequently, singular tumors with circumscribed dimensions are diagnosed that present in the clinical examination as mobile and near to the surface. For this reason, the procedure should be as minimally invasive as possible, with low risk levels for post-operative complications and limitations; an important objective to keep in mind here is preservation of the functional integrity of the facial nerve.

The main argument often used against partial resections of the parotid gland, and against extracapsular dissection in particular, is the postulated higher risk of recurrence of pleomorphic adenomas.^{4,12,18,21} We previously mentioned that the literature frequently confuses the modern technique of extracapsular dissection with the historical method of enucleation (see preceding text); importance should always be attached to the correct description and nomenclature. We introduce a 4-step concept distinguishing between extracapsular dissection and partial, superficial, and total parotidectomies as defined earlier (see Materials and Methods). Keeping this confusion in mind, the high 20% to 40% rates of recurrence reported for enucleation and other partial resections seldom represent substantive information. There are, on the other hand, studies that demonstrate that the risk of a recurring tumor does not vary among the different surgical techniques.^{11,14,23,26} For example, McGurk et al¹¹ determined a recurrence rate for pleomorphic adenomas of 2% after an average follow-up observation period of 12.5 years, following both extracapsular dissection ($n = 380$) and superficial parotidectomy ($n = 95$).

Arguments used in support of a potentially higher recurrence risk with circumscribed resections of a pleomorphic adenoma include above all peculiarities of the capsule structure of this histologic entity, also called a pseudocapsule, since histologic analysis of the tumor capsule reveals only a thin and partially discontinuous structure (ie, the capsule shows gaps).^{7,27} An investigation by Stennert et al⁷ in 2001 revealed, for example, a thin capsule ($<20 \mu\text{m}$) in 97 of 100 preparations and a partially missing capsule layer in 46%. Furthermore, after histopathologic preparation of pleomorphic adenomas, pseudopods (ie, finger-like extensions of the tumor tissue into the surrounding glandular parenchyma) are found as well as satellite nodes (ie, aggregates of tumor cells located outside of the capsule level that are separate from the main tumor).^{1,28} In an analysis of 218 pleomorphic adenomas, Zbären et al²⁷ confirmed pseudopods in 40% and satellite tumors in 13%.

Based on these histopathologic insights, the conclusion would be that, in preparation of a pleomorphic adenoma in close proximity to or directly on the capsule layer within the framework of an extracapsular dissection, there is a greater risk of leaving tumor cells behind with the glandular tissue that remains *in situ*^{7,27}; this would then appear to be less likely if the tumor were removed together with the entire gland, or at least its outer lobe.

There are, however, studies that contradict this conclusion. Donovan and Conley,²⁹ for example, have demonstrated that the tumor capsule is at least partially exposed

in 60% of cases of superficial or total parotidectomies as well. This can be explained above all by the proximity of the tumors to the facial nerve, making it necessary to do the preparation close to the capsule to avoid injury to the nerve. The postulated en bloc resection is thus, strictly speaking, not practiced in most cases anyway. The same study also showed that, in 40% of cases, only a very thin capsule layer was detectable at the edge of the preparation and that the capsule was even missing in part, or was interrupted, in 21%. Nonetheless, these histologic characteristics did not result in a raised level of recurrences in the patient collective.²⁹ Ghosh et al³⁰ demonstrated in 2003 that leaving a thin layer of connective tissue on the tumor was sufficient to minimize the risk of recurrence when removing a pleomorphic adenoma. They investigated 83 cases of pleomorphic adenoma with an average follow-up period of 12.5 years. In the cases in which the tumor extended to the edge of the resection, the investigators found a recurrence rate of 17.6% that, however, was reduced to 1.8% for the cases in which a thin capsule layer (in some cases $<1 \text{ mm}$) was detectable. The authors conclude that a separating layer consisting of 1 to 2 cell rows suffices for safe removal of the tumor.³⁰

It can be concluded from these investigations that it is important when extirpating a pleomorphic adenoma (and benign parotid tumors in general) to avoid injury to the capsule layer and, if possible (proximity of facial nerve; see earlier text), to leave a layer of glandular parenchyma on the tumor (see Figure 2). This technique does not raise the risk of tumor recurrence compared with superficial and total parotidectomies.

Furthermore, revision surgery may become necessary after any kind of parotidectomy because the risk of recurrence of a pleomorphic adenoma is 2% to 5%, independent of the surgical procedure applied (see earlier text). However, if the facial nerve's main trunk is dissected during the first operation, scarring will have taken place and dissecting the nerve again at the time of revision surgery will comprise a higher risk of damaging the nerve and, thus, of temporary and permanent paresis. In contrast, because the main trunk is not dissected during extracapsular dissection, conditions in the case of a required revision surgery are considerably better because no scarring complicates dissection of the facial nerve.

Although we suggest including extracapsular dissection into the range of surgical techniques for benign parotid tumors, the other forms of parotidectomies must not be superseded. Head and neck surgeons have to be capable of performing parotidectomies of any extent. Moreover, they have to be able to reliably identify situations in which they have to convert from an extracapsular dissection to a conventional parotidectomy and they have to be familiar with the whole spectrum of parotid surgery to do so.

CONCLUSION

The pleomorphic adenoma, the most frequent benign tumor of the parotid gland, requires adequate surgical therapy to prevent recurrence or possible malignant degeneration. Besides superficial and total parotidectomies, partial resections such as partial parotidectomy and,

in particular, extracapsular dissection, represent surgical methods by means of which suitable tumors can be removed conservatively but safely. Due to the lower level of invasiveness, perioperative complications, in particular temporary or permanent damage to the facial nerve, are much less frequent. The concern that these circumscribed resections would lead to an increased risk of recurrence have proven unfounded, both in the patients investigated here and in accord with the available literature. Nonetheless, we consider individual choice of surgical approach important: an extracapsular dissection should be considered for singular, near-surface, and mobile tumors. Intraoperatively, however, it should be possible to switch over at any time to a superficial/total parotidectomy with exposure of the main facial nerve trunk.

REFERENCES

1. Witt RL. The significance of the margin in parotid surgery for pleomorphic adenoma. *Laryngoscope* 2002;112:2141–2154.
2. Sungur N, Akan IM, Ulusoy MG, Ozdemir R, Kilinc H, Ortak T. Clinicopathological evaluation of parotid gland tumors: a retrospective study. *J Craniofac Surg* 2002;13:26–30.
3. Spiro RH. Salivary neoplasms: overview of a 35-year experience with 2,807 patients. *Head Neck Surg* 1986;8:177–184.
4. Stennert E, Jungehülsing M. Surgery of the parotid gland including reconstructive surgery of the facial nerve: standards and quality assurance [in German]. *Laryngorhinootologie* 2001;80 (suppl 1):156–197.
5. O'Brien CJ. Current management of benign parotid tumors—the role of limited superficial parotidectomy. *Head Neck* 2003;25:946–952.
6. Luers JC, Wittekindt C, Streppel M, Guntinas-Lichius O. Carcinoma ex pleomorphic adenoma of the parotid gland. Study and implications for diagnostics and therapy. *Acta Oncol* 2009;48:132–136.
7. Stennert E, Guntinas-Lichius O, Klusmann JP, Arnold G. Histopathology of pleomorphic adenoma in the parotid gland: a prospective unselected series of 100 cases. *Laryngoscope* 2001;111:2195–2200.
8. Manucha V, Ioffe OB. Metastasizing pleomorphic adenoma of the salivary gland. *Arch Pathol Lab Med* 2008;132:1445–1447.
9. Nouraei SA, Ismail Y, Ferguson MS, et al. Analysis of complications following surgical treatment of benign parotid disease. *ANZ J Surg* 2008;78:134–138.
10. Day TA, Deveikis J, Gillespie MB, et al. Salivary gland neoplasms. *Curr Treat Options Oncol* 2004;5:11–26.
11. McGurk M, Renehan A, Gleave EN, Hancock BD. Clinical significance of the tumour capsule in the treatment of parotid pleomorphic adenomas. *Br J Surg* 1996;83:1747–1749.
12. Guntinas-Lichius O, Kick C, Klusmann JP, Jungehülsing M, Stennert E. Pleomorphic adenoma of the parotid gland: a 13-year experience of consequent management by lateral or total parotidectomy. *Eur Arch Otorhinolaryngol* 2004;261:143–146.
13. Klintworth N, Zenk J, Koch M, Iro H. Postoperative complications after extracapsular dissection of benign parotid lesions with particular reference to facial nerve function. *Laryngoscope* 2010;120:484–490.
14. Rehberg E, Schroeder HG, Kleinsasser O. Surgery in benign parotid tumors: individually adapted or standardized radical interventions? [in German]. *Laryngorhinootologie* 1998;77:283–288.
15. Zernial O, Springer IN, Warnke P, Harle F, Risick C, Wiltfang J. Long-term recurrence rate of pleomorphic adenoma and postoperative facial nerve paresis (in parotid surgery). *J Craniomaxillofac Surg* 2007;35:189–192.
16. Witt RL. Facial nerve function after partial superficial parotidectomy: an 11-year review (1987–1997). *Otolaryngol Head Neck Surg* 1999;121:210–213.
17. Guntinas-Lichius O, Klusmann JP, Wittekindt C, Stennert E. Parotidectomy for benign parotid disease at a university teaching hospital: outcome of 963 operations. *Laryngoscope* 2006;116:534–540.
18. Witt RL, Rejto L. Pleomorphic adenoma: extracapsular dissection versus partial superficial parotidectomy with facial nerve dissection. *Del Med J* 2009;81:119–125.
19. Zbaren P, Tschumi I, Nuyens M, Stauffer E. Recurrent pleomorphic adenoma of the parotid gland. *Am J Surg* 2005;189:203–207.
20. McFarland J. Three hundred mixed tumors of the salivary glands of which 69 recurred. *Surg Gynecol Obstet* 1936;63:457–468.
21. Patey DH, Thackray AC. The treatment of parotid tumours in the light of a pathological study of parotidectomy material. *Br J Surg* 1958;45:477–487.
22. Gleave EN, Whittaker JS, Nicholson A. Salivary tumours—experience over thirty years. *Clin Otolaryngol Allied Sci* 1979;4:247–257.
23. Hancock BD. Clinically benign parotid tumours: local dissection as an alternative to superficial parotidectomy in selected cases. *Ann R Coll Surg Engl* 1999;81:299–301.
24. Witt RL. Minimally invasive surgery for parotid pleomorphic adenoma. *Ear Nose Throat J* 2005;84:308,310–311.
25. Redaelli de Zinis LO, Piccioni M, Antonelli AR, Nicolai P. Management and prognostic factors of recurrent pleomorphic adenoma of the parotid gland: personal experience and review of the literature. *Eur Arch Otorhinolaryngol* 2008;265:447–452.
26. Smith SL, Komisar A. Limited parotidectomy: the role of extracapsular dissection in parotid gland neoplasms. *Laryngoscope* 2007;117:1163–1167.
27. Zbaren P, Stauffer E. Pleomorphic adenoma of the parotid gland: histopathologic analysis of the capsular characteristics of 218 tumors. *Head Neck* 2007;29:751–757.
28. Orita Y, Hamaya K, Miki K, et al. Satellite tumors surrounding primary pleomorphic adenomas of the parotid gland. *Eur Arch Otorhinolaryngol* 2010;267:801–806.
29. Donovan DT, Conley JJ. Capsular significance in parotid tumor surgery: reality and myths of lateral lobectomy. *Laryngoscope* 1984;94:324–329.
30. Ghosh S, Panarese A, Bull PD, Lee JA. Marginally excised parotid pleomorphic salivary adenomas: risk factors for recurrence and management. A 12.5-year mean follow-up study of histologically marginal excisions. *Clin Otolaryngol Allied Sci* 2003;28:262–266.