

Management of Advanced Carcinoma of the Base of Tongue

ALEXANDER D. KARATZANIS, MD, PhD,¹ GEORGIOS PSYCHOGIOS, MD, PhD,²

KONSTANTINOS MANTSOPOULOS, MD, PhD,² JOHANNES ZENK, MD, PhD,^{2†}

GEORGE A. VELEGRAKIS, MD, PhD,^{1†} FRANK WALDFAHRER, MD, PhD,² AND HEINRICH IRO, MD, PhD^{2*†}

¹Department of Otorhinolaryngology, Head and Neck Surgery, University of Crete Medical School, Heraklion, Crete, Greece

²Department of Otorhinolaryngology, Head and Neck Surgery, University of Erlangen-Nuremberg Medical School, Erlangen, Germany

Background and Objective: Base-of-tongue carcinoma is a relatively rare disease with aggressive behavior and poor prognosis. Up to date no consensus exists regarding the ideal management strategy for each stage of the disease. This study aims to evaluate the experience of a single head and neck oncology center in the management of advanced stage base-of-tongue cancer.

Methods: A retrospective evaluation of cases primarily treated for stage III/IV_{A-B} base-of-tongue carcinoma, between 1980 and 2007, at a tertiary referral center.

Results: A total of 366 cases were studied. Five-year disease specific survival (DSS) was 42% and local control (LC) 80%. Regional and distal control estimates were 91.3 and 84%, respectively. Prognosis was significantly superior for cases receiving surgery plus adjuvant treatment compared to cases solely managed with non-surgical modalities. Positive surgical margins and regional disease significantly worsened prognosis. Satisfactory retention of pharyngeal function and no fatal complications were noted in surgical cases.

Conclusion: Although no consensus exists regarding ideal therapy for advanced base-of-tongue carcinoma, combined strategies with the use of surgery and adjuvant chemoradiotherapy (CRT) seem to offer the best possibility for a positive outcome.

INTRODUCTION

Oropharyngeal cancer represents a minority of head and neck carcinomas making up 10–15% of all cases in the Western world [1,2]. Base of tongue is considered the second most common subsite behind the tonsillar regions, representing between 20 and 35% of oropharyngeal lesions. The vast majority of cases are squamous cell carcinomas [3]. Although incidence of the disease is low, an increase as well as tendency of appearance in younger ages has been noted in recent years. This has been mainly attributed to human papilloma virus (HPV) infection [4].

Cancer of the base of tongue is generally considered an aggressive disease with poor prognosis [5–7]. Ideal management for each stage of the disease is yet to be defined. Treatment has recently been in significant transit due to advances in diagnostic and therapeutic approaches [8]. Surgery, radiotherapy (RT), and chemotherapy either alone in early stage disease or combined in more advanced stages, constitute the mainstay of treatment [9,10]. Surgery can range, depending on local disease stage, from simple transoral excision to mandibulotomy combined with oropharyngectomy and microvascular reconstruction. Nonsurgical treatment is also determined by the stage of disease and functional status of the patient. It ranges from primary RT to combined chemoradiotherapy (CRT) with different options in timing and combination of modalities [11,12].

Non-surgical treatment has been considered the standard of care in many centers for every stage of base-of-tongue cancer [2,5,11,12]. Organ-preservation strategies, using RT or CRT, have focused on improved disease control as well as sparing of normal tissues. These modalities seem to offer similar oncologic results with superior quality of life when compared to radical surgery and adjuvant therapy [12–15]. However, both RT and chemotherapy are still associated with severe adverse effects. In addition, the concept of organ preservation does not always coincide with function preservation.

Surgery for base-of-tongue cancer has progressed significantly in recent decades. Laser CO₂, robotic surgery, and microvascular reconstruction are among the newest options available, offering effective treatment and perhaps decreased morbidity in carefully selected cases of oropharyngeal cancer [2,5,11,16]. However, the results of surgery for advanced stages may still be jeopardized because of issues related to swallowing and speech alteration, as well as other functional disabilities [17]. Additional problems may be faced when adjuvant treatment is added to the management plan [5].

As long as the ideal management strategy for oropharyngeal cancer in general and base-of-tongue lesions in particular, remains unclear, new data presentation and analysis may be considered valuable. This study aims to retrospectively evaluate the experience of a single head and neck oncology center in the management of advanced-stage base of tongue cancer.

METHODS

A retrospective study was conducted at an academic tertiary referral center (Department of Otorhinolaryngology, Head and Neck

Alexander D. Karatzanis and Georgios Psychogios contributed equally to this manuscript.

†Professor and Chairman.

*Correspondence to: Heinrich Iro, MD, PhD, Department of Otorhinolaryngology, Head and Neck Surgery Friedrich Alexander University of Erlangen-Nuremberg, Waldstr. 1, 91054, Erlangen, Germany. Fax: 0049-9131-8533833. E-mail: heinrich.iro@uk-erlangen.de

Surgery, University of Erlangen-Nuremberg Medical School, Erlangen, Germany). Relevant approval from the institutional review board of the hospital was obtained. The files of all patients primarily treated for stage III/IV_{A-B} base-of-tongue carcinoma between 1980 and 2007 were evaluated. Patients with recurrent or systemic disease at the time of diagnosis, and histology other than squamous cell carcinoma, as well as patients with second primary tumors at the time of diagnosis, were excluded from the study.

All pathology reports were reviewed and staging was conducted in accord with the 2010 American Joint Committee on Cancer (AJCC) and Union Internationale Centre Contre Cancer (UICC) classification [12]. According to TNM staging, stage III in the oropharynx includes T3N0-1M0 and T1-2N1M0 cases. Stage IV_A includes T<4N2M0 and T4aN<3M0 cases. Finally, stage IV_B includes T4bN(any)M0 and T(any)N3M0 cases.

All patients were assessed for disease specific survival (DSS) and overall survival (OS) as well as local control (LC) rates, with respect to T classification, N classification, type of primary treatment, status of surgical margins, and adjuvant therapy. Surgical margins were evaluated from primary tumor pathology reports and considered as positive when characterized by the presence of invasive carcinoma at the edge of resection on permanent section pathology.

Five year DSS was defined using the time from the date of diagnosis to death from the tumor or complications of treatment. Time to LC or regional control (RC) was calculated from the date of initial diagnosis to the date of most recent clinical review when local or regional recurrence was confirmed. Local recurrence was defined as invasive carcinoma developing after completion of initial treatment at the anatomic site of the primary tumor. Regional and distal recurrences were defined as the presence of the same tumor in the regional lymph nodes or distant sites respectively, after the completion of initial treatment. Calculations of five-year overall and disease-specific survival, LC and RC were made with Kaplan–Meier estimates and compared by the means of the log-rank test. A *P*-value of less than 0.05 was considered significant. Statistical analysis was performed using SPSS Version 19 (SPSS Inc., Chicago IL).

Cases were additionally evaluated for incidence of major complications and retention of pharyngeal function following surgery. No data regarding complications of non-surgical modalities were available for assessment. Major surgical complications were defined as those which necessitated prolonged hospitalization, blood transfusion, additional surgery, or admission to the intensive care unit. Pharyngeal function was indirectly evaluated by assessing the incidence of permanent tracheotomies and gastrostomies.

RESULTS

A total of 366 cases that satisfied the inclusion criteria were analyzed. Among these, 308 were men and 58 women, with 5.3:1 men to women ratio. Mean age was 55 years, ranging from 24 to 84 years. Minimum follow-up was 24 months. A large amount of patients (279 cases, 76.2%) had locally advanced T3 or T4 tumors at the time of diagnosis. However, only five T4b cases were found. A detailed description of cases in accord with T and N classification is presented in Table I.

Five-year DSS was 42% overall in this series while LC was 80%. Regional and distal control estimates were 91.3 and 84%, respectively. Two major groups could be defined in accord with management. One received RT with or without chemotherapy (CRT group) as primary treatment (217 cases) and the other underwent surgery (135 cases). For another 14 cases accurate determination of primary treatment was not possible based on data from their files and these were not assessed further. Prognosis was found to differ significantly between the two major groups. DSS rate was 63.2% for the primary

TABLE I. Distribution of the 366 Cases That Were Assessed in this Study in Accord With T Classification, N Classification, and Stage of Disease

	Number of cases	Percentage (%)
T1	19	5.2
T2	68	18.5
T3	114	31.1
T4 (not otherwise specified)	30	8.2
T4a	130	35.5
T4b	5	1.3
N0	71	19.4
N1	46	12.5
N2	200	54.6
N3	49	13.4
Stage III	60	16.4
Stage IV (not otherwise specified)	28	7.6
Stage IV _A	225	61.4
Stage IV _B	53	14.4

surgery group and 29.2% for the CRT group (*P* < 0.001). OS rates were 46.5 and 18.4% (*P* < 0.001), respectively. On the other hand, comparable results were found with regard to LC as the first group achieved 85.8% and the second 76.4% rates (*P* = 0.09). Kaplan–Meier analysis of DSS in accord with primary therapy is presented in Figure 1. When locally advanced T3 and T4 cases were separately evaluated, surgically treated patients again showed better oncologic results. DSS rates were 56.5% for the surgical group and 28.2% for the CRT group (*P* < 0.001), as presented in Figure 2. Moreover, OS rates were 40.2 and 16.8%, respectively (*P* < 0.001). A trend toward better LC rate was also found for the first group, although significance was not reached (82.8% vs. 76.54%, *P* = 0.58).

Decision to perform surgery as primary treatment was mainly based on the local extent of disease, and general health status as well

disease specific survival according to primary surgical therapy

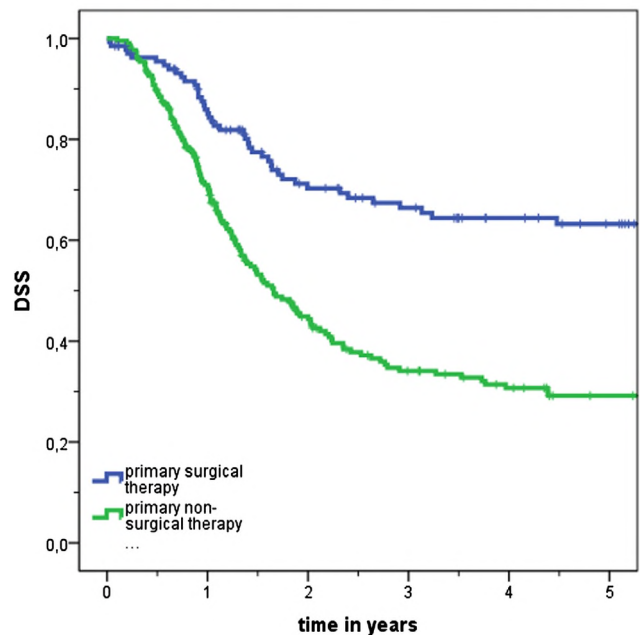


Fig. 1. Kaplan–Meier analysis of disease specific survival (DSS) with respect to primary treatment. [Color figure can be seen in the online version of this article, available at <http://wileyonlinelibrary.com/journal/jso>]

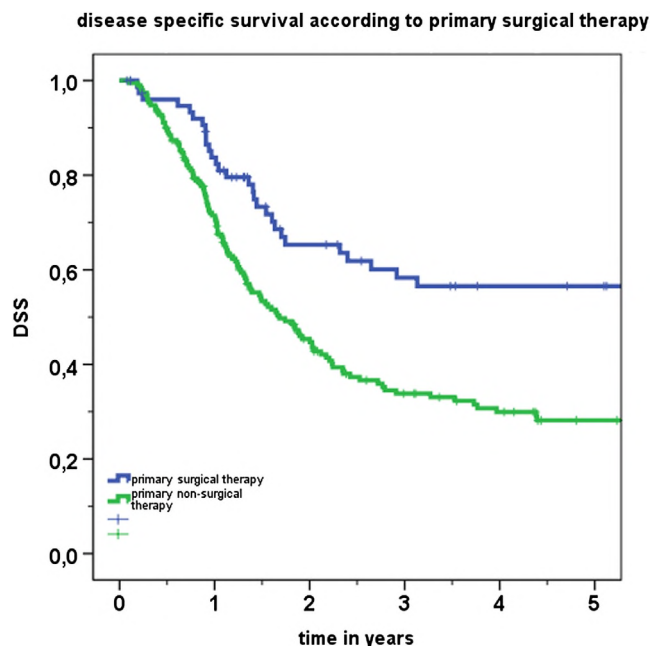


Fig. 2. Kaplan–Meier analysis of disease specific survival (DSS) specifically for locally advanced, T3 and T4 cases, in accord with primary treatment. [Color figure can be seen in the online version of this article, available at <http://wileyonlinelibrary.com/journal/jso>]

as personal preference of each patient. Type and extent of surgery depended mainly on local tumor size and clinical status of the neck. Surgery ranged from intraoral CO₂ laser or diathermy tumor excision for smaller lesions to pharyngectomy with mandibulotomy and microvascular reconstruction—typically with a radial forearm free flap—for locally advanced disease. A detailed presentation of surgical techniques may be found in Table II. Cases undergoing primary surgery typically received adjuvant therapy consisting of RT with or without chemotherapy. Only 20 cases that were deemed physically unable to receive further treatment or died before such treatment could be offered were spared from adjuvant therapy.

When only cases that underwent combined treatment, i.e., surgery and postoperative RT with or without chemotherapy (115 patients), were specifically compared to cases receiving primary chemoradiation (144 patients), results were again in favor of the former. DSS rate was 68.9% for the first group and 27.6% for the second group ($P < 0.001$). OS rates were 51.7 and 18.6% ($P < 0.001$), respectively. With regard to LC, the first group achieved 87.5% and the second 75.2% ($P = 0.04$). Kaplan–Meier analysis of DSS for these specific groups is presented in Figure 3.

TABLE II. Presentation of Operative Techniques Used for Primary Surgical Treatment in This Series

Surgical technique	Number of patients	Percentage (%)
Transoral laser surgery	65	48.2
Transoral conventional resection	31	22.9
Lateral pharyngotomy	17	12.6
Mandibular swing	5	3.7
Partial pharyngectomy with supraglottic laryngectomy	12	8.9
Laryngo-pharyngectomy	5	3.7
Total	135	100

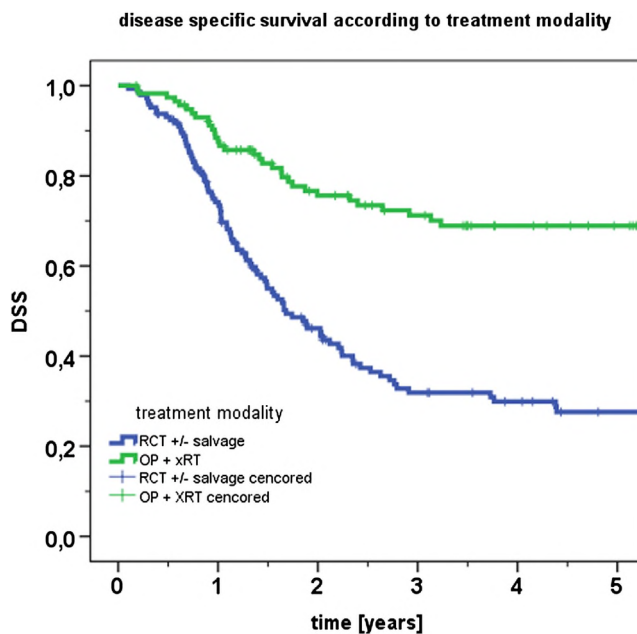


Fig. 3. Kaplan–Meier analysis of DSS specifically for cases treated with surgery and adjuvant therapy (OP + xRT), compared to cases managed with primary chemoradiation (RCT ± salvage). [Color figure can be seen in the online version of this article, available at <http://wileyonlinelibrary.com/journal/jso>]

According to pathology reports, negative surgical margins (R0 status) had been achieved in 106 out of 135 (78.5%) surgically treated cases in this series. Conversely, 29 (21.5%) cases had positive surgical margins (R+ status) at the end of surgical treatment. All of these cases later received adjuvant treatment. Survival rates were found to be significantly superior for cases with R0 status compared to R+ status cases (DSS 71.2% vs. 28.7%, $P < 0.001$, and OS 53.9% vs. 17.8%, $P < 0.001$, respectively). However, R+ status group was comparatively very small thus limiting the statistical power of the log-rank test. Kaplan–Meier analysis of DSS according to R status is presented in Figure 4.

Patients that were not treated with primary surgery received RT with or without chemotherapy. Selection of the exact treatment scheme was individualized according mainly to the extent of disease and the general health status of each patient. Non-surgical treatment has been affected by various changes in protocols as well as technical developments that have been noted over the years in this center. For recent cases, however, non-surgical treatment has typically comprised of radiation therapy with a cumulative dose of 66–72 Gy using conventional fractionation, plus concomitant cisplatin-based chemotherapy.

Clinical evidence of regional disease was found in 295 (80.6%) out of 366 cases at the time of initial management. The presence of regional metastases affected prognosis. DSS rates were 50.3% for cN0 and 40% for cN+ cases ($P = 0.042$). OS, however, was comparable between the two groups (34.9% vs. 27.9%, respectively, $P = 0.243$). In all cN0 cases undergoing surgery, bilateral selective dissection of levels II, III, and IV was performed. Almost half of these cases (7/15) showed evidence of occult metastasis on histopathology. In cases with known or suspected neck metastases, a modified radical neck dissection was typically performed. The same strategy was followed, regarding the neck, for cases in the CRT group that showed clinical evidence of regional disease at the end of primary treatment.

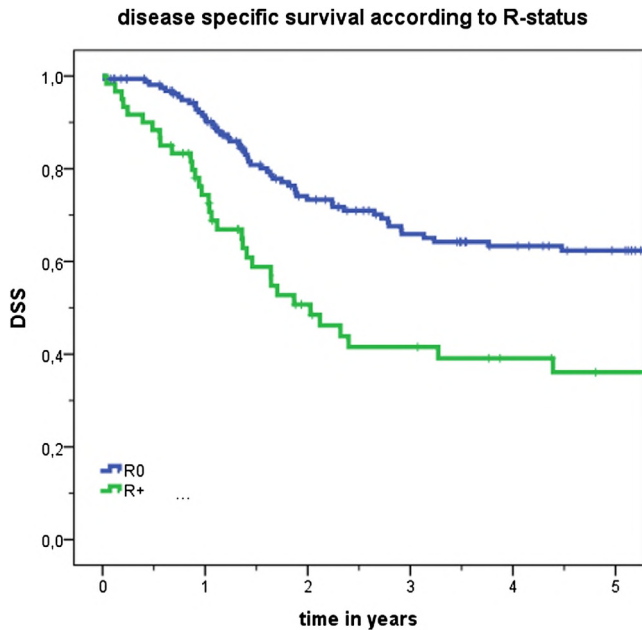


Fig. 4. Kaplan–Meier analysis of disease specific survival (DSS) for surgically treated cases, with respect to R status. R0: Cases with negative surgical margins on permanent histology. R+: Cases with positive surgical margins. [Color figure can be seen in the online version of this article, available at <http://wileyonlinelibrary.com/journal/jso>]

Overall incidence of complications was 22.9% for cases undergoing primary surgery (31/135 cases). Complications included bleeding, fistula formation, wound healing problems, and aspiration. None of these was fatal. A detailed presentation may be found in Table III. Functional results, as evidenced by the rate of permanent tracheotomies and gastrostomies, were satisfactory, as only 15.5% (21/135) of cases had a permanent tracheotomy while 6 (4.4%) patients remained permanently dependant on gastrostomy tubes.

DISCUSSION

Base-of-tongue cancer is a disease with increasing incidence that poses serious diagnostic and therapeutic challenges for treating physicians [2,11]. Diagnostic challenges are related to the fact that base of tongue is an anatomic area difficult to explore and symptoms are produced late in the course of a neoplastic disease. In addition,

the rich lymphatic drainage of this area allows for early spread to regional lymph nodes. For these reasons, diagnosis of base of tongue cancer is typically made in advanced stage [3,7]. This leads to the main therapeutic challenge regarding achievement of curability with retention of pharyngeal and laryngeal function. Adding further to the problem, is the fact that no consensus exists regarding ideal management for each stage of the disease [3,5,7,11]. Surgery, RT, and chemotherapy have been utilized alone or in various combinations producing results that have not been adequately tested and compared through prospective randomized trials [2,3]. Up to date, selection of treatment largely depends on tumor and patient factors, local expertise, and availability of support and rehabilitative services [2]. As long as randomized data are lacking, non-randomized data, such as those presented here, may offer a basis for treatment decision-making.

A shift has been noted in recent years toward organ-preserving treatment strategies for base-of-tongue cancer [12,18]. Chemotherapy in combination with irradiation has been supported as the most useful management option for every stage of the disease [3,12,13,18]. Proponents of CRT argue that this strategy offers comparable or even superior oncologic results compared to surgery and adjuvant therapy. At the same time significantly less morbidity and superior function may be anticipated [13,18,19]. However, both RT and chemotherapy have been associated with severe adverse effects. Such effects locally include dysphagia, xerostomia, trismus, difficulties in swallowing, mandibular radionecrosis, fibrosis, and pharyngeal strictures. Systemic adverse effects may also appear and these include bone marrow toxicity, infections, neuropathy, renal failure, nutritional deficiencies, and fatigue [13]. In addition, previous studies have shown that CRT may eventually lead to impaired function as well [2,16]. Therefore, organ-preservation may not necessarily lead to function-preservation.

When surgery is selected as the initial treatment for base of tongue cancer, a wide range of techniques may be adopted depending on the local extent of the lesion and preference of the surgeon. Historically, the preferred surgical approaches have included translabial composite resection or a mandibulotomy, especially in locally advanced, T3 or T4 cases. Despite the wide surgical access afforded by these approaches, disadvantages include subsequent alterations of speech and deglutition, malocclusion, wound healing problems, cosmetic deformity, and temporomandibular joint pain. As a result, mandible-sparing procedures are now advocated by most centers in the management of BOT tumors. Among these procedures, the transhyoid approach is perhaps the most common surgical alternative for limited, accessible tumors [2]. Other similar approaches include transhyoid, suprahyoid, and transpharyngeal for limited lesions of the tongue base, as well as for more extensive lesions involving the tongue base, tonsillar fossa, or both, with acceptable oncologic and functional results [2,20–22].

TABLE III. Detailed Presentation of Complications for Cases Undergoing Primary Surgical Management, in Addition to Functional Results as These May be Indirectly Assessed by the Number of Permanent Tracheostomies and Gastrostomies

Type of complication	Pharyngeal function			Total
	No evidence of functional dysfunction	Permanent tracheostomy	Permanent gastrostomy	
None	94	10	0	104
Bleeding	6	2	0	8
Necrosis of the flap	0	1	0	1
Fistula	2	3	0	5
Nerve palsy	1	0	0	1
Wound-healing problems	3	1	0	4
Aspiration	0	2	3	5
Aspiration-pneumonia	0	0	3	3
Others	2	2	0	4
Total	108 (80.1%)	21 (15.5%)	6 (4.4%)	135

In the present series surgery was selected as primary treatment in 135/366 cases. A wide range of surgical techniques, ranging from intraoral CO₂ laser or diathermy tumor excision to pharyngectomy with mandibulotomy and microvascular reconstruction, were adopted, mainly depending on the local extent of the disease. These cases combined, form a rather diverse group and make any conclusions regarding the effectiveness of surgery difficult. Despite that, an absence of fatal complications in addition to acceptable functional outcome, as evidenced by the low rates of permanent tracheostomies and gastrostomies, were generally noted. It should be emphasized once more that most of cases in the group of primary surgery also received adjuvant therapy. Therefore this should be regarded as a combined rather than surgical treatment group. On the other hand, patients that were not treated with primary surgery received RT with or without chemotherapy as the main form of therapy. Interestingly, prognosis was found to be significantly worse for these cases compared to those receiving primary surgery (Fig. 1). One could argue that such results are strongly related to selection bias as most of the low T category cases would be expected to be managed with surgery. At the same time, all locally advanced tumors that would be deemed inoperable would fall on the non-surgical group. However, only five T4b were found in this series and therefore were unlikely to affect outcomes. Moreover, oncologic results remained superior for the group of primary surgery even when locally advanced T3 and T4 cases were separately evaluated. Comparison between these groups should by no means be considered as comparison between surgery and conservative treatment. However, this study presents evidence that primary surgery might have a clear role even in advanced base of tongue lesions. Such a finding may come in contradiction with recent literature which increasingly depicts oropharyngeal cancer as a non-surgical disease [18]. Although randomized, prospective trials are necessary for safe conclusions, the notion that base of tongue cancer should, by definition, be managed conservatively is hereby challenged.

For surgically managed cases, status of surgical margins was found to significantly affect prognosis. Patients with R0 status showed better survival rates compared to R+ cases (Fig. 2). The significance, therefore, of achieving tumor-free surgical margins should be emphasized. It has been previously established that patients with head and neck cancer exhibiting positive resection margins show decreased survival [23–26]. This study confirms the importance of surgical margins in primary surgical treatment of base of tongue lesions. An increased incidence of positive margins, mainly related to advanced local stage, was noted, however, in this series. The prognostic value of positive neck nodes at presentation was also confirmed, as patients with positive lymph nodes showed significantly worse survival compared to cases with negative neck at diagnosis. Furthermore, an increased rate of occult metastasis, again as expected, was noted for cN0 cases undergoing neck dissection [5,24].

The data presented here meet many of the limitations inherent in nonrandomized studies. These limitations include selection bias and use of non-standard treatment with modifications made in RT and chemotherapy protocols over the years. Moreover, the lack of data regarding complications and functional results for patients managed with non-surgical treatment modalities makes comparison between treatment strategies more difficult. The diversity of surgical techniques which comprise the group of primary surgery creates additional skepticism. On the other hand, this is the largest retrospective, single-institution, clinical case series of advanced stage base of tongue carcinomas currently in the literature. Since prospective randomized studies are generally lacking, data such as that presented here may still prove to be valuable during treatment decision-making. In addition, these results emphasize the need for properly designed studies, before any safe conclusions regarding the ideal management of base of tongue cancer can be reached.

As this was a retrospective study, no focus was given on the prognostic effect of HPV infection. It becomes clear in recent literature, however, that an etiologic association exists between oropharyngeal carcinoma and oncogenic HPV [4]. Evidence also suggests that the biology and behavior of HPV-associated carcinomas differs from non HPV-associated cases and a more favorable prognosis may be anticipated for the former [4,27,28,29]. The prognostic significance and therapeutic implications of HPV infection in oropharyngeal lesions certainly warrant further attention in the future.

In conclusion, advanced carcinoma of the base of tongue comprises a relatively rare but difficult to manage disease entity. Despite recent advances in treatment options, prognosis remains generally poor. Although no consensus exists regarding ideal therapy for advanced stages, combined strategies with the use of surgery and adjuvant CRT seem to offer the best possibility for a positive outcome.

ACKNOWLEDGMENTS

The authors would like to thank Philipp Grundtner for his valuable assistance during the statistical analysis of the data.

REFERENCES

1. Kraus DH, Joe JK: Neoplasms of the oral cavity and oropharynx. In: Snow James B, Ballenger John Jacob, editors. Ballenger's otorhinolaryngology head and neck surgery, 16th edition. Hamilton, Ontario, Canada: BC Decker Inc; 2003.
2. Rodrigo JP, Diaz-Molina JP, Moreno C, et al.: Oncologic and functional results after transhyoid surgical approach for cancer of the base of tongue. *Head Neck* 2011;33:1079–1084.
3. Jones A, Rafferty M, Fenton J, et al.: Treatment of squamous cell carcinoma of the tongue base: Irradiation, surgery or palliation? *Ann Otol Rhinol Laryngol* 2007;116:92–99.
4. Attner P, Du J, Nasman A, et al.: Human papillomavirus and survival in patients with base of tongue cancer. *Int J Cancer* 2011;128:2892–2897.
5. Karatzanis AD, Psychogios G, Waldfahrer F, et al.: Surgical management of T1 oropharyngeal carcinoma. *Head Neck* 2011. DOI: 10.1002/hed.21916
6. Psychogios G, Mantsopoulos K, Kuenzel J, et al.: Primary surgical treatment of T2 oropharyngeal carcinoma. *J Surg Oncol* 2011. DOI: 10.1002/jso.23026
7. Pitcher M, Martin C: Delay in referral of oropharyngeal squamous cell carcinoma to secondary care correlates with a more advanced stage at presentation, and is associated with poorer survival. *Br J Cancer* 2006;94:955–958.
8. Cohan DM, Popat S, Kaplan SE, et al.: Oropharyngeal cancer: Current understanding and management. *Curr Opin Otolaryngol Head Neck Surg* 2009;17:88–94.
9. Walvekar RR, Li RJ, Gooding WE, et al.: Role of surgery in limited (T1-2, N0-1) cancers of the oropharynx. *Laryngoscope* 2008;118:2129–2134.
10. National Comprehensive Cancer Network. 2007; NCCN clinical practice guidelines in oncology head and neck cancers. Available at: <http://www.nccn.org>.
11. Henstrom D, Moore EJ, Olsen KD, et al.: Transoral resection for squamous cell carcinoma of the base of the tongue. *Arch Otolaryngol Head Neck Surg* 2009;135:1231–1238.
12. Pederson AW, Haraf DJ, Witt ME, et al.: Chemoradiotherapy for locoregionally advanced squamous cell carcinoma of the base of tongue. *Head Neck* 2010;32:1519–1527.
13. Mowry SE, Ho A, Lotempio MM, et al.: Quality of life in advanced oropharyngeal carcinoma after chemoradiation versus surgery and radiation. *Laryngoscope* 2006;116:1589–1593.
14. Allal AS, Nicourar K, Mach N, et al.: Quality of life in patients with oropharynx carcinomas: Assessment after accelerated radiotherapy with or without chemotherapy versus radical surgery and postoperative radiotherapy. *Head Neck* 2003;25:833–839.

15. Kreeft AM, Molen LV, Hilgers FJ, et al.: Speech and swallowing after surgical treatment of advanced oral and oropharyngeal carcinoma: A systematic review of the literature. *Eur Arch Otorhinolaryngol* 2009;266:1687–1698.
16. Iro H, Mantsopoulos K, Zenk J, et al.: Results of transoral laser resection in T1-2 oropharyngeal, hypopharyngeal and laryngeal carcinomas. *Laryngorhinootologie* 2011;90:481–485.
17. American Joint Committee on Cancer (AJCC). Manual for staging of cancer, 7th edition. New York, NY: Springer-Verlag; 2010; 30–38.
18. Haigentz M Jr, Silver CE, Corry J, et al.: Current trends in initial management of oropharyngeal cancer: The declining use of open surgery. *Eur Arch Otorhinolaryngol* 2009;266:1845–1855.
19. Mendenhall WM, Morris CG, Amdur RJ, et al.: Definitive radiotherapy for squamous cell carcinoma of the base of tongue. *Am J Clin Oncol* 2006;29:32–39.
20. Weber PC, Johnson JT, Myers EN: The suprahyoid approach for squamous cell carcinoma of the base of the tongue. *Laryngoscope* 1992;102:637–640.
21. Agrawal A, Wenig BL: Resection of cancer of the base of tongue and tonsil via the transhyoid approach. *Laryngoscope* 2000;110:1802–1806.
22. Azizzadeh B, Enayati P, Chhetri D, et al.: Long-term survival outcome in transhyoid resection of base of tongue squamous cell carcinoma. *Arch Otolaryngol Head Neck Surg* 2002;128:1067–1070.
23. Jackel M, Ambrosch P, Martin A, et al.: Impact for re-resection for inadequate margins on the prognosis of upper aerodigestive tract cancer treated by laser microsurgery. *Laryngoscope* 2007; 117:350–356.
24. Karatzanis AD, Waldfahrer F, Psychogios G, et al.: Resection margins and other prognostic factors regarding surgically treated glottic carcinomas. *J Surg Oncol* 2010;101:131–136.
25. Karatzanis AD, Psychogios G, Zenk J, et al.: Evaluation of available surgical management options for early supraglottic cancer. *Head Neck* 2010;32:1048–1055.
26. Karatzanis AD, Psychogios G, Waldfahrer F, et al.: T1 and T2 hypopharyngeal cancer treatment with laser microsurgery. *J Surg Oncol* 2010;102:27–33.
27. Cmelak AJ, Li S, Goldwasser MA, et al.: Phase II trial of chemoradiation for organ preservation in respectable stage II or IV squamous cell carcinomas of the larynx or oropharynx: Results of Eastern Cooperative Oncology Group Study E2399. *J Clin Oncol* 2007;25:3971–3977.
28. Ritchie JM, Smith EM, Summersgill KF, et al.: Human papillomavirus infection as a prognostic factor in carcinomas of the oral cavity and the oropharynx. *Int J Cancer* 2003;104: 336–344.
29. Mantsopoulos K, Psychogios G, Waldfahrer F, et al.: Surgical treatment of locally limited tonsillar cancer. *Surg Oncol* 2012;21:e13–6. Epub 2011 Nov 18.