

# Surgical management of T1 oropharyngeal carcinoma

Alexander D. Karatzanis, MD, PhD,<sup>1</sup> Georgios Psychogios, MD, PhD,<sup>2</sup> Frank Waldfahrer, MD, PhD,<sup>2</sup> Johannes Zenk, MD, PhD,<sup>2</sup> George A. Velegrakis, MD, PhD,<sup>1</sup> Heinrich Iro, MD, PhD<sup>2\*</sup>

<sup>1</sup>Department of Otorhinolaryngology, Head and Neck Surgery, University of Crete Medical School, Heraklion, Crete, Greece, <sup>2</sup>Department of Otorhinolaryngology, Head and Neck Surgery, University of Erlangen-Nuremberg Medical School, Erlangen, Germany.

**ABSTRACT:** *Background.* The purpose of this study was to assess the efficacy of primary transoral surgery in the management of T1 oropharyngeal carcinoma.

*Methods.* A retrospective evaluation was conducted on the files of all patients treated with primary surgery for pT1 oropharyngeal carcinoma at a tertiary referral center between 1976 and 2005.

*Results.* A total of 223 cases were assessed. Disease-specific survival was 88% and local control 93%. Transoral surgery with the use of CO<sub>2</sub> laser or electrocautery was adopted in every case. Positive surgical margins and regional disease were found to significantly worsen

prognosis. A low rate of complications and satisfactory retention of pharyngeal function were noted.

*Conclusions.* Primary transoral surgical treatment is very effective against T1 oropharyngeal carcinoma. A low rate of complications should be expected. However, in every case complete excision of the tumor must be accomplished and the neck included in the primary treatment plan. © 2011 Wiley Periodicals, Inc. *Head Neck* 34: 1277–1282, 2012

**KEY WORDS:** oropharynx, cancer, carcinoma, survival, local control, laser, surgery, treatment

The oropharynx represents the midportion of the pharynx extending from the plane of the hard palate to the superior surface of the hyoid bone. It consists of the base of tongue, tonsillar regions, soft palate, and lateral and posterior pharyngeal walls.<sup>1</sup> Cancer of the oropharynx makes up for a minority of head and neck neoplasms in the West. It is estimated that only 10.9% of head and neck carcinomas arise in the oropharynx in England and approximately 5000 new cases are diagnosed each year in the United States.<sup>2,3</sup> Approximately 85% to 90% of all cases are squamous cell carcinomas.<sup>4</sup> Despite the low prevalence of oropharyngeal cancer, an increasing incidence has been noted in recent times, with specific preference for younger ages.<sup>5</sup> This increase has been attributed to human papillomavirus (HPV) infection involving mainly the tonsils and base of tongue.<sup>6</sup>

Oropharyngeal cancer is traditionally considered as an aggressive disease, often diagnosed in advanced stage.<sup>7</sup> Yet the overall management of the disease is in significant transit due to recent advances mainly in molecular biology, but also in diagnostic and therapeutic approaches.<sup>4</sup> Surgery and radiotherapy, either alone in early-stage disease or combined in more advanced stages, have traditionally been the mainstay of treatment.<sup>8</sup> Chemotherapy has also been shown to be effective but is re-

served for advanced stages or pathology with adverse features.<sup>9</sup>

In general, nonsurgical treatment has been advocated for limited oropharyngeal tumors, to avoid the morbidity associated with historical resections. This morbidity may also be avoided with the use of minimally invasive surgical techniques such as transoral laser microsurgery (TLM). Such techniques, when feasible, may provide satisfactory oncologic outcome, allow for more accurate disease staging, and also overcome the severe adverse effects of chemoradiotherapy.<sup>8,10,11</sup>

This purpose of this study was to evaluate the experience of a single head and neck oncology center in the surgical management of T1 oropharyngeal carcinoma.

## MATERIALS AND METHODS

A retrospective study was conducted at an academic tertiary referral center (Department of Otorhinolaryngology, Head and Neck Surgery, University of Erlangen-Nuremberg Medical School, Erlangen, Germany). Relevant approval from the institutional review board of the hospital was obtained. The files of all patients treated with primary surgery for pT1 oropharyngeal carcinoma between 1976 and 2005 were evaluated. Patients with previous treatment for the same reason, systemic disease at the time of diagnosis, and histology other than squamous cell carcinoma, as well as patients with second primary tumors at the time of diagnosis were excluded from the study.

All pathology reports were reviewed and staging was conducted in accord with the 2002 American Joint Committee on Cancer (AJCC) and Union Internationale Contre

\*Corresponding author: H. Iro, Department of Otorhinolaryngology, Head and Neck Surgery, University of Erlangen-Nuremberg Medical School, Erlangen, Germany. E-mail: heinrich.iro@uk-erlangen.de

**TABLE 1. Number of cases by surgical technique and affected anatomic subsite of the oropharynx.**

Surgical technique	Anatomic location (total no. of patients)				Total
	Base of tongue	Tonsillar fossa	Soft palate	Lateral and posterior pharyngeal wall	
Diathermy	14	75	72	9	170
Laser	20	12	11	10	53
Total	34	87	83	19	223

le Cancer (UICC) classifications.<sup>12</sup> In accord with TNM staging, T classification describes the size of the primary tumor and whether it has invaded nearby tissue. T1 lesions, assessed in this study, are defined as those that are limited to 1 subsite of the oropharynx and have a largest dimension of  $\leq 2$  cm.

All cases were assessed for disease-specific survival (DSS) as well as local control (LC), with respect to status of surgical margins, N classification, and decision on neck management and adjuvant therapy. Different anatomic subsites, such as tonsillar fossa, base of tongue, soft palate, and lateral/posterior pharyngeal walls, were separately evaluated. In addition, oncologic results were assessed with respect to the different surgical techniques used. Surgical margins were evaluated from primary tumor pathology reports and considered as positive when characterized by the presence of invasive carcinoma at the edge of resection on permanent section pathology.

Five-year DSS was defined using the time from the date of diagnosis to death from the cancer or complications of treatment. This excluded from the patient group all deaths that were not specifically due to the tumor of interest. LC reflected the analysis of tumor recurrence in the primary site and was calculated from the date of surgery to the date of local recurrence diagnosis or date of last follow-up. Local recurrence was defined as invasive carcinoma developing after completion of initial treatment at the anatomic site of the primary tumor. Regional and distal recurrences were defined as the presence of the same tumor in the regional lymph nodes or distant sites, respectively, after the completion of initial treatment. Regional and distal recurrence rates were also calculated from the time of initial therapy completion to the date of regional or distal recurrence diagnosis, respectively, or date of last follow-up.

Cases were additionally evaluated for incidence of major complications and retention of pharyngeal function overall, and by type of surgical procedure. Major complications were defined as those that necessitated prolonged hospitalization, blood transfusion, additional surgery, or admission to the intensive care unit. Pharyngeal function was indirectly evaluated by assessing the incidence of tracheotomies and gastrostomies. Tracheotomies were considered as transient when performed intraoperatively or in the immediate postoperative period but later closed. Accordingly, tracheotomies were considered as permanent in cases in which closing had not been possible at any time postoperatively. Regarding gastrostomies, on the

other hand, only data on permanent procedures were available and therefore assessed.

Statistical analysis was performed using the Kaplan–Meier method and the log-rank test with 95% intervals, and the Fischer’s exact test. Analytical software (SPSS version 18; SPSS Inc, Chicago, IL) for Microsoft Windows was used for the analysis. A value of  $p < .05$  was considered significant.

## RESULTS

A total of 223 cases were included in the study. Among these, 182 were men and 41 women, with a 4.5:1 male to female ratio. Mean age for males was 54.29 years (range, 34–83 years, SD 11.2), and for women 55.9 years (range, 33–82 years, SD 10.7). The mean follow-up period was 65 months, whereas minimum follow-up was 24 months. All cases underwent surgery using a transoral technique. TLM was applied in 53 cases (23.78%) and electrocautery in 170 cases (76.22%). The most commonly involved anatomic subsites included the soft palate and tonsillar fossas. A detailed description of cases according to surgical technique and affected anatomic subsite of the oropharynx is presented in Table 1.

Five-year DSS was 88% overall in this series, whereas LC was 93%. Five-year Kaplan–Meier estimates in accord with N classification are presented in Table 2. With regard to surgical technique, oncologic results were found to be comparable. DSS and LC were 89% and 95% for TLM, and 87% and 91%, respectively, for electrocautery ( $p > .05$ ). Kaplan–Meier analysis of DSS and LC in accord with surgical technique is shown in Figure 1. DSS and LC according to anatomic subsite were also comparable, as can be seen in Table 3. Regional recurrence rate in this series was 2.2% (5/223 cases), whereas distant recurrence rate was 5.4% (9/223 cases).

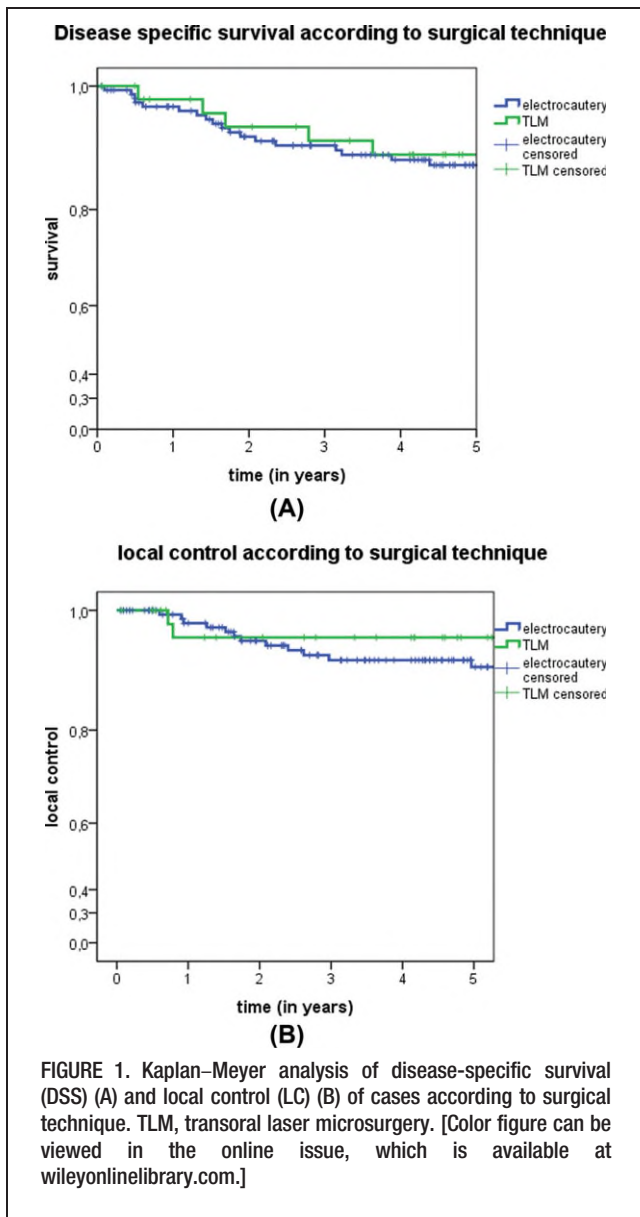
According to pathology reports, negative surgical margins (R0 status) had been achieved in 205/223 cases (92%) in this series. Conversely, 18 cases (8%) had positive surgical margins (R+ status) at the end of surgical treatment. Fifteen of these 18 patients (83.3%) later received adjuvant treatment. Survival rates were found to be significantly better for patients with R0 status compared with R+ status (DSS 88.9% vs 66.4%,  $p = .002$ ). However, the R+ status group was comparatively very small, thus limiting the statistical power of the log-rank test. Kaplan–Meier analysis of DSS in accord with R status is presented in Figure 2.

The presence of regional metastases was found to significantly affect prognosis. DSS was 92% for a total of 123 N0 (70 patients with pN0 and 53 patients with cN0 and no neck dissection) cases, while it was 81.8% ( $p = 0.034$ ) for

**TABLE 2. Disease-specific survival estimates by N classification.**

Factor	DSS estimates by pathologic N classification			
	pN0	pN1	pN2	pN3
Total no. of patients	70	23	70	6
DSS (5-y KM estimate expressed as %)	92	89.6	78.3	75

Abbreviation: DSS, disease-specific survival.



100 cases with neck metastases (N+ classification). Details regarding neck status and relevant prognosis are shown in Table 2. Overall, 169 cases (75.79%) underwent some form of neck dissection. Conversely, in 54 cases, the neck was not surgically treated. In all cN0 cases where the neck was primarily managed, either a bilateral or ipsilateral to the side of tumor, selective dissection of levels II, III, and IV was performed, depending on the exact location of the primary lesion. In cases with known or suspected neck metastases, a modified radical neck dissection was typically performed. Surgery of the neck was performed simultaneously with the primary site procedure or, in some cases, shortly after, when permanent histology results from the primary tumor had been made available. A neck dissection was performed in all patients with known regional disease, except 1 who died due to unrelated reasons before such treatment could be undertaken.

Of 95 patients with cN0 status preoperatively, 42 were treated with a neck dissection, whereas another 53 were not. In those cases in which the patient underwent surgery

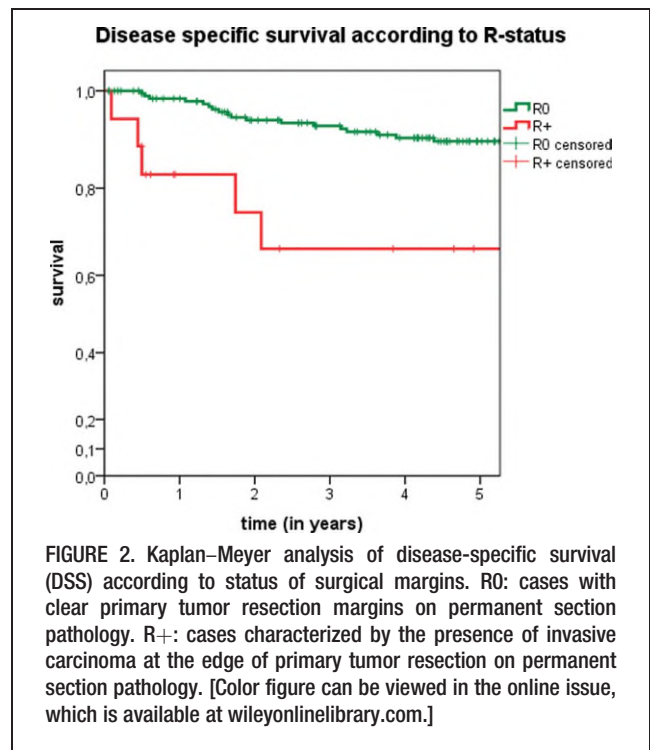
TABLE 3. Disease-specific survival and local control estimates by anatomic subsite.

Factor	Anatomic location				p value*
	Base of tongue	Tonsillar fossa	Soft palate	Lateral and posterior pharyngeal wall	
DSS (5-y KM estimate expressed as %)	90.7	87.5	88.1	85.1	>.05
LC (5-y KM estimate expressed as %)	96.9	94.5	86.4	100	>.05

Abbreviations: DSS, disease-specific survival; LC, local control.  
\* Log-ranked value, checked against level of significance.

occult metastases in the neck specimens were found in 11 patients, with an overall incidence of 26%. However, survival estimates were found to be comparable among cN0 patients that underwent neck surgery and those that did not (92.6% and 95.9%, respectively,  $p = .343$ ). Among cN0 cases in which the neck was not surgically treated, 19 patients received radiotherapy, alone or combined with chemotherapy, whereas 35 did not. Interestingly, survival estimates were comparable between these 2 groups (DSS 94% and 96%, respectively;  $p = .26$ ).

Adjuvant treatment in this series consisted of postoperative radiotherapy, either alone or combined with chemotherapy. Typical indications for adjuvant treatment included the presence of positive surgical margins when further surgery



**TABLE 4. Incidence and type of complications and tracheotomies by surgical technique.**

Factor	Surgical technique (total no. of patients)		
	TLM	Electrocautery	Total
Technique type of complication (total no. of patients, %)			
Bleeding	2 (3.7)	4 (7.5)	6 (11.1)
Aspiration	1 (1.85)	1 (1.85)	2 (3.7)
Fistula	1 (1.85)	2 (3.7)	3 (5.55)
Nerve injury	0 (0)	1 (1.85)	1 (1.85)
Wound healing problems	0 (0)	2 (3.7)	2 (3.7)
Total	4 (7.5)	10 (5.8)	14 (6.2)
Type of tracheotomy (total no. of patients, %)			
Temporary	4 (7.5)	4 (2.3)	8 (3.5)
Permanent	2 (3.7)	5 (2.9)	7 (3.1)
Total	6 (11.3)	9 (5.3)	15 (6.7)

Abbreviation: TLM, transoral laser microsurgery.

was not feasible, advanced neck disease, tumor infiltration depth of >5 mm, extracapsular tumor spread, and infiltration of lymph vessels or nerves on permanent histology. The decision to offer adjuvant therapy was also affected by the choice of surgical management of the neck. Overall, adjuvant treatment was eventually administered in the majority of cases (134/223 patients, 60.1%). Irradiation typically included the primary tumor site and both sides of the neck. However, various changes in treatment protocols as well as technical developments have been noted over the years. Today, nevertheless, routine adjuvant treatment in our center consists of radiation therapy, with a cumulative dosage of 64 Gy using conventional fractionation, plus concomitant cisplatin-based chemotherapy if necessary. Survival estimates were found to be comparable between cases that underwent adjuvant treatment and those that did not (DSS 87.4% and 89.5%, respectively,  $p > .05$ ). In addition, among pN0 cases with negative tumor margins (R0), Kaplan-Meier estimates rates were found to be comparable irrespective of whether the patients received adjuvant treatment (DSS 93.9% vs 92.7%,  $p = .492$ ).

Major complications in this series included bleeding, fistula formation, wound healing problems, and hypoglossal nerve injury. None of these complications was fatal. A detailed presentation can be found in Table 4. Overall incidence of complications was 6.2%. Complication rates were found to be comparable among different techniques. Overall incidence and type of tracheotomies are also presented in Table 4. Permanent tracheotomies were necessary in 3.1% of cases overall. Permanent gastrostomy tubes, on the other hand, were not necessary in any case in this series.

## DISCUSSION

Comparison among available management modalities for head and neck cancer is a complicated issue. Unfortunately, definitive, prospective, randomized controlled studies comparing all available treatment modalities are currently lacking.<sup>7,8,13</sup> Nonrandomized, retrospective data are characterized by numerous flaws, but they are still important because they offer a valuable basis for treatment decision making. This study aimed to retrospec-

tively evaluate the effectiveness of surgical treatment in the management of early oropharyngeal cancer. The data presented here meet many of the limitations of non-randomized data. These limitations include selection bias and use of nonstandard treatment, with modifications made in radiotherapy and chemotherapy protocols over the years. However, important conclusions may still be drawn, in that the series presented here is the largest of surgically managed T1 oropharyngeal carcinoma cases currently in the literature.

Nonsurgical treatment is often considered the standard of care for every stage of oropharyngeal cancer.<sup>7,11</sup> Recent advances in radiotherapy and chemoradiotherapy have focused on improved disease control as well as sparing of normal tissues. These modalities seem to offer similar oncologic results with superior quality of life when compared with radical surgery and adjuvant therapy.<sup>14,15</sup> However, both radiotherapy and chemotherapy are still associated with severe adverse effects. Such effects locally include dysphagia, xerostomia, trismus, difficulties in swallowing, mandibular radionecrosis, fibrosis, and pharyngeal strictures. Systemic adverse effects may also appear, and these include bone marrow toxicity, infections, neuropathy, renal failure, nutritional deficiencies, and fatigue.<sup>14</sup> Considering the fact that oropharyngeal carcinomas have recently shown a tendency to present in younger ages, the burden of toxicity becomes larger because it may persist or even progress for many years. In addition, the use of radiotherapy for limited disease will eliminate the possibility to use this modality again for a second primary tumor, the incidence of which has been known to be as high as 25%.<sup>16</sup>

Aiming toward curability as well as functional organ preservation, many advances have also been made in modern surgical therapies. Transoral techniques, including laser and robotic surgery, may offer effective treatment with decreased morbidity in carefully selected cases of oropharyngeal cancer.<sup>11,17,18</sup> Modern surgical techniques can bypass the functional disabilities related to historical open procedures as well as the potentially severe adverse effects of primary radiotherapy with or without concomitant chemotherapy. These advantages become more obvious during management of limited disease.<sup>8</sup> Surgery, in addition, offers complete pathologic staging, which may serve for more accurate prognosis assessment. Such surgical staging can also spare patients the need for further treatment or at least deintensify adjuvant radiotherapy protocols leading perhaps to reduced toxicity.<sup>8,11</sup> Furthermore, although related prospective studies are lacking, minimally invasive surgical techniques might prove to be more cost-effective than non-surgical therapies when not only costs related to treatment and complications are considered, but also auxiliary costs including days of work lost by the patient and caregivers, costs for transportation to the hospital, as well as long-term consequences of therapy.<sup>8</sup> Cost-effectiveness should be a critical issue during treatment decision making in these financially challenging times.

An important disadvantage of primary surgery, however, remains the fact that a relatively high percentage of patients will eventually require postoperative radiotherapy with or without chemotherapy. These patients will therefore face the increased morbidity and costs of combined

treatment.<sup>8,11</sup> In the present series, 134 patients (60.1%) eventually received adjuvant treatment. Unfortunately, it is extremely difficult to preoperatively detect which patient will require further treatment after surgery because most indications for that rely on permanent histology. Results from this study showed that pN0 cases with clear surgical margins have an excellent prognosis, independent from adjuvant treatment administration, suggesting that at least cases with limited disease may be managed with surgery alone, as long as negative margins can be achieved. In any case, patients with early oropharyngeal cancer should be thoroughly counseled regarding the advantages and disadvantages of having single-modality radiotherapy or transoral primary surgery, which eventually could involve additional treatment with perhaps increased morbidity and similar overall survival benefits.

In the present series, all patients were operated on using a transoral technique. Excellent oncologic results were generally noted (DSS 88% and LC 93%). The efficiency of primary surgery for early oropharyngeal cancer, as previously reported, was therefore confirmed.<sup>8,10,19</sup> This was even true for patients with regional disease (DSS 81.8% for N+ cases), also in agreement with previous reports.<sup>20</sup>

The 2 surgical techniques used for primary tumor excision included TLM and extirpation with simple use of electrocautery. Regarding TLM, a standard piecemeal technique for tumor excision, in accord with the principles of Steiner,<sup>21</sup> has been routinely used in our institution. With this technique, narrow margin control is allowed with maximum preservation of function. The laser is typically used as a cutting instrument rather than to vaporize the tumor. Frozen section control is necessary as an indicator for further resection. For surgery with the use of electrocautery, on the other hand, en block resection is typically performed. Both techniques have shown, however, comparable oncologic results as well as complication rates.

TLM has been popularized in the surgical treatment of the upper aerodigestive system due to many distinctive advantages. This method essentially represents a minimally invasive surgical approach, which allows tumors to be removed with limited sacrifice of healthy tissue and acceptable retention of function.<sup>21</sup> Additional advantages of TLM include low morbidity and mortality, avoidance of tracheostomy, shorter periods of hospitalization, and low cost.<sup>21,22</sup> For readily accessible lesions of the oropharynx, however, most of these advantages may be enjoyed with the simple use of diathermy. Eventually, it is in anatomic areas with limited access, such as the base of tongue, where the endoscopy-based technique of TLM seems to gain the upper hand.

Most common anatomic subsites found to be involved were the soft palate and tonsillar fossas. Incidence for base of tongue was found to be relatively low, coming in disagreement with the literature.<sup>11</sup> Such a discrepancy may be attributed to the fact that only cases with early disease were studied here, whereas base of tongue lesions tend to present with more advanced disease. No significant differences were found, however, regarding disease control and survival estimates in accord with anatomic location.

Status of surgical margins was found to significantly affect prognosis. Patients with R0 status showed better

Kaplan-Meier estimates compared with R+ cases (Figure 2). The significance, therefore, of achieving tumor-free surgical margins should be emphasized. It has been previously established that patients with head and neck cancer exhibiting positive resection margins have significantly higher rates of local or regional recurrence and even show decreased survival.<sup>23-26</sup> This study confirms the importance of surgical margins in primary surgical treatment of early oropharyngeal lesions. However, a relatively high rate of positive margins was found in this series (8%). Unfortunately, the reasons for this are difficult to detect due to the retrospective nature of the study.

The presence of nodal metastases was found to significantly worsen prognosis (Table 2). Furthermore, in cases with cN0 classification preoperatively, neck dissection revealed a 26% incidence of occult metastases on permanent histology. These 2 findings suggest that an aggressive management strategy should be adopted for the neck, even in cases with early oropharyngeal lesions without clinically evident regional disease. However, in the present series, cN0 cases that were not surgically addressed showed comparable survival rates with those that were. Results remained comparable even for those among the former cases that did not receive adjuvant treatment. Such discrepancies could perhaps be explained by the retrospective nature of the study, particularly the fact that neck as well as adjuvant treatment indications and protocols have evolved during time, thus complicating the assessment of results, and should be regarded as a study weakness. In any case, including the neck in the primary treatment plan of limited oropharyngeal cancer seems warranted in current practice.<sup>11</sup> In addition, the role of other strategies such as sentinel lymph node biopsy needs further evaluation in the future.<sup>27,28</sup>

In the present series, 31 cases (13.8%) received postoperative chemotherapy in addition to radiotherapy. Reasons related to such a decision are difficult to detect retrospectively because this was individualized in most cases. However, typical indications would include positive surgical margins, multiple nodes involved, extracapsular nodal spread, and lymphangiosis carcinomatosa. It is noted here that the specific role of chemotherapy for the treatment of early oropharyngeal lesions is not yet established. On the other hand, improved disease control and survival rates have been repeatedly demonstrated with concurrent administration of chemotherapy with radiotherapy in patients with advanced carcinomas of the head and neck.<sup>11</sup> Moreover, specific evidence supports platinum-based chemotherapy-induced radiosensitization for locally advanced oropharyngeal carcinomas.<sup>29</sup> Taxane-based protocols have also been effectively used for these cases.<sup>30</sup> With regard to the neck, the presence of extracapsular spread constitutes a major risk factor, typically indicating the addition of chemotherapy in the treatment algorithm.<sup>8</sup> As already mentioned, however, the exact role of chemotherapy as well as the optimal chemotherapeutic regimen and radiotherapy protocol against oropharyngeal cancer are still not known.<sup>11</sup>

A low complication rate was noted in this series. Fortunately, none of these complications proved to be fatal. The most common complication was postoperative bleeding, which typically occurred within the first 24 hours

postoperatively. Cases with hemorrhage were led back to the operation table and were transorally managed under general anesthesia. Other isolated types of complications were in fact too rare to be separately commented on. On the other hand, a relatively high rate of tracheotomies was noted. This may be partly related to the fact that some cases included date back to the earliest days of laser use in head and neck surgery where a higher rate of tracheotomies would be expected. On the contrary, long-term swallowing function was found to be excellent, as evidenced by the zero rate of permanent gastrostomy tubes in this series.

This retrospective study did not focus on the prognostic effect of HPV infection in oropharyngeal cancer. An increasing amount of evidence, however, supports an etiologic association of oropharyngeal carcinoma with oncogenic HPV.<sup>4-6</sup> The biology and behavior of HPV-associated carcinomas seem to be distinct from non-HPV-associated cases and a more favorable prognosis should be anticipated for the former.<sup>30,31</sup> The prognostic significance and therapeutic implications of HPV infection in oropharyngeal lesions certainly warrant further attention.

In conclusion, primary transoral surgical treatment is very effective against T1 oropharyngeal carcinomas. In every case, however, complete excision of the tumor must be accomplished. Moreover, the high incidence of occult nodal metastases supports strategies that include the neck in the primary treatment plan. Prospective, randomized studies are necessary to fully clarify the indications, type, and even intensity of adjuvant therapy for T1 oropharyngeal lesions. However, primary transoral surgery seems to be a first-line treatment option for these cases, with a low rate of complications and satisfactory long-term functional results.

## Acknowledgements

The authors thank Philipp Grundtner for the valuable assistance during statistical analysis of the data.

## REFERENCES

- Kraus DH, Joe JK. Neoplasms of the oral cavity and oropharynx. In: Ballenger JJ, Snow JB, editors. *Ballenger's otorhinolaryngology: head and neck surgery*, 16th ed. Hamilton, Ontario, Canada: BC Decker; 2003. pp 1408-1440.
- Rhys Evans PH, Patel SG, Henk JM. Tumours of the oropharynx. In: Rhys Evans PH, Montgomery PQ, Gullane PQ, editors. *Principles and practice of head and neck oncology*. London: Martin Dunitz, an imprint of Taylor & Francis Group; 2003. pp 415-430.
- Jemal A, Siegel R, Ward E, Hao Y, Xu J, Tun MJ. Cancer statistics 2009. *CA Cancer J Clin* 2009;59:225-249.
- Cohan DM, Popat S, Kaplan SE, et al. Oropharyngeal cancer: current understanding and management *Curr Opin Otolaryngol Head Neck Surg* 2009;17:88-94.
- Gillison ML. Current topics in the epidemiology of oral cavity and oropharyngeal cancers. *Head Neck* 2007;29:779-792.
- Chaturvedi AK, Engels EA, Anderson WF, Gillison ML. Incidence trends for human papillomavirus-related and -unrelated oral squamous cell carcinomas in the United States. *J Clin Oncol* 2008;26:612-619.
- Makitie AA, Pukkila M, Laranne J, et al. Oropharyngeal carcinoma and its treatment in Finland between 1995 and 1999: a nationwide study. *Eur Arch Otorhinolaryngol* 2006;263:139-143.
- Walvekar RR, Li RJ, Gooding WE, et al. Role of surgery in limited (T1-2, N0-1) cancers of the oropharynx. *Laryngoscope* 2008;118:2129-2134.
- National Comprehensive Cancer Network (NCCN). 2007 NCCN clinical practice guidelines in oncology head and neck cancers. Available at: <http://www.nccn.org>.
- Shin HA, Lim YC, Jeong HM, Choi EC. Role of primary surgery for early-stage (T1-2N0) squamous cell carcinoma of the oropharynx. *Oral Oncol* 2009;45:1063-1066.
- Haigentz MJR, Silver CE, Corry J, et al. Current trends in initial management of oropharyngeal cancer: the declining use of open surgery. *Eur Arch Otorhinolaryngol* 2009;266:1845-1855.
- American Joint Committee on Cancer (AJCC). *Manual for staging of cancer*. 6th ed. New York: Springer-Verlag; 2002. pp 47-57.
- Christiansen H, Hermann RM, Martin A, et al. Long-term follow-up after transoral laser microsurgery and adjuvant radiotherapy for advanced recurrent squamous cell carcinoma of the head and neck. *Int J Radiat Oncol Biol Phys* 2006;65:1067-1074.
- Mowry SE, Ho A, Lotempio MM, et al. Quality of life in advanced oropharyngeal carcinoma after chemoradiation versus surgery and radiation. *Laryngoscope* 2006;116:1589-1593.
- Allal AS, Nicourar K, Mach N, Dulguerov P. Quality of life in patients with oropharynx carcinomas: assessment after accelerated radiotherapy with or without chemotherapy versus radical surgery and postoperative radiotherapy. *Head Neck* 2003;25:833-839.
- Galati LT, Myers EN, Johnson JT. Primary surgery as treatment for early squamous cell carcinoma of the tonsil. *Head Neck* 2000;22:294-296.
- Weinstein GS, O'Malley BW, Cohen MA, Quon H. Transoral robotic surgery for advanced oropharyngeal carcinoma. *Arch Otolaryngol Head Neck Surg* 2010;136:1079-1085.
- Weinstein GS, Quon H, O'Malley BWJr, Kim GG, Cohen MA. Selective neck dissection and deintensified postoperative radiation and chemotherapy for oropharyngeal cancer: a subset analysis of the University of Pennsylvania transoral robotic surgery trial. *Laryngoscope* 2010;120:1749-1755.
- Grant DG, Salassa JR, Hinni ML, Pearson BW, Perry WC. Carcinoma of the tongue base treated by transoral laser microsurgery, part one: untreated tumors, a prospective analysis of oncologic and functional outcomes. *Laryngoscope* 2006;116:2150-2155.
- Reddy AN, Eisele DW, Forastiere AA, Lee DJ, Westra WH, Califano JA. Neck dissection followed by radiotherapy or chemoradiotherapy for small primary oropharynx carcinoma with cervical metastasis. *Laryngoscope* 2005;115:1196-1200.
- Steiner W, Ambrosch P, editors. *Endoscopic laser surgery of the upper aerodigestive tract*. Stuttgart, Germany: Georg Thieme Verlag; 2000.
- Grant DG, Salassa JR, Hinni ML, Pearson BW, Hayden RE, Perry WC. Transoral laser microsurgery for recurrent laryngeal and pharyngeal cancer. *Otolaryngol Head Neck Surg* 2008;138:606-613.
- Jackel M, Ambrosch P, Martin A, Steiner W. Impact for re-resection for inadequate margins on the prognosis of upper aerodigestive tract cancer treated by laser microsurgery. *Laryngoscope* 2007;117:350-356.
- Karatzanis AD, Waldfahrer F, Psychogios G, et al. Resection margins and other prognostic factors regarding surgically treated glottic carcinomas. *J Surg Oncol* 2010;101:131-136.
- Karatzanis AD, Psychogios G, Zenk J, et al. Evaluation of available surgical management options for early supraglottic cancer. *Head Neck* 2010;32:1048-1055.
- Karatzanis AD, Psychogios G, Waldfahrer F, et al. T1 and T2 hypopharyngeal cancer treatment with laser microsurgery. *J Surg Oncol* 2010;102:27-33.
- Stoeckli SJ, Alkureishi LW, Ross GL. Sentinel node biopsy for early oral and oropharyngeal squamous cell carcinoma. *Eur Arch Otorhinolaryngol* 2009;266:787-793.
- Santaolalla F, Sanchez JM, Ereno C, Sanchez A, Martinez A. Comparative study of patients with and without sentinel lymph node biopsy (SLNB) in oral and oropharyngeal cancer: is SLNB an accurate and useful procedure? *Acta Oto-Laryngol* 2009;129:199-204.
- Denis F, Garaud P, Bardet E, et al. Final results of the 94-01 French Head and Neck Oncology and Radiotherapy Group randomized trial comparing radiotherapy alone with concomitant radiochemotherapy in advanced stage oropharynx carcinoma. *J Clin Oncol* 2004;22:69-76.
- Cmelak AJ, Li S, Goldwasser MA, et al. Phase II trial of chemoradiation for organ preservation in respectable stage II or IV squamous cell carcinomas of the larynx or oropharynx: results of Eastern Cooperative Oncology Group Study E2399. *J Clin Oncol* 2007;25:3971-3977.
- Ritchie JM, Smith EM, Summersgill KF, et al. Human papillomavirus infection as a prognostic factor in carcinomas of the oral cavity and the oropharynx. *Int J Cancer* 2003;104:336-344.
- Fakhry C, Westra WH, Li S, et al. Improved survival of patients with human papillomavirus-positive head and neck squamous cell carcinoma in a prospective clinical trial. *J Natl Cancer Inst* 2008;100:261-269.