

# Function-Preserving Therapy for Jugulotympanic Paragangliomas: A Retrospective Analysis from 2000 to 2010

Julian Künzel, MD; Heinrich Iro, MD; Joachim Hornung, MD; Michael Koch, MD;  
Christoph Brase, MD; Gunther Klautke, MD; Johannes Zenk, MD

**Objectives/Hypothesis:** Treatment for jugulotympanic paragangliomas (JTPs) is shifting from radical toward function-preserving surgery. Alternative primary treatments are available, such as stereotactic radiotherapy (SRT) and radiosurgery. The aim of this study was to analyze the results after primary function-preserving surgery with or without adjuvant radiotherapy, or primary SRT, in the treatment of JTPs.

**Study Design:** Retrospective analysis.

**Methods:** From 2000 to 2010, 45 patients (mean age, 62.5 years) received function-preserving treatment for JTPs—four type A paragangliomas (8.9%), 19 type B (42.2%), 13 type C (28.9%), and nine type D (20%) in the Fisch classification. The patients were retrospectively assigned to three groups: primary function-preserving surgery, primary stereotactic radiotherapy, and close follow-up. The end points for analysis were long-term tumor control, cranial nerve function, and hearing.

**Results:** A total of 64.4% of the patients ( $n = 29$ ) received primary surgery, with complete resection in 18. Eleven patients had surgical tumor reduction, with fractionated postoperative radiotherapy (mean 53.5 Gy; range, 50–56 Gy) in five cases and radiosurgery (18 Gy) in one case; five patients received close follow-up. Twelve patients (26.7%) underwent primary radiotherapy (11 with SRT [mean, 50 Gy]; one with radiosurgery [16 Gy]). Four patients (8.9%) received a wait-and-scan strategy. The mean follow-up was 46.8 months. The overall tumor control rate was 97.2%.

**Conclusions:** With these high tumor control rates, consistent with the literature, function-preserving therapy for JTPs currently appears to offer the greatest benefit for patients.

**Key Words:** Paraganglioma, glomus tumor, lateral skull base, foramen jugulare.

**Level of Evidence:** 2b.

## INTRODUCTION

Paragangliomas in the head and neck region are highly vascularized tumors that in the majority of cases are benign. The incidence is two to five times higher in women. The age at manifestation is between 40 and 60.<sup>1,2</sup> Paragangliomas only show histopathological signs of malignancy or metastases to nonendocrine tissue in approximately 3% of cases. The mean tumor doubling rate is 4.2 years.<sup>3</sup> Overall, the lesions represent 0.6% of all tumors in the head and neck region and 80% of tumors in the jugular foramen.<sup>4</sup> Jugulotympanic paragangliomas (JTPs) are thus the most frequent neoplasms in the middle ear and the second most frequent in the region of the petrous bone.

There has been intensive debate over the various treatment options ever since Rosenwasser's first description of JTPs as a carotid body tumor of the middle ear.<sup>5</sup> The treatment of choice is moving away from radical resection toward surgical tumor reduction aimed at preserving function.<sup>6,7</sup> Local control of any residual tumor can be achieved using postoperative stereotactic radiotherapy (SRT), or conservatively with a wait-and-scan strategy. Alternative primary treatment options, depending on the individual situation (e.g., age, comorbidity, multifocal lesions, and risk of injury to cranial nerves [CNs]), include SRT (50–60 Gy) or radiosurgical procedures such as the gamma knife or CyberKnife (Accuray, Sunnyvale, CA) (12–18 Gy).<sup>8,9</sup> The complex anatomy of the skull base and the highly vascularized nature of these tumors are a serious challenge for surgeons even today, although the further development of microsurgical operating techniques has also made complete removal of large JTPs possible.<sup>10–13</sup> Various surgical access routes have been described in the literature, such as the widely used infratemporal access route pioneered by Fisch et al.<sup>7,14–20</sup>

The aim of the present study was to analyze our own results with primary function-preserving surgery with or without adjuvant radiotherapy or primary SRT in the treatment of JTPs.

From the Department of Otorhinolaryngology, Head and Neck Surgery (J.K., H.I., J.H., M.K., C.B., J.Z.), and the Department of Radiotherapy (G.K.), University of Erlangen–Nuremberg Medical School, Erlangen, Germany.

The authors have no funding, financial relationships, or conflicts of interest to disclose.

Send correspondence to Julian Künzel, MD, Department of Otorhinolaryngology, Head and Neck Surgery, University of Erlangen–Nuremberg, Waldstrasse 1, 91054 Erlangen, Germany. E-mail: julian.kuenzel@uk-erlangen.de

TABLE I.  
The Fisch Classification of Jugulotympanic Paragangliomas.

Class	Characteristics
A	Limited to mesotympanum (glomus tympanicum)
B	Limited to hypotympanum, mesotympanum, and mastoid with/without erosion of the jugular bulb (glomus hypotympanicum)
C	Involvement and destruction of infralabyrinthine and apical compartments
C1	No invasion of vertical carotid canal; destruction of the jugular foramen
C2	Invasion of vertical carotid canal between foramen and bend
C3	Invasion along horizontal carotid canal
C4	Invasion of foramen lacerum and along carotid canal into cavernous sinus
D	Intracranial extension
De1	≤2-cm dural displacement
De2	>2-cm dural displacement
Di1	≤2-cm intradural extension
Di2	>2-cm intradural extension
Di3	Inoperable intracranial invasion

## MATERIALS AND METHODS

A total of 45 patients with JTPs were treated with function-preserving intent in the Department of Ear, Nose and Throat Medicine and the Department of Radiotherapy at Erlangen–Nuremberg University Hospital between 2000 and 2010. The patients consisted of 10 males (22.3%) and 35 females (77.7%), with an average age of 62.5 years (range, 35–85 years). The JTPs were categorized in accordance with the Fisch classification as follows: type A, 8.8% (n = 4); type B, 42.2% (n = 19); type C1, 24.4% (n = 11); type C3, 4.4% (n = 2); type De1, 6.6% (n = 3); type De2, 6.6% (n = 3); type Di1, 2.2% (n = 1); and type Di2, 4.4% (n = 2) (Tables I and II).

Clinical examinations of the CNs were carried out both before and after treatment, in addition to endoscopic examinations and pure-tone audiography. Before the start of treatment, all of the patients underwent detailed vestibular nerve diagnosis. Facial nerve function was classified in accordance with the House-Brackmann system.<sup>21</sup> For further diagnosis, computed tomography (CT) and magnetic resonance imaging (MRI) of the head and neck region were carried out in addition to ultrasonography. Preoperatively, digital subtraction angiography was carried out in most cases in JTPs that were size B or larger. Embolization of the afferent vessels was carried out during this procedure when possible. Preoperative catecholamine analyses were not part of the routine diagnostic program. No clinical signs of increased secretion of neuropeptides or vasoactive amines were present in any of the cases.

For further analysis, the patients were retrospectively assigned to three groups relative to the different treatment procedures used. The first group consisted of patients in whom a surgical procedure was basically indicated with the aim of achieving resection of the JTP with healthy margins. When CN paresis was already evident preoperatively, the surgical procedure was more radical than when the caudal CNs were still intact. Following function-preserving tumor reduction, postoperative SRT was indicated depending on other factors present, such as the patient's age, comorbid conditions, and the size of the tumor.

The second group consisted of patients in whom primary SRT was carried out. The indication for primary radiotherapy was established particularly when a surgical procedure was

likely to involve a high risk of damage to intact CNs. In addition, the indication depended on the patient's age and concomitant diseases, and the patient's wishes and preferences were also taken into account.

The third group consisted of patients with smaller type A or B JTPs, who were reluctant to undergo treatment in view of their general lack of symptoms. They were initially assigned to a tight follow-up schedule representing a wait-and-scan strategy.

MRIs were carried out at annual check-ups. In addition to freedom from recurrences, criteria for successful tumor control following primary surgical procedures included a postoperatively stable residual tumor or a progression-free primary lesion following primary SRT. Group 3 was not included in the tumor control analysis.

Auditory function analysis was carried out by calculating the medians of differences at four frequencies (500 Hz, 1,000 Hz, 2,000 Hz, and 4,000 Hz) between the preoperative and postoperative air-conduction and bone-conduction audiograms.

Statistical analysis was carried out using SPSS Statistics version 19.0.0.1 (IBM, Armonk, NY). Group comparisons relative to a target variable were carried out using the Pearson  $\chi^2$  test and the Kruskal-Wallis test. The significance level was  $P \leq .05$ .

## Surgical Access Routes

Three different surgical access routes were basically used. Depending on the location and size of the JTP, a classic tympanic access route was used for types A and B, with additional mastoidectomy and tympanotomy if necessary. In type C and D JTPs, or when CN pareses were already present preoperatively, the standard approach used was a transmastoid–transcervical (TMTC) route. In the procedure described by Glasscock et al., this involved enlarging the retroauricular–transmastoid access. As well as making it possible to check structures in the jugular foramen and posterior cranial fossa, this also makes it possible to expose the internal carotid artery, internal jugular vein, and the cervical course of the caudal CNs.<sup>22</sup> A Fisch anterior transposition of the mastoid part of the facial nerve was carried out in two cases.<sup>23</sup> Finally, depending on the intraoperative findings, combinations or modifications of the surgical access routes described by Fisch and Al-Mefty et al. (types A–D) were used when needed.<sup>7,10</sup> If reconstruction of the facial nerve was necessary, it was done in the same session using a bridging graft from the great auricular nerve.

## Planning and Implementation of Radiotherapy

The radiotherapy methods used involved either fractionated SRT or radiosurgery. All but one of the patients received

TABLE II.  
The Fisch Classification of Jugulotympanic Paragangliomas for the Individual Groups in the Present Study.

Fisch Classification	Group 1, Surgery, n = 29, No. (%)	Group 2, SRT, n = 12, No. (%)	Group 3, Wait and Scan, n = 4, No. (%)
A	2 (6.9)	1 (8.3)	1 (25)
B	13 (44.8)	3 (25)	3 (75)
C1	4 (13.8)	7 (58.3)	—
C3	2 (6.9)	—	—
De1	3 (10.3)	—	—
De2	3 (10.3)	—	—
Di1	1 (3.4)	—	—
Di2	1 (3.4)	1 (8.3)	—

SRT = stereotactic radiotherapy.

TABLE III.  
The Frequencies of Preoperative and Postoperative Symptoms Relative to the Individual Groups.

	Group 1, Surgery, No. (%)		Group 2, SRT, No. (%)		Group 3, Wait and Scan, No. (%)
	Preoperative	Postoperative	Preoperative	Postoperative	
Tinnitus	25 (86.2)	7 (24.1)	12 (100)	9 (75)	4 (100)
Hypoacusis	21 (72.4)	19 (65.5)	11 (91.6)	10 (83.3)	2 (50)
Vertigo	6 (20.7)	2 (6.9)	4 (33.3)	3 (25)	—
Dysphagia	2 (6.9)	3 (10.3)	—	1 (8.3)	—
Dysphonia	3 (10.3)	5 (17.2)	—	—	—
Ear pressure	6 (20.7)	5 (17.2)	—	—	3 (75)
Otalgia	3 (10.3)	—	2 (16.6)	—	—

SRT = stereotactic radiotherapy.

radiotherapy in a Novalis Shaped Beam Surgery Center (Brainlab Ltd., Feldkirchen, Germany). Another patient underwent gamma-knife irradiation at an outside radiotherapy department at his own request. For radiotherapy planning, all of the patients underwent contrast MRI (with a slice thickness of 1–3 mm) as well as receiving individually prepared thermoplastic stereotactic masks and a planning CT with a slice thickness of 1 to 2 mm. Using the Novalis Brain Scan planning system, MRI and CT data were fused for contouring of the target volume (a macroscopic tumor with a safety margin of 2–3 mm). The dosage was standardized to the reference point (in accordance with the International Commission on Radiation Units & Measurements Report No. 50); individual doses of 1.8 to 2.0 Gy, conventionally fractionated, were administered up to a final dosage of 50 to 56 Gy. Dosages of 12 to 18 Gy were administered in radiosurgery.

## RESULTS

A reddish, gleaming, or pulsating space-occupying lesion in a hypotympanic location was seen on otoscopy in 95.5% of cases (n = 43). The most frequent symptoms reported were pulsatile tinnitus in 91.1% of cases (n = 41) and hypoacusis in 75.5% of cases (n = 34). Facial nerve paresis was seen before treatment in 4.4% of the patients (n = 2) and paresis of the glossopharyngeal nerve (CN IX) in 6.6% (n = 3). Paresis of the vagus nerve (CN X) and of the hypoglossal nerve (CN XII) were each present in 11.1% (n = 5).

Tumor resection was carried out via a classic tympanic access route in 41.4% of cases (n = 12), via an additional mastoidectomy with anterior and posterior tympanotomy in 13.8% of cases (n = 4), and via a TMTC access route in 44.8% of cases (n = 13). Overall, anterior transposition of the facial nerve was only carried out in 6.8% of cases (n = 2). Procedure-related tracheotomy was not required in any cases. An intraoperative cerebrospinal fluid fistula occurred in seven cases (type B, n = 1; type D, n = 6), and was treated directly with muscle, fascia, or fat transplants in each case. Temporary cerebrospinal fluid drains were also placed in five of these patients. In one case, a mastoid revision was carried out during the course of treatment to close a persistent cerebrospinal fluid fistula.

Preoperatively, 11 cranial nerve deficiencies (CNDs) were present in a total of six patients. Postoperatively,

this figure increased to 18 CNDs in a total of seven patients. Five of these patients had peripheral facial nerve paresis (House II, n = 2; House IV, n = 1; House VI, n = 2). The surgical procedure thus led to an increase in CNDs by 63.3%. In one patient with pareses in the jugular CN group, temporary nutrition via a percutaneous endoscopy gastrostomy became necessary due to marked dysphagia. The precise distribution of JTPs in accordance with the Fisch classification in the individual groups and the frequencies of preoperative and postoperative clinical symptoms are shown in Tables II and III. A detailed listing of pretreatment and post-treatment CN function and its course is presented in Tables IV and V.

## Primary Surgical Therapy

**Complete tumor removal.** A total of 29 patients (64.4%; seven males, 22 females) underwent primary surgery, with macroscopically complete tumor removal in 18 cases (mean age, 58.7 years; range, 38–80 years). The mean follow-up period was 56.5 months (range, 3–107 months), although three patients were lost to follow-up. In one female patient with a progressive recurrence, neither a revision procedure nor postoperative SRT have yet been carried out, due to progressive Alzheimer's disease. In another case, surgical revision due to a progressive recurrence was carried out. A recurrence-

TABLE IV.  
Distribution of Preoperative and Postoperative Cranial Nerve Deficits in the Two Treatment Arms.

CND	Group 1, Surgery		Group 2, SRT	
	Preoperative	Postoperative	Preoperative	Postoperative
CN VII	2	5	—	1
CN IX	2	3	1	2
CN X	4	5	1	1
CN XI	—	2	—	—
CN XII	3	3	2	2
Total	11	18	4	6

CND = cranial nerve deficit; SRT = stereotactic radiotherapy; CN = cranial nerve.

TABLE V.  
Course in Patients With Post-Treatment Cranial Nerve Deficits.

Fisch Classification	Age, yr	Preoperative Status	Treatment	Postoperative Status
B	66	CN VII (House IV)	TMTC, great auricular nerve	CN VII (House II)
B	73	Asymptomatic	SRT	CN IX
C1	45	CN X	TMTC, anterior transposition	CN X, IX, XI, XII
C1	69	CN IX, CN X, CN XII	SRT	CN IX, X, XII
C1	69	Asymptomatic	TMTC + gamma knife	CN XI
C1	38	Asymptomatic	Gamma knife	CN VII (House IV)
De1	70	CN VII (House IV), CN X	TMTC + SRT	CN VII (House VI), X
De2	64	CN IX, X, XII	TMTC	CN VII (House II), IX, X, XII; PEG
De2	35	CN XII	TMTC, great auricular nerve	CN VII (House VI with eyelid weight), X, XII
Di2	78	CN XII	SRT	CN XII
Di2	71	CN IX, X, XII	TMTC, anterior transposition	CN VII (House IV), IX, X, XII

CN = cranial nerve; TMTC = transmastoid-transcervical (route); SRT = stereotactic radiotherapy.

free course has since been observed in this patient for 6 years. All of the other patients remained free of recurrences up to the time of data collection. The tumor control rate following complete resection was thus 93.3%.

**Tumor reduction with or without postoperative SRT.** Maximum tumor reduction was achieved in 11 patients (mean age, 58.2 years; range, 35–75 years). In most cases, these were older patients in whom a small amount of residual tumor in the area of the internal carotid artery or jugular cranial nerve group was left in order to preserve function. Postoperative SRT was indicated in six patients (mean age, 62 years; range, 37–75 years). In a 37-year-old female patient with unremarkable neurologic findings, postoperative SRT was carried out at the patient's own urgent request, following a macroscopic resection with healthy margins for a size B JTP. Postoperative SRT was administered in fractionated doses in five cases (mean, 53.5 Gy; range, 50–56 Gy) and in one case with radiosurgery (18 Gy). The mean follow-up period was 42.7 months (range, 11–95 months). A total of five patients (mean age, 53.6 years; range, 35–71 years) declined the postoperative radiotherapy offered, and tight check-up examinations were agreed for the follow-up period. In these patients, the mean follow-up period was 49.4 months (range, 3–116 months). Independently of whether or not postoperative radiotherapy was carried out, imaging findings have shown progression-free residual tumors in all cases to date. The tumor control rate in these patients was thus 100%.

### Primary Radiotherapy

Primary SRT was indicated in 26.7% of the patients (n = 12; two males, 10 females). Their average age was 70 years (range, 38–85 years). SRT was carried out on a fractionated basis in 91.6% of these patients (n = 11). The mean radiation dose administered was 50 Gy (range, 32–54 Gy). Radiosurgical treatment was administered in one case (gamma knife, 16 Gy). Before treatment, four CNDs were identified in a total of two

patients. Pareses in the jugular cranial nerve group were found in one patient with a type C1 lesion before the start of treatment. This female patient declined surgery. During the course of SRT, acute dyspnea developed, requiring tracheotomy, so that the SRT had to be interrupted at a total dosage of 32 Gy. This patient also withdrew from follow-up. However, it can be assumed that the existing CNDs persisted even after treatment was interrupted. In summary, six CNDs were seen after treatment in a total of four patients. The number of CNDs observed thus increased overall by 33.3% (Tables IV and V). Two patients withdrew from follow-up. In 10 patients, the mean follow-up period was 37.5 months (range, 4–85 months). A stable primary lesion was seen in 70% of cases during the course, and regression in the size of the primary lesion was seen in 30%. The tumor control rate following primary radiotherapy was thus 100%.

### Patients Without Therapy (Wait and Scan)

A wait-and-scan strategy was followed in four patients (8.9%; one male, three females). The patients' mean age was 69 years (range, 50–81 years). No CNDs were present at the time of diagnosis. All of the patients were largely free of symptoms and have so far declined treatment. One patient died independently of the tumor, with no evidence of tumor progression. No tumor progression was seen in this group up to the time of data collection, with a mean follow-up period of 35.6 months.

In summary, the median follow-up period in all groups was 46.8 months (range, 3–116 months), although five patients were lost to follow-up. The overall tumor control rate in the study patients was 97.2%.

### Hearing

For assessment of hearing after the completion of each treatment in groups 1 and 2, the medians of differences ( $\Delta$ ) between the pretreatment and post-treatment bone-conduction and air-conduction audiograms at four frequencies from 500 Hz to 4 kHz were calculated. The

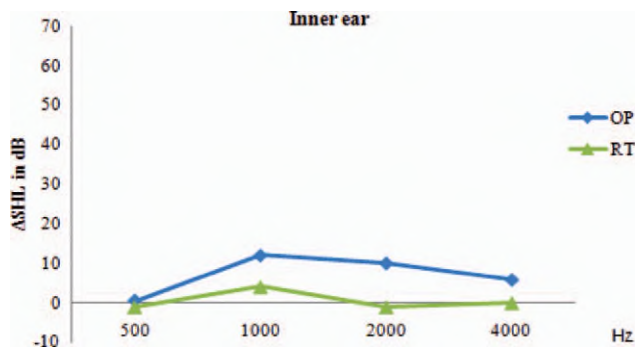


Fig. 1. Medians of differences in pretreatment and post-treatment bone conduction (sensorineural hearing loss [ $\Delta$ SHL]) from 500 Hz to 4 kHz (x-axis) relative to the different treatment methods used. OP (blue) = surgery; RT (green) = radiotherapy. [Color figure can be viewed in the online issue, which is available at [wileyonlinelibrary.com](http://wileyonlinelibrary.com).]

results are shown in the graphs in Figures 1 and 2. Overall, 32 patients (71.1%) reported subjective hypoacusis before treatment (Table III). Following primary surgery, three of 18 patients with preoperative hypoacusis reported subjective hearing improvement, ranging up to normal hearing. Only one patient, in group 1, reported a newly developed impairment of hearing. After the completion of primary SRT, only one patient reported subjective hearing improvement.

Due to the small sizes of the groups and above all the difference in sizes between the two treatment groups, it was not possible to carry out any statistical tests assuming a normal distribution. However, a nonparametric test (the Kruskal-Wallis test) showed no significant differences with regard to auditory function between groups 1 and 2.

## DISCUSSION

Treatment for JTPs should ensure a high level of tumor control and should maintain function in CNs VII to XII. As far as possible, an attempt should also be made to preserve hearing. During treatment planning, the risks of surgery have to be weighed critically in comparison with the natural growth behavior of JTPs. To date, various surgical access routes in the lateral skull base have been developed to reduce the morbidity associated with the operation.<sup>15,18,23–25</sup> Jackson et al. and Watkins et al. report mortality rates of 0% to 4% after surgical treatment.<sup>26,27</sup> It is generally accepted that there is an absolute indication for a primary surgical procedure when patients are suffering from neurological effects of expansive tumor growth such as raised intracranial pressure or hydrocephalus.<sup>28</sup> The degree of long-term tumor control achieved with radiotherapy has often been questioned, on the assumption that it causes tumor necrosis not by directly destroying tumor cells, but rather through fibrosis and occlusion of the tumor's vessels.<sup>27,29</sup> According to Mumber and Greven, vital tumor cells can lead to recurrences even 10 years after the completion of radiotherapy.<sup>30</sup> On the other hand, Spector et al. and Hawthorne et al., among others, have demonstrated good local control after radiotherapy.<sup>31,32</sup> Several

studies in recent years have shown that SRT is effective in postoperative and also in primary therapy for JTPs.<sup>2,33,34</sup> In general, SRT is considered to be indicated in older symptomatic patients or in situations in which there is a high risk of damaging intact CNs. Various authors have reported tumor control rates of 76% to 100% after SRT.<sup>9,35–37</sup> Despite the good results obtained with radiotherapeutic procedures, limitations of the method have also been reported in the literature. These include unclear tumor histology, the need for rapid reduction of the tumor mass when there are CN symptoms, tumor sizes larger than 3 cm, and tumor spread to below the base of the skull.<sup>2,37</sup> It has also been reported that there is a risk of rare but severe radiation-induced long-term sequelae, such as osteoradionecroses and radiogenic secondary malignancies in the irradiation field.<sup>38</sup>

In the patients included in the present study, a combined procedure with limited surgery and postoperative SRT was used in six cases to preserve nerve function. This achieved a reduction in symptoms while maintaining a low risk to major CNs. Miller et al. also regard the combination of surgery and postoperative radiotherapy as highly promising for treatment of JTPs in the future.<sup>34,39</sup>

Ivan et al. and Springate et al. report tumor control rates of 86% with a primary surgical procedure,<sup>40,41</sup> 69% with subtotal tumor resection,<sup>40</sup> 71%<sup>40</sup> to 90%<sup>41</sup> with a combined procedure involving subtotal resection and adjuvant SRT, and 93%<sup>41</sup> to 95%<sup>40</sup> with primary SRT. The results of the present study are quite comparable with these data, with local control in 93% to 100% of cases, taking into account the relevant follow-up intervals and heterogeneous tumor sizes.

Ivan et al. analyzed the data from 46 publications, in which the great majority of JTPs treated were size C and D, with regard to the rate of post-treatment CNs after surgical treatment or SRT. Increases in paresis postoperatively were seen in CN IX in 38% of cases, in CN X in 26%, in CN XI in 40%, and in CN XII in 18%. After SRT, the rates were much lower, at 9% to 12%. The authors concluded that the higher morbidity in the caudal CNs following surgical treatment is not associated with increased tumor control, and that SRT thus

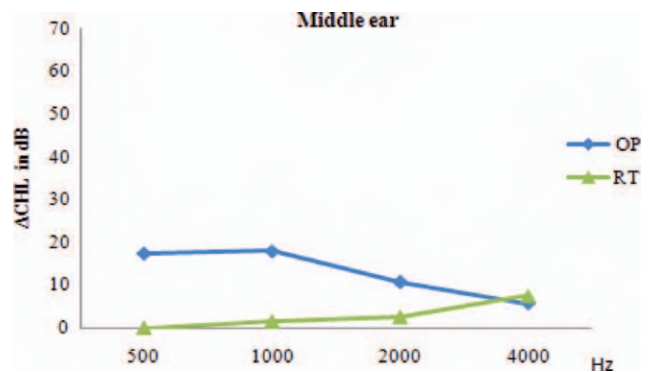


Fig. 2. Medians of differences between pretreatment and post-treatment air conduction (conductive hearing loss [ $\Delta$ CHL]) from 500 Hz to 4 kHz (x-axis) relative to the different treatment methods used. OP (blue) = surgery; RT (green) = radiotherapy. [Color figure can be viewed in the online issue, which is available at [wileyonlinelibrary.com](http://wileyonlinelibrary.com).]

appears to be superior to primary surgical treatment, taking the current follow-up intervals into account.<sup>40</sup> In the present study, an increase in CNDs of 64% was observed after surgical procedures in comparison with the preoperative status, although in contrast to Ivan et al., facial nerve pareses are also included in that figure. When only the caudal cranial nerve group is included, the postoperative increase in pareses observed was 30.8%, which again is quite comparable with the literature data mentioned above. The number of pareses observed in the caudal CN group increased by 25% after SRT. There was thus a trend in the present group of patients toward less CN morbidity after SRT in comparison with a primary surgical procedure, with a similar degree of tumor control.

A study by Cosetti et al. reports on three patients who showed no tumor growth over periods of up to 33 years without therapy.<sup>42</sup> Particularly in largely asymptomatic patients with small JTPs who are reluctant to undergo treatment, or in patients at an advanced age, a "wait-and-scan" strategy may be justifiable. Four of the patients in the present study have not so far had any tumor progression during a mean follow-up period of 36 months.

Only a few studies to date have given special attention to the preservation of hearing in the context of treatment for JTPs.<sup>43–45</sup> The infratemporal access route described by Fisch, with closure of the external auditory canal and removal of the middle ear structures, is regarded in many institutions as the standard approach, although it is always associated with severe conductive hearing loss.<sup>7</sup> The present analysis shows no statistically significant differences between primary surgery and primary radiotherapy with regard to postoperative auditory function. This makes it clear that it is possible to preserve hearing in the context of surgical treatment for JTPs, with good tumor control at the same time.

## CONCLUSION

Almost without exception, smaller JTPs of sizes A and B can be resected completely using a diversified surgical approach. Larger JTPs of sizes C and D can be treated either with primary surgery or stereotactic radiotherapy with function-preserving intent and with a comparable degree of tumor control. Particularly in young patients with unilateral tumors and evident CN pareses, the authors regard a primary surgical procedure aiming for resection with healthy margins as the treatment of choice. Especially in older patients with normal cranial nerve function and acceptable auditory function, radical surgery should be regarded particularly critically, as a loss of function in the major cranial nerves is usually followed by a difficult and stressful rehabilitation process. The extent of the surgery should therefore be based on the intraoperative findings. In many situations, reducing the size of the tumor while preserving function represents an adequate treatment option. On the basis of the results presented here, the question arises of whether postoperative radiotherapy

may in general only be indicated when there is objective evidence of tumor progression.

## Acknowledgment

The authors are most grateful to Mr. Philipp Grundtner for his valuable support with the statistical analysis of the data.

## BIBLIOGRAPHY

1. Thedinger BA, Glasscock ME III, Cueva RA, Jackson CG. Postoperative radiographic evaluation after acoustic neuroma and glomus jugulare tumor removal. *Laryngoscope* 1992;102:261–266.
2. Chen PG, Nguyen JH, Payne SC, Sheehan JP, Hashisaki GT. Treatment of glomus jugulare tumors with gamma knife radiosurgery. *Laryngoscope* 2010;120:1856–1862.
3. Boedeker CC, Ridder GJ, Schlipper J. Paragangliomas of the head and neck: diagnosis and treatment. *Fam Cancer* 2005;4:55–59.
4. Batsakis JG, Farber ER. Chemodectomas of the head and neck. *Univ Mich Med Cent J* 1967;33:123–130.
5. Rosenwasser H. Carotid body tumor of the middle ear and mastoid. *Arch Otolaryngol* 1945;41:64–67.
6. Kollert M, Minovi AA, Draf W, Bockmuhl U. Cervical paragangliomas—tumor control and long-term functional results after surgery. *Skull Base* 2006;16:185–191.
7. Fisch U. Infratemporal fossa approach to tumours of the temporal bone and base of the skull. *J Laryngol Otol* 1978;92:949–967.
8. Bianchi LC, Marchetti M, Brait L, et al. Paragangliomas of head and neck: a treatment option with CyberKnife radiosurgery. *Neurol Sci* 2009;30:479–485.
9. Varma A, Nathoo N, Neyman G, et al. Gamma knife radiosurgery for glomus jugulare tumors: volumetric analysis in 17 patients. *Neurosurgery* 2006;59:1030–1036.
10. Al-Mefty O, Fox JL, Rifai A, Smith RR. A combined infratemporal and posterior fossa approach for the removal of giant glomus tumors and chondrosarcomas. *Surg Neurol* 1987;28:423–431.
11. Gardner G, Cocke EW Jr, Robertson JT, Trumbull ML, Palmer RE. Combined approach surgery for removal of glomus jugulare tumors. *Laryngoscope* 1977;87:665–688.
12. Gardner G, Cocke EW Jr, Robertson JT, Trumbull ML, Palmer RE. Glomus jugulare tumours—combined treatment: part I. *J Laryngol Otol* 1981;95:437–454.
13. Gardner G, Cocke EW Jr, Robertson JT, Trumbull ML, Palmer RE. Glomus jugulare tumours—combined treatment: part II. *J Laryngol Otol* 1981;95:567–580.
14. Capps FC. Glomus jugulare tumours of the middle ear. *J Laryngol Otol* 1952;66:302–314.
15. Al-Mefty O, Teixeira A. Complex tumors of the glomus jugulare: criteria, treatment, and outcome. *J Neurosurg* 2002;97:1356–1366.
16. Jackson CG. Glomus tympanicum and glomus jugulare tumors. *Otolaryngol Clin North Am* 2001;34:941–970.
17. Jenkins HA, Fisch U. Glomus tumors of the temporal region. Technique of surgical resection. *Arch Otolaryngol* 1981;107:209–214.
18. Leonetti JP, Brackmann DE, Prass RL. Improved preservation of facial nerve function in the infratemporal approach to the skull base. *Otolaryngol Head Neck Surg* 1989;101:74–78.
19. Maniglia AJ, Sprecher RC, Megerian CA, Lanzieri C. Inferior mastoidectomy—hypotympanic approach for surgical removal of glomus jugulare tumors: an anatomical and radiologic study emphasizing distances between critical structures. *Laryngoscope* 1992;102:407–414.
20. Pensak ML, Jackler RK. Removal of jugular foramen tumors: the fallopian bridge technique. *Otolaryngol Head Neck Surg* 1997;117:586–591.
21. House JW, Brackmann DE. Facial nerve grading system. *Otolaryngol Head Neck Surg* 1985;93:146–147.
22. Glasscock ME III, Harris PF, Newsome G. Glomus tumors: diagnosis and treatment. *Laryngoscope* 1974;84:2006–2032.
23. Fisch U, Pillsbury HC. Infratemporal fossa approach to lesions in the temporal bone and base of the skull. *Arch Otolaryngol* 1979;105:99–107.
24. Brackman D, Kinney S, Fu K. Glomus tumor: diagnosis and management. *Head Neck Surg* 1987;9:306–311.
25. Brackmann DE. The facial nerve in the infratemporal approach. *Otolaryngol Head Neck Surg* 1987;97:15–17.
26. Jackson CG, McGrew BM, Forest JA, Netteville JL, Hampf CF, Glasscock ME III. Lateral skull base surgery for glomus tumors: long-term control. *Otol Neurotol* 2001;22:377–382.
27. Watkins LD, Mendoza N, Cheesman AD, Symon L. Glomus jugulare tumours: a review of 61 cases. *Acta Neurochir (Wien)* 1994;130:66–70.
28. Gottfried ON, Liu JK, Couldwell WT. Comparison of radiosurgery and conventional surgery for the treatment of glomus jugulare tumors. *Neurosurg Focus* 2004;17:E4.
29. Carrasco V, Rosenman J. Radiation therapy of glomus jugulare tumors. *Laryngoscope* 1993;103(suppl 60):23–27.
30. Mumber MP, Greven KM. Control of advanced chemodectomas of the head and neck with irradiation. *Am J Clin Oncol* 1995;18:389–391.

31. Spector GJ, Compagno J, Perez CA, Maisel RH, Ogura JH. Glomus jugulare tumors: effects of radiotherapy. *Cancer* 1975;35:1316–1321.
32. Hawthorne MR, Makek MS, Harris JP, Fisch U. The histopathological and clinical features of irradiated and nonirradiated temporal paragangliomas. *Laryngoscope* 1988;98:325–331.
33. Thompson BG, Coffey RJ, Flickinger JC, Lunsford LD. Stereotactic radiosurgery of small intracranial tumors: neuropathological correlation in three patients. *Surg Neurol* 1990;33:96–104.
34. Miller JP, Semaan M, Einstein D, Megerian CA, Maciunas RJ. Staged Gamma Knife radiosurgery after tailored surgical resection: a novel treatment paradigm for glomus jugulare tumors. *Stereotact Funct Neurosurg* 2009;87:31–36.
35. Ganz JC, Abdelkarim K. Glomus jugulare tumours: certain clinical and radiological aspects observed following Gamma Knife radiosurgery. *Acta Neurochir (Wien)* 2009;151:423–426.
36. Pollock BE. Stereotactic radiosurgery in patients with glomus jugulare tumors. *Neurosurg Focus* 2004;17:E10.
37. Jordan JA, Roland PS, McManus C, Weiner RL, Giller CA. Stereotactic radiosurgery for glomus jugulare tumors. *Laryngoscope* 2000;110:35–38.
38. Tanbouzi Husseini S, Piccirillo E, Taibah A, Paties CT, Rizzoli R, Sanna M. Malignancy in vestibular schwannoma after stereotactic radiotherapy: a case report and review of the literature. *Laryngoscope* 2011;121:923–928.
39. Miller JP, Semaan MT, Maciunas RJ, Einstein DB, Megerian CA. Radio-surgery for glomus jugulare tumors. *Otolaryngol Clin North Am* 2009;42:689–706.
40. Ivan ME, Sughrue ME, Clark AJ, et al. A meta-analysis of tumor control rates and treatment-related morbidity for patients with glomus jugulare tumors. *J Neurosurg* 2011;114:1299–1305.
41. Springate SC, Haraf D, Weichselbaum RR. Temporal bone chemodectomas—comparing surgery and radiation therapy. *Oncology (Williston Park)* 1991;5:131–137.
42. Cosetti M, Linstrom C, Alexiades G, Tessema B, Parisier S. Glomus tumors in patients of advanced age: a conservative approach. *Laryngoscope* 2008;118:270–274.
43. Gjuric M, Seidinger L, Wigand ME. Long-term results of surgery for temporal bone paraganglioma. *Skull Base Surg* 1996;6:147–152.
44. Jackson CG, Haynes DS, Walker PA, Glasscock ME III, Storper IS, Josey AF. Hearing conservation in surgery for glomus jugulare tumors. *Am J Otol* 1996;17:425–437.
45. Gjuric M, Wigand ME, Weidenbecher M, Wolf SR, Seidinger L. Function preserving surgery of glomus jugulare tumors. An achievable goal? *HNO* 1997;45:983–989.