

Primary Surgical Treatment of T2 Oropharyngeal Carcinoma

GEORGIOS PSYCHOGIOS, MD, PhD,* KONSTANTINOS MANTSOPOULOS, MD, PhD,

JULIAN KUENZEL, MD, PhD, MICHAEL KOCH, MD, PhD, JOHANNES ZENK, MD,

ULI HARREUS, MD, PhD,** FRANK WALDFAHRER, MD, PhD, AND HEINRICH IRO, MD, PhD[†]

Department of Otorhinolaryngology, Head and Neck Surgery, Friedrich Alexander University of Erlangen-Nuremberg, Erlangen, Germany

Background: The optimal management of oropharyngeal carcinoma (OPC) is not yet proven. The aim of this study is to analyze the outcome of primary surgical management of T2 cancers of the oropharynx.

Methods: All patients treated with primary surgery for pT2 OPCs between 1984 and 2005 were evaluated retrospectively. Two hundred and twenty eight cases were assessed for disease-specific survival (DSS) as well as local control (LC) estimates, with respect to tumor location, surgical technique, status of surgical margins, N classification, and adjuvant therapy. Cases were also evaluated for major complications and functional results.

Results: DSS was 73.2% and LC 88.9%. Carcinoma of the tonsils showed a significantly better DSS than lesions of the base of the tongue (DSS = 76.3 vs. 60.2%, $P = 0.02$). DSS estimates in patients with pN0–1 classification were significantly better in comparison with pN2–3 (83.6 vs. 64.5%, $P = 0.018$). Patients who were given adjuvant treatment had a better prognosis. The incidence of occult neck metastases was 17% and complications rate 12.7%.

Conclusions: Primary surgical treatment of T2 OPC proved to be an effective treatment modality with a low rate of complications and satisfactory functional results. Complete tumor excision is essential and a neck dissection is justified. Most patients need adjuvant radiotherapy.

INTRODUCTION

Oropharyngeal carcinoma (OPC) represents a minority of head and neck tumors in western nations. It is an aggressive disease mostly diagnosed at an advanced stage because of cervical metastases, even when the primary tumor remains small. The management of patients with primary oropharyngeal squamous cell carcinoma (OPC) remains controversial. The National Comprehensive Cancer Network (NCCN) Guidelines state that early-stage (T1–2 N0–1) OPC can be treated by either primary surgery or radiotherapy (RT). In contrast, the recommended treatment of choice for advanced disease (Tx N2–3) is chemoradiotherapy (CRT) [1].

Nonsurgical therapies, which utilize combinations of chemotherapy and RT, have become popular treatments for advanced OPC. Studies have shown that RT, particularly intensity modulated radiotherapy (IMRT), in combination with chemotherapy offers similar oncologic and functional results with lower rates of severe complications [2–4]. Given that the majority of patients ultimately require adjuvant RT, there has therefore been a trend towards primary (chemo)radiotherapy as the definitive treatment in many centers throughout the world [5,6]. However, surgical techniques have also improved greatly in the past years [7]. With the aid of better instrumentation and optics, tumor resection can nowadays be achieved transorally. The extent of neck dissection (ND) can often be reduced with good results [8]. Microvascular reconstruction after resection of advanced tumors has greatly improved the rate and extent of the patient's functional recovery [9,10]. Advances in imaging have improved the recognition of primary tumor boundaries and metastatic disease [11]. New pathology techniques have increased the speed and accuracy of intraoperative histological assessment. Surgical treatment also allows accurate staging of the disease and avoidance of RT for patients with clear margins and no negative prognostic factors.

Most studies examining the outcome of primary surgery concentrate on early carcinomas [12–14]. But with OPCs, even small primary tumors usually present at an advanced stage because of

cervical metastasis. It is therefore interesting to investigate the outcomes of surgically treated small OPCs in different stages of the disease. The aim of this paper was to analyze the oncologic and functional outcome of definitive primary surgical management of patients with T2 cancer of the oropharynx, with or without adjuvant therapy. To the best of our knowledge this is the largest study of T2 OPCs to date. Since prospective trials do not exist and are unlikely to be performed in the near future, retrospective data still provide meaningful information.

METHODS

A retrospective study was conducted at an academic tertiary care center. The main inclusion criterion was previously untreated T2 squamous cell carcinomas (SCC) of the oropharynx that had undergone definitive surgical treatment between 1984 and 2005. Patients

Abbreviations: OPC, oropharyngeal squamous cell carcinoma; NCCN, National Comprehensive Cancer Network; RT, radiotherapy; IMRT, intensity modulated radiotherapy; SCC, squamous cell carcinoma; AJCC, American Joint Committee on Cancer; UICC, Union Internationale Centre Contre Cancer; DSS, disease-specific survival; LC, local control; TLM, transoral laser microsurgery; OS, Overall survival.

[†]Professor and Chairman.

*Correspondence to: Georgios Psychogios, MD, PhD, Department of Otorhinolaryngology, Head and Neck Surgery Friedrich Alexander University of Erlangen-Nuremberg Waldstrasse 1, 91054 Erlangen, Germany; Fax: 0049-9131-8533833. E-mail: Georgios.Psychogios@uk-erlangen.de, gpsychogios@gmail.com.

**Correspondence to: Uli Harreus, MD, PhD, Department of Otorhinolaryngology, Head and Neck Surgery, Ludwig Maximilian University, Munich, Germany. E-mail: uli.harreus@uk-erlangen.de

TABLE I. Number of Patients According to Shown Characteristics

Characteristics	Total number of patients (relative frequency in %)
Age (years)	Mean: 56.1 years, Median: 55.0 years, Range: 33–83 years
Follow up	Mean: 63.6 months, range: 1–247 months
Gender	Male: 184 (80.7%), female: 44 (19.3%)
Smoking	Smokers: 198 (86.9%), ex-smokers: 14 (6.1%), non-smokers: 16 (7.0%)
Surgical technique	TLM: 61 (26.8%), electrocautery: 148 (64.9%), combined: 19 (8.3%)
Adjuvant treatment	None: 32 (14.0%), RT: 147 (64.9%), RCT: 49 (21.5%)
pN-classification	pN0: 71 (31.1%), pN1: 22 (9.6%), pN2: 95 (41.7%), pN3: 23 (10.1%); no ND: 17 (7.5%)
Differentiation	Well: 9 (3.9%), moderate: 128 (56.1%), poor: 85 (37.3%), not differentiate: 7 (3.1%)

previously treated for head and neck carcinomas, those with distant metastases at the time of diagnosis, histology other than SCC, and with second primary tumors at the time of diagnosis were excluded from the study. Approval was obtained from the institutional review board of the hospital.

The operation and pathology reports were reviewed and staging was re-evaluated according to the 2002 American Joint Committee on Cancer (AJCC) and Union Internationale Centre Centre Cancer (UICC) classification [15].

The endpoints for the analysis were disease-specific survival (DSS) and local control (LC). DSS was defined using the time from the date of diagnosis to death from the cancer or complications of treatment. Time to LC was calculated from the date of initial diagnosis to the date of the most recent clinical review when local recurrence was confirmed. Local recurrence was defined as invasive carcinoma developing at the anatomic site of the primary tumor after completion of initial treatment. Calculations of 5-year overall survival, DSS, and LC were made with Kaplan–Meier estimates and compared by the means of a log-rank test using 95% intervals. A *P*-value of less than 0.05 was considered significant. All statistical analyses were performed using SPSS Version 19 (SPSS Inc., Chicago IL) for Microsoft Windows.

Cases were also evaluated for major complications and maintenance of pharyngeal function. Major complications were defined as those which necessitated prolonged hospitalization, blood transfusion, additional surgery, or admission to the intensive care unit. Pharyngeal function was evaluated indirectly from the incidence of tracheotomies and gastrostomies.

Resection of the primary tumor was performed using transoral electrocautery in most cases where the tumor could be accessed directly, or transoral laser microsurgery (TLM) in cases where the tumor site was deeper (e.g., base of the tongue, inferior pole of the tonsils). Combined resection was necessary in a few cases. En block resection of the tumor was performed whenever possible. Most patients also had ND. In cases with known or suspected neck metastases, a modified radical ND was usually performed. In all cN0 cases

with primary management of the neck, selective dissection of levels II, III, and IV was usually performed, either ipsilateral to the tumor, or bilaterally, depending on the exact location of the primary lesion. Surgery of the neck was performed simultaneously with the primary site procedure or shortly after, once the definitive histology results from the primary tumor were available.

RESULTS

A total of 228 patients met the final inclusion criteria. Detailed patient demographics are presented in Table I.

Overall 5-year survival (OS) was 61.6%, DSS was 73.2%, and LC 88.9%. Mean time to first local recurrence was 2.49 years (range 2.5 months–6.1 years). Regional recurrence occurred in 10 patients and distant metastasis in 17 out of the 228 patients.

Most commonly involved primary anatomic subsites were the tonsillar region (i.e., tonsil, tonsillar fossa, and pillars), followed by the base of the tongue. Most patients were operated on transorally. Electrocautery was used in 148 (64.9%) and TLM in 61 (26.8%) patients. 19 (8.3%) patients were operated on transcervically or with a combined approach. A detailed description of cases according to surgical technique and anatomic subsite of the oropharynx affected is presented in Table II. DSS and LC according to anatomic site are also shown in Table II. A direct comparison of the survival rates of all four subsites showed no statistically significant differences. But a comparison of the two main regions of the oropharynx showed that carcinoma of the tonsils has a significantly better DSS than that of the tongue base (76.3 vs. 60.2%, *P* = 0.02).

Survival estimates according to surgical technique showed no statistically significant differences. DSS and LC were 74.5 and 88.6% for electrocautery, 69.7 and 88.3% for TLM, and 75.8 and 93.8% for patients where an external approach was used (*P* = n.s.).

After re-evaluating the pathology reports of all patients, clear surgical margins (R0) had been achieved in 197 patients (86.4) whereas positive margins (R+) were found in 31 patients (13.6%) at the end of surgical treatment. DSS was 75.1% for cases with R0 status and

TABLE II. Number of Cases According to Surgical Technique and Anatomic Site of the Oropharynx Affected.

	Anatomic site				Total
	Base of tongue	Tonsillar region	Soft palate	Lateral and posterior pharyngeal wall	
Surgical technique					
Diathermy	19	91	29	9	148
Laser	30	19	9	3	61
External	9	7	0	3	19
Total	58	117	38	15	228
DSS	60.2%	76.3%	76.4%	91.7%	<i>P</i> = n.s.
LC	87.3%	89.1%	84.6%	100%	<i>P</i> = n.s.

TABLE III. Disease-Specific Survival (DSS) Estimates According to N Classification.

	pN0 stage II	pN1 stage III	pN2 stage IVa	pN3 stage IVb	No ND	All
Number of cases	71	22	95	23	17	228
DSS (%)	81.9	89.3	64.2	67.7	67.4	73.2

60.8% for R+ patients. ($P = 0.2$ but curves meet several times at the beginning).

ND was performed in 211 patients, while the neck was not treated surgically in 17 patients. Stage II was diagnosed in 71 patients (31.1%), stage III in 22 (9.6%), and stage IV in 118 (51.8%). Survival estimates according to the N classification and pathological stage are shown in Table III. Statistical analysis was not possible because many groups had only small numbers of patients. We therefore divided the population into two subgroups: 93 patients with pN0–1 and 118 patients with pN2–3. DSS rates were found to be significantly better in patients with a pN0–1 classification than with pN2–3 (83.6 vs. 64.5%, $P = 0.018$) (Fig. 1).

ND was performed in all except four cases with a clinical suspicion of regional disease. Two of these died of postoperative bleeding before the ND could be performed. One patient was found to be R+ and the interdisciplinary team suggested RCT without further surgery because of his poor general health, and the last patient refused a second operation after successful removal of the primary tumor. This patient received postoperative RT. Fifty nine patients presented with a preoperative cN0 status. Out of these patients, 46 underwent elective ND, with occult metastases found in eight of them, giving an incidence of 17.4%.

The majority of patients received postoperative adjuvant treatment (196/228 patients, 86%). Postoperative RT alone was administered to 149 patients and combined CRT in 47. Irradiation typically included the primary tumor site and both sides of the neck. Various changes in treatment protocols, as well as technical developments, have been noted over the years. Today, however, typical indications for adjuvant treatment include the presence of positive surgical margins when further surgery is not feasible, advanced neck disease, tumor infiltration depth of more than 5 mm, extracapsular tumor spread, and infiltration of lymph vessels or nerves on histology. A cumulative dosage of 60–64 Gy is usually applied using conventional or accelerated

fractionation, plus concomitant cisplatin-based chemotherapy if necessary. Survival estimates were found to be significantly better in patients who were given adjuvant treatment than those who were not (DSS 74.6 vs. 51.0%, respectively, $P = 0.002$; LC 90.2 vs. 80.2%, $P = 0.05$). However, it has to be noted that the second group (32 cases) includes patients who died because of postoperative complications or were excluded from adjuvant treatment because of poor general health. On the other hand, of the 69 patients with pN0 status and negative tumor margins (R0), 49 received adjuvant treatment and 20 did not. Survival estimates were found to be similar in the two groups (DSS 81.5 vs. 80.0%, $P = 0.361$).

All major complications were documented. These included postoperative bleeding, fistula formation, aspiration, wound-healing problems, and nerve injury. Overall incidence of complications was 12.7% (29 cases). Thirteen patients suffered postoperative bleeding, which proved fatal in three cases (1.3% mortality rate). Three patients got a fistula, which was treated surgically. Five patients showed delayed wound healing and two patients had nerve injuries. Six patients had permanent aspiration. Table IV shows the complication rates according to surgical technique. Overall incidence and type of tracheostomy and gastrostomy tubes according to surgical procedure is presented in Table V. Permanent tracheostomies were necessary in nine (3.9%) and gastrostomies in eight (3.5%) patients.

DISCUSSION

The optimal management of OPC is not yet proven. The treatment options vary widely between institutions but there has been a significant change over the past years. Many centers have replaced the traditional approach of radical surgery and adjuvant (chemo)radiotherapy with primary CRT. One important study behind this change is that of Parson et al. [2], showing similar oncologic results in combination with better functional outcomes in the radiation group. However, studies often compare very old surgical data neglecting the fact that surgery has also evolved from mutilating to function-oriented techniques.

There are several retrospective studies dealing with primary surgery of early OPCs [12–14,16] but none solely investigating the outcome of pathological T2 OPCs. The large number of patients included in our study provides the opportunity to investigate various interesting parameters and subgroups. One negative aspect of this study is the lack of data concerning HPV status which seems to play an important role in pathogenesis and prognosis of OPCs [17].

The survival results in this study were comparable with other studies. Rösli et al. [16] presented a large group of OPC. 152 cases with T2 had a 5-year OS of 63.1% and DSS of 77.5%. Patients were divided into three groups: Surgery alone, surgery combined with RT, and primary (chemo)radiotherapy. The DSS was 77.5, 78.1, and 73.8%, respectively. Unfortunately no further details are given about patient numbers and characteristics in each group. Moncrieff et al. [14] retrospectively studied 92 patients with primarily operated T1–2 OPC and showed a DSS of 83% and an LC of 87%. Adjuvant RT was given in 62% of the cases. The T2 subgroup consisted of 66 patients with a DSS of 78%. It has to be noted that many of these patients (30/66) did not have any nodal involvement. Cosmidis et al. [12] specifically studied the results of surgery without adjuvant RT in 53 patients with T1–2 N0 OPC and complete tumor resection.

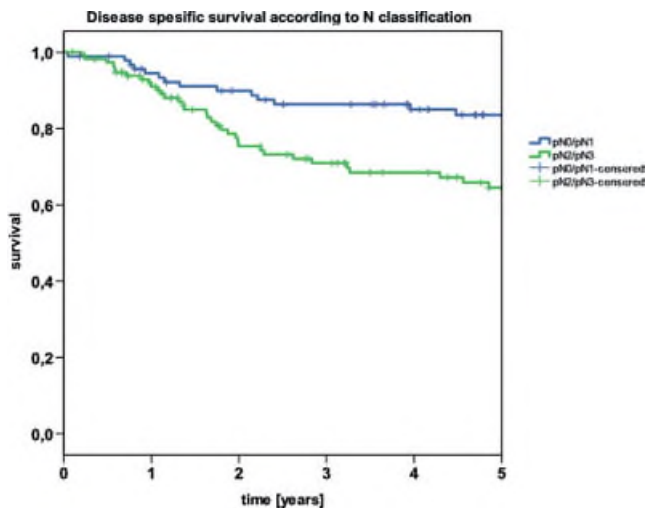


Fig. 1. Disease-specific survival according to N-classification. [Color figure can be seen in the online version of this article, available at <http://wileyonlinelibrary.com/journal/jso>]

TABLE IV. Incidence and Type of Complication According to Surgical Technique.

Complication	Surgical technique			Total (n = 228)
	TLM (n = 61)	Electrocautery (n = 147)	Combined approach (n = 19)	
Bleeding	5	7	1	13
Aspiration	3	2	1	6
Fistula	0	2	1	3
Nerve injury	0	1	1	2
Wound-healing problems	0	4	1	5
Total (%)	8 (13.1)	16 (10.9)	5 (26.3)	29 (12.7)

They achieved a DSS of 100%. All seven patients who developed a local recurrence in this study could be treated by a second operation and/or RT. This shows that surgery alone can produce excellent results in this infrequent group of patients, sparing them the side effects of RT, and keeping this therapeutic weapon in reserve. Table VI summarizes all recent studies which give survival estimates for T2 OPC.

One of the most interesting results of this study is the difference in survival between patients with carcinoma of the tonsillar region and those with tongue base lesions. These anatomic subsites were the two most commonly involved (51.3 vs. 25.4%), which is consistent with the literature [6,14]. The rate of R1 resection, 17.1% (20/117) for tonsillar carcinomas and 12.1% (7/58) for base of the tongue, and the nodal status of stage IV disease, 52% (61/117) and 62% (36/58), respectively, do not justify this difference. One explanation for the worst survival with tongue base carcinomas could be the anatomy itself, which makes transoral resection more challenging, while involvement of muscle tissue that retracts significantly after the first resection makes an incomplete resection (R1) very difficult to correct. Mäkitie et al. [18] also reported the worst outcome for tumors of the base of the tongue. Some studies of early OPC do not even include carcinomas in this location [12].

In the present study, most of the cases were operated transorally. Both techniques showed comparable oncologic results and complication rates (Table IV). For easily accessible lesions in the tonsillar region and the soft palate, resection can be accomplished easily with electrocautery, making laser treatment unnecessary. On the other hand, in anatomic areas with limited access such as the base of the tongue, endoscopic TLM is invaluable [19].

In this study 61.4% of the patients (140/228) showed some form of nodal involvement and 17.4% of the cN0 cases who underwent ND had occult lymph node metastasis [11]. The 17 patients with no treatment of the neck also had a DSS similar to stage IV patients. An aggressive strategy to treat the neck in T2 OPC is therefore justified. A solitary lymph node metastasis less than 3 cm does not worsen the prognosis in this group of patients, which is consistent with the literature [20]. And for this reason, the need for adjuvant RT in this population is currently being investigated in a prospective

multicenter study [21]. On the other hand pN2–3 (stage IV) cases showed significantly worse survival even though all patients received adjuvant (chemo)radiotherapy. The only patients having an equally good survival rate without adjuvant therapy are the pT2pN0 cases. In this case series, 20/228 (8.8%) patients were able to forgo adjuvant RT without any detriment to the DSS. Because of the small number of patients (20) who were treated with surgery alone, this result cannot be considered definitive and needs further validation.

One of the main arguments for the primary use of concurrent (chemo)radiotherapy as standard therapy for oropharyngeal lesions was the better side effect profile with comparable oncologic results. Parson et al. [2] examined the literature between 1970 and 2000 and found a morbidity rate of less than 1% in the RT ± ND group compared with more than 3% in the S ± RT group. In recent years several studies demonstrated better survival rates with CRT than with RT in the management of OPC, making it the standard if nonsurgical treatment is chosen [22,23]. This, of course, leads to an increase in acute and chronic side effects. Pederson et al. [24] studied 127 cases with base of tongue carcinoma treated with CRT (median radiation dose of 72.5 Gy) with an OS of 58.2%. They found four patients who died from treatment-related toxicity prior to completing therapy and another four whose deaths were attributed to late toxicity, giving a mortality rate of 6.3%. Late grade 3 and 4 toxicity was also recorded in 23 patients (18.1%). This study showed relatively few complications (12.7%) and mortality (1.3%) rates. The need for permanent tracheostomies and gastrostomies was low and mainly related to persistent aspiration. Other authors have also reported low complication rates [25]. Furthermore new developments in surgical techniques could further improve the rate of adverse events. Leonhardt et al. [26] have investigated the role of robotic-assisted transoral surgery for OPCs. This appears to be a safe and effective technique which could prove to be an important development, particularly for tongue base lesions that are difficult to access.

Another benefit of primary surgical treatment is the precise histology which permits accurate classification of the disease and adjustment of adjuvant treatment [27]. The absence of cervical node disease on the contralateral side, for instance, means that no adjuvant RT is necessary on that side [28]. Nevertheless the current study

TABLE V. Incidence of Tracheostomy and Gastrostomy According to Surgical Technique

	Surgical technique			Total (n = 228)
	TLM (n = 61)	Electrocautery (n = 147)	combined approach (n = 19)	
Temporary tracheostomy (%)	2 (3.3)	23 (15.6)	9 (47.4)	34 (14.9)
Permanent tracheostomy (%)	2 (3.3)	5 (3.4)	2 (10.5)	9 (3.9)
Total (%)	4 (6.6)	28 (19.0)	11 (57.9)	43 (18.9)
Temporary gastrostomy (%)	6 (9.8)	49 (33.3)	18 (100)	73 (32.0)
Permanent gastrostomy (%)	2 (3.3)	5 (3.4)	1 (5.3)	8 (3.5)
Total (%)	8 (13.1)	54 (36.7)	19 (100)	81 (35.5)

TABLE VI. Survival of T2 OPC in the Recent Literature

Authors	Patients	DSS (%)	OS	Treatment
Röösl, 2009	152	77.5	63.1%	Surg. ± RT or CRT
Moncrieff, 2009	66	78		Surg. ± RT
Mäkitie, 2006	55	70		Surg. ± RT or CRT
Cosmidis, 2004	21	100		Surg. only

does not provide data to compare the efficacy and safety of primary surgery with primary CRT. Only a prospective study directly comparing the two approaches could give a definitive answer of the best treatment choice.

CONCLUSION

In conclusion, primary surgical treatment of T2 OPC proved to be an effective treatment modality with a low rate of complications and satisfactory functional results. Complete tumor excision is essential and an aggressive strategy for the neck is justified. Most patients need adjuvant RT but further investigations could identify those patients where it is unnecessary and keep it in reserve for locoregional failures or second primary tumors.

ACKNOWLEDGMENTS

The authors would like to thank Phillip Grundtner for his valuable assistance during the statistical analysis of the data.

REFERENCES

- National Comprehensive Cancer Network (2010) Clinical practice guidelines in oncology: Head and neck cancer V.1.2010. <http://www.nccn.org>.
- Parsons JT, Mendenhall WM, Stringer SP, et al.: Squamous cell carcinoma of the oropharynx: Surgery, radiation therapy, or both. *Cancer* 2002;94:2967–2980.
- Allal AS, Nicoucar K, Mach N, et al.: Quality of life in patients with oropharynx carcinomas: Assessment after accelerated radiotherapy with or without chemotherapy versus radical surgery and postoperative radiotherapy. *Head Neck* 2003;25:833–839; discussion 839–840.
- Mowry SE, Ho A, Lotempio MM, et al.: Quality of life in advanced oropharyngeal carcinoma after chemoradiation versus surgery and radiation. *Laryngoscope* 2006;116:1589–1593.
- Chen AY, Schrag N, Hao Y, et al.: Changes in treatment of advanced oropharyngeal cancer, 1985–2001. *Laryngoscope* 2007;117:16–21.
- Haigentz M Jr, Silver CE, Corry J, et al.: Current trends in initial management of oropharyngeal cancer: The declining use of open surgery. *Eur Arch Otorhinolaryngol* 2009;266:1845–1855.
- Kreeft AM, van der Molen L, Hilgers FJ, et al.: Speech and swallowing after surgical treatment of advanced oral and oropharyngeal carcinoma: A systematic review of the literature. *Eur Arch Otorhinolaryngol* 2009;266:1687–1698.
- Weinstein GS, Quon H, O'Malley BW Jr, et al.: Selective neck dissection and deintensified postoperative radiation and chemotherapy for oropharyngeal cancer: A subset analysis of the University of Pennsylvania transoral robotic surgery trial. *Laryngoscope* 120:1749–1755.
- Bozec A, Poissonnet G, Chamorey E, et al.: Quality of life after oral and oropharyngeal reconstruction with a radial forearm free flap: Prospective study. *J Otolaryngol Head Neck Surg* 2009;38:401–408.
- Lybak S, Liavaag PG, Monge OR, et al.: Surgery and postoperative radiotherapy a valid treatment for advanced oropharyngeal carcinoma. *Eur Arch Otorhinolaryngol* 2011;268:449–456.
- Cohan DM, Popat S, Kaplan SE, et al.: Oropharyngeal cancer: Current understanding and management. *Curr Opin Otolaryngol Head Neck Surg* 2009;17:88–94.
- Cosmidis A, Rame JP, Dassonville O, et al.: T1-T2 NO oropharyngeal cancers treated with surgery alone. A GETTEC study. *Eur Arch Otorhinolaryngol* 2004;261:276–281.
- Walvekar RR, Li RJ, Gooding WE, et al.: Role of surgery in limited (T1-2, N0-1) cancers of the oropharynx. *Laryngoscope* 2008;118:2129–2134.
- Moncrieff M, Sandilla J, Clark J, et al.: Outcomes of primary surgical treatment of T1 and T2 carcinomas of the oropharynx. *Laryngoscope* 2009;119:307–311.
- American Joint Committee on Cancer (AJCC): Cancer staging manual, 7th edition. New York, NY: Springer-Verlag; 2010.
- Röösl C, Tschudi DC, Studer G, et al.: Outcome of patients after treatment for a squamous cell carcinoma of the oropharynx. *Laryngoscope* 2009;119:534–540.
- Deng Z, Hasegawa M, Matayoshi S, et al.: Prevalence and clinical features of human papillomavirus in head and neck squamous cell carcinoma in Okinawa, southern Japan. *Eur Arch Otorhinolaryngol* 2011;268:1625–1631.
- Mäkitie AA, Pukkila M, Laranne J, et al.: Oropharyngeal carcinoma and its treatment in Finland between 1995–1999 : A nationwide study. *Eur Arch Otorhinolaryngol* 2006;263:139–143.
- Karatzanis AD, Psychogios G, Waldfahrer F, et al.: T1 and T2 hypopharyngeal cancer treatment with laser microsurgery. *J Surg Oncol* 2010;102:27–33.
- Ambrosch P, Kron M, Pradier O, et al.: Efficacy of selective neck dissection: A review of 503 cases of elective and therapeutic treatment of the neck in squamous cell carcinoma of the upper aerodigestive tract. *Otolaryngol Head Neck Surg* 2001;124:180–187.
- Moergel M, Jahn-Eimermacher A, Krummenauer F, et al.: Effectiveness of adjuvant radiotherapy in patients with oropharyngeal and floor of mouth squamous cell carcinoma and concomitant histological verification of singular ipsilateral cervical lymph node metastasis (pN1-state)—a prospective multicenter randomized controlled clinical trial using a comprehensive cohort design. *Trials* 2009;10:118.
- Denis F, Garaud P, Bardet E, et al.: Final results of the 94-01 French Head and Neck Oncology and Radiotherapy Group randomized trial comparing radiotherapy alone with concomitant radiochemotherapy in advanced-stage oropharynx carcinoma. *J Clin Oncol* 2004;22:69–76.
- Salama JK, Seiwert TY, Vokes EE: Chemoradiotherapy for locally advanced head and neck cancer. *J Clin Oncol* 2007;25:4118–4126.
- Pederson AW, Haraf DJ, Witt ME, et al.: Chemoradiotherapy for locoregionally advanced squamous cell carcinoma of the base of tongue. *Head Neck* 32:1519–1527.
- Karatzanis AD, Psychogios G, Waldfahrer F, et al.: Surgical management of T1 oropharyngeal carcinoma. *Head Neck* 2011; DOI: 10.1002/hed.21916
- Leonhardt FD, Quon H, Abrahao M, et al.: Transoral robotic surgery for oropharyngeal carcinoma and its impact on patient-reported quality of life and function. *Head Neck* 2011; DOI: 10.1002/hed.21688
- Olzowy B, Tsalemchuk Y, Schotten KJ, et al.: Frequency of bilateral cervical metastases in oropharyngeal squamous cell carcinoma: A retrospective analysis of 352 cases after bilateral neck dissection. *Head Neck* 33:239–243. DOI: 10.1002/hed.21436
- Mantsopoulos K, Psychogios G, Waldfahrer F, et al.: Surgical treatment of locally limited tonsillar cancer. *Surg Oncol* 2011; DOI: 10.1016/j.suronc.2011.10.003