

## Diagnosis and gland-preserving minimally invasive therapy for Wharton's duct stenoses

Michael Koch, Heinrich Iro, Julian Künzel, Georgios Psychogios, Alessandro Bozzato, Johannes Zenk

### Angaben zur Veröffentlichung / Publication details:

Koch, Michael, Heinrich Iro, Julian Künzel, Georgios Psychogios, Alessandro Bozzato, and Johannes Zenk. 2011. "Diagnosis and gland-preserving minimally invasive therapy for Wharton's duct stenoses." *The Laryngoscope* 122 (3): 552-58. <https://doi.org/10.1002/lary.22452>.

### Nutzungsbedingungen / Terms of use:

licgercopyright

Dieses Dokument wird unter folgenden Bedingungen zur Verfügung gestellt: / This document is made available under the following conditions:

**Deutsches Urheberrecht**

Weitere Informationen finden Sie unter: / For more information see:

<https://www.uni-augsburg.de/de/organisation/bibliothek/publizieren-zitieren-archivieren/publizieren>



# Diagnosis and Gland-Preserving Minimally Invasive Therapy for Wharton's Duct Stenoses

Michael Koch, MD; Heinrich Iro, MD; Julian Künzel, MD; Georgios Psychogios, MD;  
Alessandro Bozzato, MD; Johannes Zenk, MD

**Objectives/Hypothesis:** The management of stenoses of Wharton's duct has so far been little investigated or systematized. The development of minimally invasive treatment methods, including sialendoscopy, has made preservation of gland function possible.

**Study Design:** Retrospective study in a tertiary referral center.

**Methods:** A total of 153 stenoses of the submandibular duct were diagnosed and treated in 138 patients. Ultrasound and sialendoscopy were the first-choice diagnostic measures. A total of 62.7% of the stenoses were located in the distal, 11.1% in the middle segment, and 18.3% in the proximal to posthilar duct. Diffuse stenoses were observed in 7.8% of the cases. Sialendoscopy-assisted intraductal cortisone administration, interventional sialendoscopy, and transoral ductal surgery were the treatment options. The mean period between treatment and data collection was 52.5 months.

**Results:** Fibrotic stenoses were diagnosed in 88.3% and bilateral involvement in 8.6% of the cases. Distal stenoses were treated predominantly by ductal incision (79.2%). Stenoses of the midsubmandibular duct were treated conservatively in 29.4% or with sialendoscopy or ductal incision in 35.3% of cases each. Proximal up to posthilar stenoses could be dilated by interventional sialendoscopy in 82.2%. In 25% of all diffuse stenoses, glandular resection was carried out, representing 2.6% of all stenoses. Glandular function was preserved in 97.8% of cases.

**Conclusions:** Stenoses of the submandibular duct can be treated using minimally invasive procedures and with preservation of glandular function with a high success rate. Ductal incision procedures are the most important measure, but sialendoscopy becomes more important the more centrally the stenosis is located.

**Key Words:** Salivary obstruction, Wharton's duct, stenosis, sialendoscopy.

**Level of Evidence:** 2b.

## INTRODUCTION

Salivary duct stenoses represent a relatively rare pathologic condition. Twenty-five percent of all such stenoses are located in the submandibular duct (Wharton's duct).<sup>1,2</sup> At least 5% of all obstructions of the submandibular gland, and in unclear cases more than 50%, are caused by stenoses.<sup>1-7</sup>

Ultrasound, magnetic resonance (MR) sialography, and conventional sialography play an important role in the diagnosis and can contribute to more precise characterization of stenoses with regard to their location, number, and extent. An analysis of more than 1,300 sialographies with strictures of the efferent ducts, recognized by contrast filling defects or loss of contrast in the ductal system, showed that the submandibular gland was affected in 25% of all diagnoses. Ngu et al. have

described the numbers of stenoses diagnosed using sialography and their location in the ductal system.<sup>1,7</sup>

MR sialography is an alternative method of imaging stenoses that does not require the use of contrast media.<sup>8</sup> Ultrasound provides an overview of the entire ductal system. The stenosis is indirectly characterized by a hypoechoic dilation of the proximal ductal system. Approximate localization of the stenosis is possible (Fig. 1). The accuracy of the findings can be significantly improved after vitamin C administration.<sup>2,5,9</sup> Sialendoscopy allows the diagnosis to be established by providing direct visualization of the ductal system. Stenoses can be precisely assessed with regard to their location, number, and extent, the degree of the luminal stricture, and the tissue quality. In this respect, sialendoscopy appears to be superior to the other diagnostic methods (Fig. 2).<sup>2,3,5,10,11</sup>

The cause of benign stenoses is unclear in the majority of cases.<sup>1,5</sup> The management of these stenoses has so far been investigated in very few studies. Several gland-preserving treatment procedures have been described. These include limited ductal incision procedures,<sup>12-15</sup> as well as more extensive ductal incision procedures as described for stone extraction.<sup>16,17</sup> Developments in radiographically guided interventional balloon dilation<sup>7,18,19</sup> and interventional sialendoscopy<sup>2,3,5,7</sup> have made minimally invasive intraductal therapy possible.

From the Department of Otorhinolaryngology, Head and Neck Surgery, University of Erlangen-Nuremberg, Bavaria, Germany.

Send correspondence to Michael Koch, MD, PhD, Klinik für Hals-, Nasen- Ohren-Kranke, Kopf- und Hals-Chirurgie, Friedrich-Alexander-Universität Erlangen-Nürnberg, Waldstrasse 1, D-91054 Erlangen, Germany. E-mail: michael.koch@uk-erlangen.de

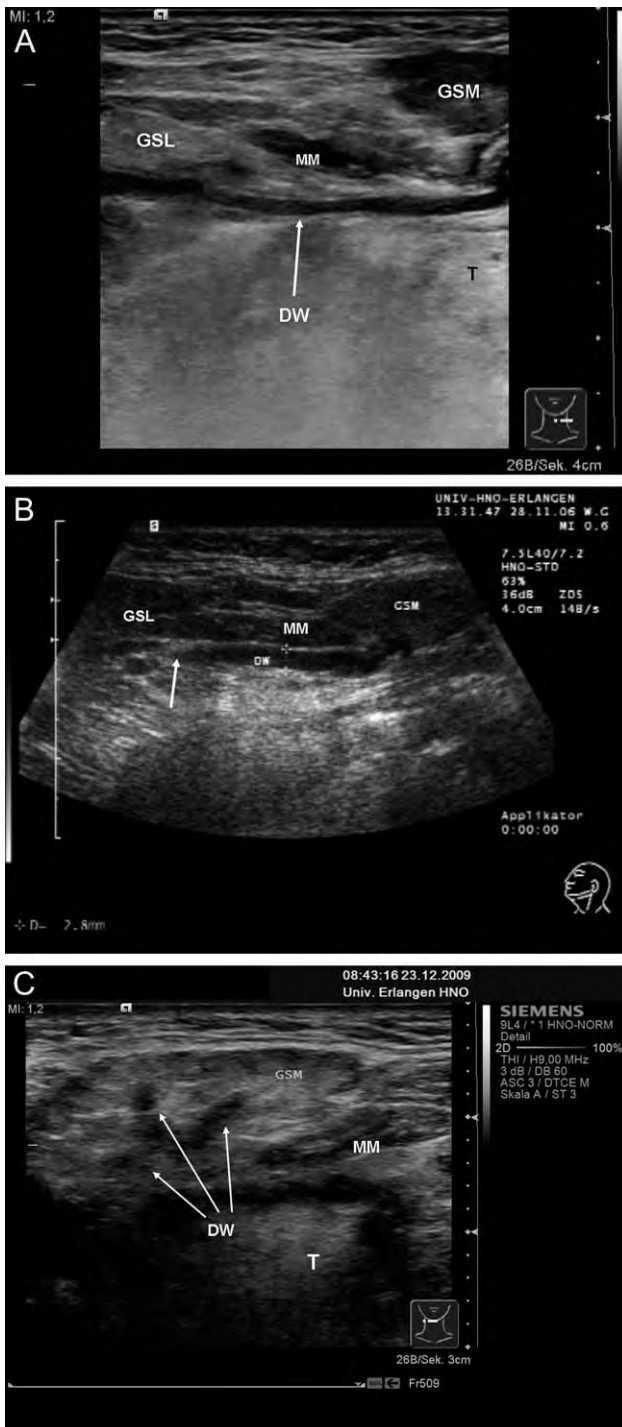


Fig. 1. Ultrasound findings in stenoses of the submandibular duct (Wharton's duct) in various locations. (A) Stenosis in the distal area of the duct; the whole length of the duct is congested (white arrow). (B) Stenosis in the middle third of the duct, showing the ductal system with proximal congestion and ductal discontinuity (white arrow). (C) A central posthilar stenosis. The ductal system is congested up to the intraparenchymal area (white arrows), and it is not visible distal to the hilar area. DW = Wharton's duct; GSL = sublingual gland; GSM = submandibular gland; MM = mylohyoid muscle; T = tongue.

There have been no previous publications dealing systematically with the diagnosis and treatment of this type of stenosis. A treatment algorithm including all

gland-preserving treatment modalities has been published by our own research group.<sup>20</sup> In the present study, a retrospective analysis of Wharton's duct stenoses was carried out to establish the relative importance of the different methods. The use of the various treatment methods was investigated relative to the location of the stenoses, and the results of the treatments were evaluated. The study was approved by the review board of the Friedrich-Alexander University of Erlangen-Nuremberg.

## MATERIALS AND METHODS

A total of 138 patients (male 43.5%, female 56.5%; mean age, 48.9 years) with a total of 153 stenoses of the submandibular duct were diagnosed and treated at the Department of Otorhinolaryngology, Head and Neck Surgery at Erlangen University Hospital from 2001 to 2010. The patients presented with recurrent painful swelling of the submandibular gland after or during eating, which had led to a marked impairment of their quality of life.

All of the patients were initially examined using high-resolution ultrasonography (Sonoline Elegra or Acuson S 2000, 5–10 MHz; Siemens Medical Solutions, Inc., Malvern, PA). Sialendoscopy was carried out after the suspected diagnosis had been established on the basis of the clinical and ultrasound examinations. Various semirigid sialendoscopes were used (type 11572, 0.8 mm; type 11574, 1.1 mm; type 11576, 1.6 mm; Karl Storz Ltd., Tuttlingen, Germany).<sup>2,21</sup> In addition to direct visualization, pretherapeutic assessment of the location, length, number, and degree of the stenoses and of the tissue quality in the area of the stenoses was also possible. Highly reliable estimation of the degree of stenosis was possible using the various external diameters of the endoscopes (0.8–1.6 mm), and the precise position and length of the stenosis was reliably estimated using the centimeter scale on the endoscope shaft.<sup>10</sup>

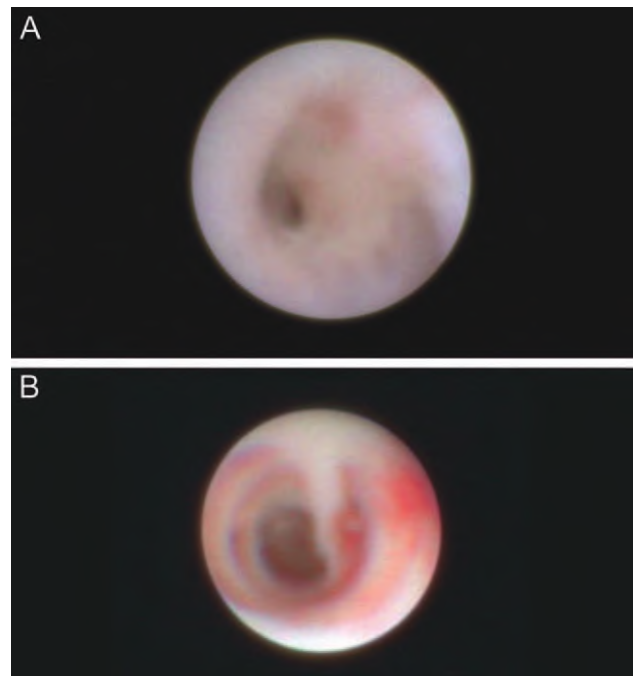


Fig. 2. (A) Hilar/posthilar fibrous stenosis after duct division at an inferior orifice. (B) Inflammatory segmental swelling of the duct in a patient with an inflammatory stenosis of the distal area of the duct, with a predominant inflammatory reaction.

## Diagnosis and Characterization of Stenoses

The stenoses were evaluated with regard to the clinical and sialendoscopic tissue differences that are also seen in stenoses of the parotid gland.<sup>10</sup> It was possible to distinguish between stenotic areas with a severe inflammatory reaction and with only slight fibrotic changes on the one hand and stenoses with mainly fibrotic tissue on the other (Fig. 2).

The location of the stenoses was identified using ultrasound and sialendoscopy. Approximate localization was possible with ultrasound (Fig. 1), and precise localization was achieved using the recognizable anatomic landmarks and with the centimeter marks on the instrument during sialendoscopy.<sup>10</sup> The main duct was divided into three segments: segment 1: stenoses in the papillary region and in the distal ductal system (papilla up to 2 cm proximally); segment 2: stenoses in the middle third of the ductal system (2–5 cm proximally); and segment 3: stenoses in the proximal ductal system/hilar region/posthilar (from approximately 0.5 to 1.0 cm in front of the hilum to posthilar; various depths, depending on the ductal division pattern).

In addition, diffuse stenoses (length >3 cm and/or involving several segments including the main duct and hilar region or the entire ductal system) were identified. Distinctions were also made relative to the number of stenoses, between single and multiple stenoses ( $n \geq 2$ ), and, relative to their length, between stenoses of limited length (length  $\leq 3$  cm, including membranous stenoses, pinhole stenoses) and diffuse stenoses (>3 cm, see previous description).

For assessing luminal strictures, the published anatomic data on the diameter of the parotid duct (average, 1.5 mm) were used as reference data.<sup>22</sup> The diameter of the sialendoscope shaft being used (0.8, 1.1, or 1.6 mm) allowed precise assessment of the residual lumen. Stenoses were described as minor if they could still be passed with the 1.1-mm sialendoscope, moderate if they could still be passed with the 0.8-mm scope, and high grade (filiform or complete) if they were only passable after additional instrumental dilation.<sup>11</sup>

## Treatment Strategy

The suspected diagnosis established by the ultrasound examination was confirmed on sialendoscopy. If it was not possible to introduce the sialendoscope into the ductal system because of a papillary stenosis, a papillotomy was carried out initially. The stenosis was analyzed using diagnostic sialendoscopy.

Rinsing of the ductal system with cortisone was carried out in all patients during initial and checkup sialendoscopies (conservative sialendoscopy-assisted basic therapy). If the stenosis was less severe (as was often the case in patients with inflammatory stenoses), efforts were made to reduce the symptoms without further surgical measures.

In patients with severe filiform to complete stenoses (often fibrotic), surgical measures were usually indicated. These included interventional sialendoscopy and transoral ductal surgery procedures such as papillotomy and distal or extended ductal incision. The location of the stenosis was decisive for the choice of treatment procedure (Fig. 3).

Based on experience with ductal incision as a safe surgical procedure, this was the preferred method, particularly in cases of complete fibrous stenosis in the distal ductal system up to the start of the hilar area. The reasons for this are the good accessibility of the duct and the option of proximal marsupialization, combined with minimizing the risk of recurrence. In patients with minor to moderate stenoses, endoscopically controlled dilation was the preferred option.

In the proximal ductal system up to the posthilar ductal area, the conditions for carrying out ductal incision are less favorable. It is much more technically difficult in fibrotic tissue conditions, particularly in relation to exposing the ductal system and carrying out

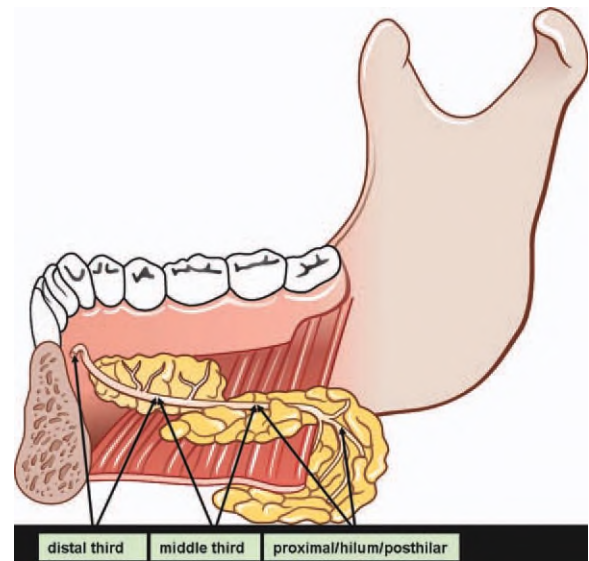


Fig. 3. Division of Wharton's duct in into three segments (length of segment 1 approximately 2 cm, segment 2 approximately 3 cm and segment 3 approximately 2–2.5 cm) as an anatomic base and orientation for treatment planning. Predictable excellent approach to the duct system by means of ductal incision and the possibility of marsupialization of the duct system is given in segment 1 and 2. [Color figure can be viewed in the online issue, which is available at [wileyonlinelibrary.com](http://wileyonlinelibrary.com).]

the necessary marsupialization. The ductal system is very well visualized with the sialendoscope in this location. Stenoses here were usually only dilated with endoscopic guidance. The technique to open filiform or complete stenoses in smaller duct lumens was based mainly on the use of the basket and microdrill (Fig. 4).<sup>2,5,10,20</sup> In all stenoses that were opened endoscopically (with an intact non-patent ductal system), postinterventional intraductal cortisone instillation was carried out, with administration of 50 mg of prednisolone into the ductal system via an indwelling venous cannula in each case (current regimen: once weekly for 8 weeks, once every 2 weeks for 4 weeks, and once after an additional 4 weeks).

## RESULTS

All of the procedures were carried out with local anesthesia, which was administered intraductally and/or as conduction block anesthesia via the lingual nerve (2–5 mL Ultracaine 2% with epinephrine). Using ultrasound and sialendoscopy, a total of 153 stenoses were diagnosed and subsequently treated in the 138 patients.

## Diagnosis

Ultrasound typically showed a bandlike hypoechoic zone as a typical sign of ductal dilation (Fig. 1). On sialendoscopy, fibrous stenoses (Fig. 2A) were present in 88.3% of cases and inflammatory stenoses (Fig. 2B) in 11.7% of cases. Of the stenoses, 62.7% were at the papilla or in the distal duct; 11.1% were in the middle segment of the duct; 18.3% were in the proximal segment of the duct including the hilar or posthilar area, and 7.8% showed diffuse and/or multiple stenoses of the ductal system. The stenoses were of limited length ( $\leq 3$  cm) in 93.2% of cases. One-third of the stenoses in the middle part of the ductal area and 25% of the diffuse stenoses were inflammatory (Fig. 5). Two stenoses each were diagnosed in the same ductal system in 2.1%

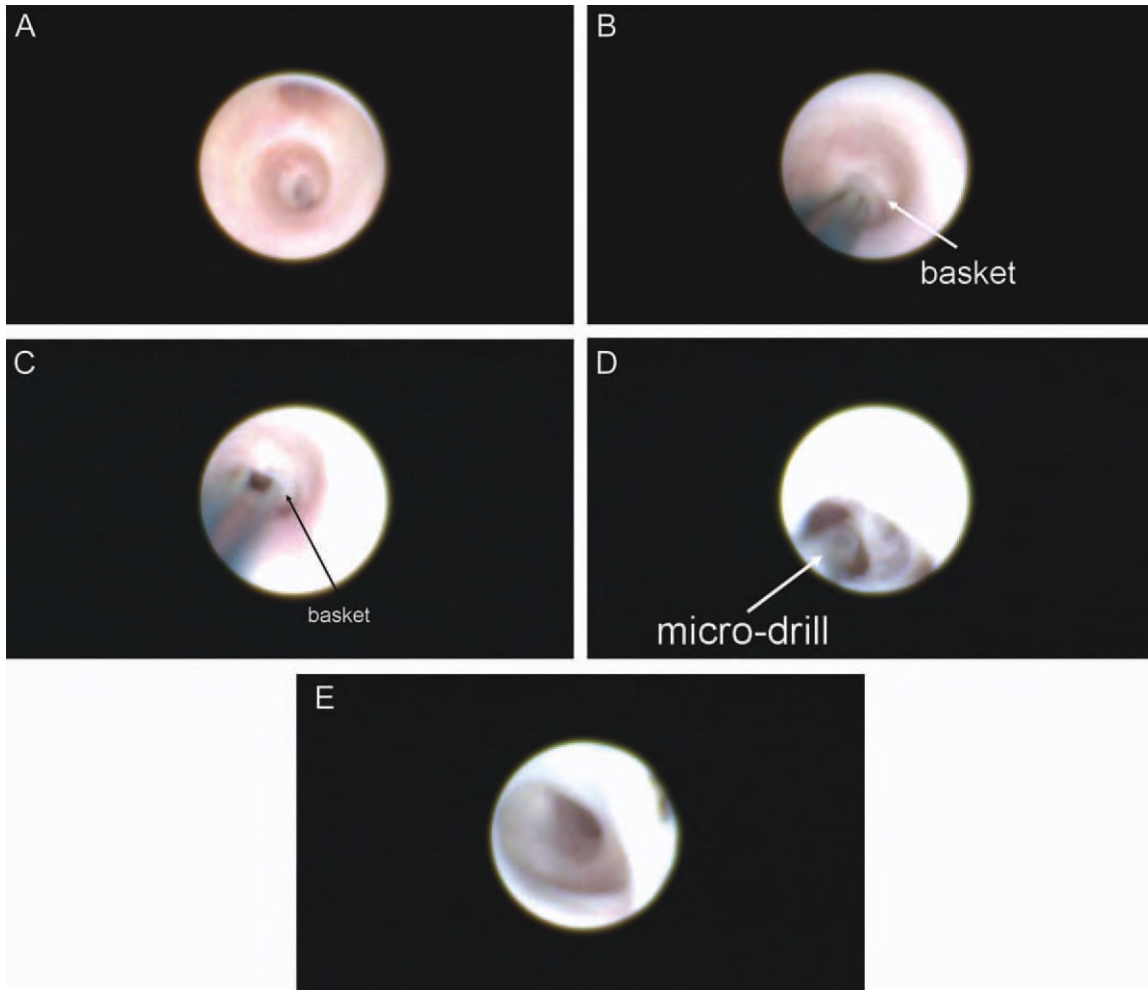


Fig. 4. Interventional sialendoscopy in posthilar stenosis. (A) Filiform fibrous stenosis in the posthilar duct system. (B) Probing of the stenosis using the basket. (C) The fibrous tissue is dilated step by step by using the basket, which is flexible and atraumatic at the tip. (D) Transsection of scar tissue to further enlarging and smoothing of the ductal lumen with the microdrill. (E) Stenosis after opening and dilation, with a view of the proximal intraparenchymal ductal system.

of the patients (3 of 138), and bilateral stenoses were diagnosed in 8.6% of the patients (12 of 138). A total of two stenoses in one or both glands were found in 4.3% of the patients (6 of 138), and three stenoses in both glands were found in 0.7% (1 of 138). Simultaneous sialolithiasis was present in 2.1% (3 of 138).

Anatomic variations involving ductal kinking or bending were also present in 5.1% (7 of 138), and webs were present in 1.4% (2 of 138); accessory ducts were observed in 0.7% (1 of 138).

**Association with Possible Causative Conditions**

The stenoses were associated with previous therapy and/or existing diseases that represented possible causes in 51.4% of the patients (71 of 138).<sup>1,3</sup> The most frequent conditions involved were surgical manipulation of the ductal system (13.8%) and allergy (26.8%). Surgical manipulations preceded distal stenoses in 17.7% of cases (17 of 96; one sialendoscopy, two papillotomies, 12 ductal incisions, one ranula operation, and one operation for a tumor in the floor of the mouth; for further data, see Table I).

**Treatment**

Location and extent of stenoses were decisive for the choice of treatment procedure (Fig. 3).

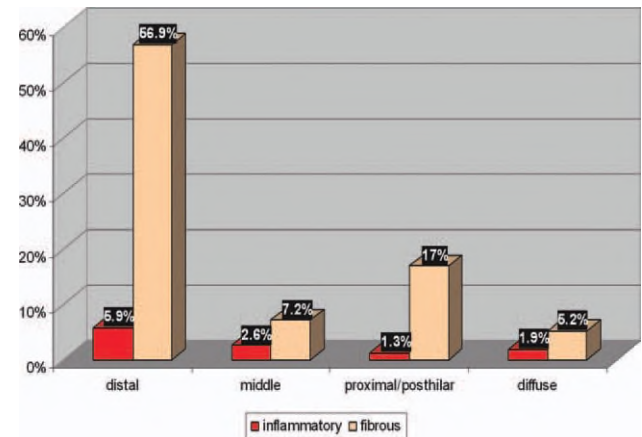


Fig. 5. Tissue quality relative to the location of the stenosis in stenoses of the submandibular duct (Wharton's duct).

TABLE I.

Stenoses of Wharton's Duct in Association With Previous Treatment and Associated Diseases in 138 Patients.

Causes	No.	%
Previous surgery or treatment*	19	13.8
Stone <sup>†</sup>	7	5.1
Allergy <sup>‡</sup>	37	26.8
Autoimmune disease	7	5.1
Status postradioiodine treatment <sup>‡</sup>	5	3.6
Status postradiotherapy	2	1.4
Dental prosthesis	2	1.4
Amyloidosis	1	0.7
Total	71	51.4

Nine patients had multiple involvements.

\*Previous surgery or treatment plus another disease simultaneously, n = 5 (3.6%).

<sup>†</sup>Stone plus stenosis and allergy simultaneously, n = 3 (2.2%).

<sup>‡</sup>Allergy plus radioiodine treatment, n = 1 (0.7%).

**Stenoses of the papilla and distal ductal system (segment 1: 62.7% of all stenoses, n = 96; number of patients n = 89).** Conservative sialendoscopy-assisted basic treatment was sufficient in 9.3% of cases (9 of 96). Endoscopic dilation of the stenosis was possible in 11.5% of cases (11 of 96). The most important procedures, however, were papillotomy and distal ductal incision in 79.2% of all stenoses (76 of 96). Two of these patients had combined stenoses in segments 1 and 3 (simultaneous ductal incision and interventional sialendoscopy, see later description). In seven patients, bilateral distal duct incision was performed. Distal duct surgery was combined with treatment of a hilar stenosis (conservative, 1 patient) and treatment of a stenosis in the middle third of the duct system (duct incision, 1 patient) on the other side. Glandular resection was not necessary in any of the cases.

**Stenoses of the middle third of the ductal system (segment 2: 11.1% of all stenoses, n = 17; number of patients = 17).** Conservative sialendoscopy-assisted basic therapy was sufficient in 29.4% of cases (5 of 17). Dilation of the stenoses was achieved with endoscopy or ductal incision in 35.3% of cases each (6 of 17). One patient had a combined stenosis in segments 2 and 3; simultaneous ductal incision and interventional sialendoscopy were carried out. Bilateral treatment included treatment of a distal duct incision (1 patient) and treatment of a diffuse stenosis (extended duct incision, 1 patient) of the other side. All of the methods were more or less equivalent in this location. Again, glandular resection was not necessary in any cases here.

**Stenoses of the proximal ductal system (segment 3: 18.3% of all stenoses, n = 28; number of patients = 24).** Conservative sialendoscopy-assisted basic therapy was sufficient in 17.8% of cases (5 of 28). Two of these patients declined to undergo the interventional sialendoscopy that would have been indicated. In the remaining 82.2% (23 of 28), all the stenoses were dilated endoscopically (Figs. 2A and 4). Neither ductal incision nor glandular resection was carried out in any

of the cases. There were combined stenoses in two of these patients in segments 1 and 3 and in one patient in segments 2 and 3. Simultaneous ductal incision and interventional sialendoscopy were carried out in each case. Bilateral treatment of a hilar stenosis was performed in one case, and in another case interventional sialendoscopy was combined with distal duct incision on the other side because of a distal duct stenosis.

**Diffuse stenoses of the proximal ductal system (>1 segment, length  $\geq 3$  cm: 8.7% of all stenoses, n = 12; number of patients = 11).** Ductal incision was the most important procedure here; 58.3% (7 of 12) of these stenoses were successfully treated in this way. Interventional sialendoscopy (following unsuccessful conservative sialendoscopy-assisted basic therapy) was successful in 8.3% of cases (1 of 12). Removal of the (residual) gland had to be carried out in 25% (4 of 12). All of the glandular resections carried out (two unilateral, one bilateral, and one of residual glandular tissue) were thus in the group of patients who had diffuse stenoses. Attempts to carry out interventional sialendoscopy were not successful in any of these cases, and conservative sialendoscopy-assisted basic therapy was not indicated or successful (1 case treated by interventional sialendoscopy) in any of the cases.

### Treatment Summary and Course

The period between treatment and data collection averaged 52.5 months (range, 3–117 months). Conservative sialendoscopy-assisted basic therapy was also successful in 95% of all attempted treatments (19 of 20); in one case, additional interventional sialendoscopy was necessary. Attempts to relieve the stenosis using interventional sialendoscopy were successful in 93.2% of the patients (41 of 44). A total of 49 sialendoscopies were carried out, 46 of which were successful (93.9%). One sialendoscopy was sufficient in 40 cases, two were needed in three cases (hilar stenoses in each), and three sialendoscopies were required in one case (hilar stenosis). The more central the location of the stenosis, the more frequently was sialendoscopy indicated. Cortisone was instilled into the ductal system once a week after every sialendoscopy (see previous description). Attempts to treat the stenosis using ductal incision were successful in all cases. Ductal incision proved to be the most important treatment procedure (58.1% of all stenoses).

The rate of glandular resection was 2.1% (Table II); the gland was preserved in 97.9% of the patients (135 of 138). At the time of data collection, 2.2% of these patients (3 of 135) reported symptoms typical of obstructive salivary gland disease. Further treatment was not desired at that time by any of the three patients.

### DISCUSSION

Obstructive diseases of the submandibular gland lead to recurrent painful postprandial swelling in affected patients. Stenoses of Wharton's duct are the second most frequent cause of glandular obstruction but are much rarer than parotid gland stenoses. Very few

TABLE II.  
Success Rates of the Various Methods of Treating Stenoses of Wharton's Duct (n = 153).

Stenosis Location	Conservative		Interventional Sialendoscopy		Transoral Ductal Incision		Glandular Resection		Total	
	No.	%	No.	%	No.	%	No.	%	Σ	%
Distal	9	9.3	11	11.5	76	79.2	—	—	96	62.7
Middle	5	29.4	6	35.3	6	35.3	—	—	17	11.1
Proximal/hilum/posthilar	5	17.8	23	82.2	—	—	—	—	28	18.3
Diffuse	—	—	1	7.7	7	61.5	4	25	12	7.8
Total	19	12.4	41	26.8	89	58.1	4	2.1	153	100.0

published reports have comprehensively discussed the diagnosis and treatment of this type of pathology.<sup>1,2,20</sup>

Ultrasound, MR sialography, conventional sialography, and sialendoscopy currently represent the most important diagnostic procedures. All of these procedures can contribute to more accurate characterization of the stenoses.<sup>1,5</sup>

Ngu et al. analyzed 49 sialographies with regard to the number and location of Wharton's duct stenoses. They distinguished between strictures in the anterior third (18.1%), middle third (12.1%), and posterior third including the hilar region (69.7%). The distribution of stenotic locations observed in the patients included in the present study was opposite to this finding, with 62.7% of the stenoses located in the distal third of the duct and 18.1% in the proximal third. This may possibly be because of the association with previous operations in the present patients, as 16 of the 19 patients (16 of 138, 11.6%) had also undergone previous procedures in the area of the distal ductal system (Table I).

Multiple stenoses were observed more frequently in the study by Ngu et al. (48.5% vs. 5.1%), but no bilateral stenoses were encountered, in comparison with a rate of 8.6% in our patients.<sup>1</sup>

In the present study, 12.4% of the stenoses, particularly incomplete and/or inflammatory stenoses with a limited length, were easily managed with conservative treatment measures (Table II). Fibrous stenoses were present in 88.3% of cases, almost all of which were high grade and required surgical intervention (previous surgical procedures in the ductal system were present in nearly 20% of the patients with distally located stenoses; Table I). In contrast to sialolithiasis, which is the main cause of obstruction of the submandibular gland, stenoses were diagnosed much more rarely. Comparison with the parotid gland shows that stenoses were diagnosed more frequently there, particularly during the course of chronic recurrent parotitis.<sup>1,5,10</sup> Chronic recurrent inflammation of the submandibular gland is as yet poorly defined as a clinical picture. However, evidence of such inflammation may be provided by the fact that in addition to iatrogenic causes, there are also specific diseases that are associated with the occurrence of these stenoses (Table I).

Because of the accessibility of the ductal system in the floor of the mouth, the location and extent of stenosis play a very important role in the choice of treatment

modality. In all, 58.1% of the stenoses were successfully treated with transoral surgical procedures (Table II). In the present group of patients, these were the most important treatment methods used, particularly in patients with distal stenoses (nearly 80%) but also in those with long, diffuse stenoses if the hilar region was not affected (>60%). However, the importance of ductal incision declined toward the central area of the duct system. Although 35% of the stenoses were still treated with ductal incision in the middle segment of the duct, this was not possible in any cases with hilar or posthilar stenosis. The reason for this is the good accessibility of the ductal system for surgical manipulation in the area of the floor of the mouth. In addition to safe opening of the ductal lumen by an incision into the duct, marsupialization of the duct and creating a neo-ostium is an important prerequisite for successful treatment. This should be carried out in nonfibrotic ducts proximal to the stenosis to ensure a sufficiently wide neo-ostium; otherwise there is a risk of recurrent stenosis. Transoral ductal surgery procedures have been described in the treatment for submandibular gland stenoses. However, these procedures were used only to a limited extent for the purposes of "bypass surgery" or for incisions in the distal two-thirds of the ductal system.<sup>12-15</sup> More extensive procedures involving incision in the proximal ductal system as well, including the hilum, or extending to submandibulotomy, as has been described in the treatment of sialolithiasis,<sup>16,17</sup> have not as yet been reported in connection with the treatment of submandibular gland stenoses. The prerequisite for ductal incision is that the stenoses must be located in front of or within the hilar region and that marsupialization of the duct with the creation of a neo-ostium must be possible. For proximal and hilar stenoses, we have found ductal incision is an appropriate procedure only in individual cases; however, such stenoses can be effectively treated using interventional sialendoscopy. Particularly in the hilar and posthilar area, sialendoscopy provides a unique direct view of a segment of the ductal system that cannot be visualized with other methods (Fig. 2A). The importance of sialendoscopy increases from the distal to the proximal/hilar/posthilar duct system. Although distal stenoses were treated with this method in only 11.5% of cases and stenoses of the middle third of the ductal system in as many as 35.3% of cases, sialendoscopy-guided instrumental dilation of stenoses in the proximal to posthilar

area of the duct was the most important treatment procedure, representing 82.2% of cases (Fig. 4) (Table II). Ninety-three percent of patients who underwent endoscopic treatment also became free of symptoms, confirming the published data with rates of 80% to 90%.<sup>2,3</sup>

The injection of cortisone into the ductal system has proved to be a valuable form of treatment in patients with inflammatory changes in the ductal system, particularly in the treatment of stenoses.<sup>2,3,20</sup> In the present group of patients, 12.4% became free of symptoms after sialendoscopy alone and rinsing of the ductal system with NaCl/cortisone (conservative endoscopy-assisted basic therapy) and postinterventional intraductal cortisone injection alone.

Diffuse stenoses can be treated using ductal incision in more than 60% of cases. When the hilum and/or posthilar area was involved, it was not always possible to avoid glandular resection (25% of our cases). Sialendoscopy-based treatment procedures do not appear to be a suitable indication in patients with long, diffuse stenoses.

Overall, sialendoscopy-based techniques played a decisive role in the treatment of 39.2% of the patients.

Sialography-controlled balloon dilation represents an alternative minimally invasive treatment, which has been used with success rates of 70% to 80%.<sup>7,18,19</sup> However, this procedure has the disadvantage that it only allows indirect visualization of the stenosis, involves radiation exposure, and is associated with a risk of reaction to contrast media. In view of the opportunities provided by sialendoscopy, it does not currently represent the treatment of choice.

The various methods of treating these stenoses have been included in a published treatment algorithm.<sup>20</sup>

## CONCLUSION

Ultrasound and sialendoscopy play an extremely important role in stenoses of Wharton's duct. They allow rapid, low-cost diagnosis with simultaneous planning and implementation of treatment. In the treatment, the location of the stenoses appears to be decisively important. Thanks to the good accessibility of the area, transoral ductal surgery is the most important method, especially in stenoses located in the distal third. The more central the location of the stenosis, however, the more important interventional sialendoscopy becomes, and it proved to be the most important therapeutic tool in stenoses located in the proximal and posthilar duct system. In sialendoscopy-based treatment strategies with an intact, unincised ductal system, intraductal cortisone instillation

appears to have a positive effect on inflammatory and fibrotic processes. Overall this combined treatment was associated with a high level of patient acceptance, a low number of patients still having symptoms following gland-preserving treatment, and a low rate of glandular resection after all other treatment options had been exhausted.

## BIBLIOGRAPHY

1. Ngu RK, Brown JE, Whaites EJ, Drage NA, Ng SY, Makdissi J. Salivary duct strictures: nature and incidence in benign salivary obstruction. *Dentomaxillofac Radiol* 2007;36:63–67.
2. Koch M, Zenk J, Iro H. Diagnostic and interventional sialoscopy in obstructive diseases of the salivary glands. *HNO* 2008;56:139–144.
3. Nahlieli O, Shacham R, Yoffe B, Eliav E. Diagnosis and treatment of strictures and kinks in salivary gland ducts. *J Oral Maxillofac Surg* 2001;59:484–490; discussion, 490–492.
4. Marchal F, Dulguerov P, Becker M, Barki G, Disant F, Lehmann W. Submandibular diagnostic and interventional sialendoscopy: new procedure for ductal disorders. *Ann Otol Rhinol Laryngol* 2002;111:27–35.
5. Koch M, Zenk J, Bozzato A, Bumm K, Iro H. Sialoscopy in cases of unclear swelling of the major salivary glands. *Otolaryngol Head Neck Surg* 2005;133:863–868.
6. Yu C, Yang C, Zheng L, Wu D. Endoscopic observation and strategic management of obstructive submandibular sialadenitis. *J Oral Maxillofac Surg* 2010;68:1770–1775.
7. Koch M, Zenk J, Iro H. Algorithms for treatment of salivary gland obstructions. *Otolaryngol Clin North Am* 2009;42:1173–1192, Table of Contents.
8. Brown JE. Interventional sialography and minimally invasive techniques in benign salivary gland obstruction. *Semin Ultrasound CT MR* 2006;27:465–475.
9. Gadodia A, Seith A, Sharma R, Thakar A, Parshad R. Magnetic resonance sialography using CISS and HASTE sequences in inflammatory salivary gland diseases: comparison with digital sialography. *Acta Radiol* 2010;51:156–163.
10. Bozzato A, Hertel V, Bumm K, Iro H, Zenk J. Salivary simulation with ascorbic acid enhances sonographic diagnosis of obstructive sialadenitis. *J Clin Ultrasound* 2009;37:329–332.
11. Koch M, Iro H, Zenk J. Sialendoscopy-based diagnosis and classification of parotid duct stenoses. *Laryngoscope* 2009;119:1696–1703.
12. Yuasa K, Nakhyama E, Ban S, et al. Submandibular gland duct endoscopy. Diagnostic value for salivary duct disorders in comparison to conventional radiography, sialography, and ultrasonography. *Oral Surg Oral Med Oral Pathol Oral Radiol Endod* 1997;84:578–581.
13. Karas ND. Surgery of the salivary ducts. *Atlas Oral Maxillofac Surg Clin North Am* 1998;6:99–116.
14. Labrunie G, Lair J, Touzet C. Bypass whartonostomy (author's transl) [in French]. *Rev Stomatol Chir Maxillofac* 1981;82:70–75.
15. Mandel L, Kaynar A. Surgical bypass of submandibular duct stricture. *Oral Surg Oral Med Oral Pathol Oral Radiol Endod* 1999;88:532–533.
16. Rontal M, Rontal E. The use of sialodochoplasty in the treatment of benign inflammatory obstructive submandibular gland disease. *Laryngoscope* 1987;97:1417–1421.
17. Zenk J, Constantinidis J, Al-Kadah B, Iro H. Transoral removal of submandibular stones. *Arch Otolaryngol Head Neck Surg* 2001;127:432–436.
18. McGurk M. Surgical release of a stone from the hilum of the submandibular gland: a technique note. *Int J Oral Maxillofac Surg* 2005;34:208–210.
19. Salerno S, Lo Casto A, Comparetto A, et al. Sialodochoplasty in the treatment of salivary-duct stricture in chronic sialoadenitis: technique and results. *Radiol Med* 2007;112:138–144.
20. McGurk M, Escudier MP, Thomas BL, Brown JE. A revolution in the management of obstructive salivary gland disease. *Dent Update* 2006;33:28–30,33–36.
21. Zenk J, Koch M, Bozzato A, Iro H. Sialoscopy—initial experiences with a new endoscope. *Br J Oral Maxillofac Surg* 2004;42:293–298.
22. Zenk J, Hosemann WG, Iro H. Diameters of the main excretory ducts of the adult human submandibular and parotid gland: a histologic study. *Oral Surg Oral Med Oral Pathol Oral Radiol Endod* 1998;85:576–580.