

Salivary simulation with ascorbic acid enhances sonographic diagnosis of obstructive sialadenitis

Alessandro Bozzato, Victoria Hertel, Klaus Bumm, Heinrich Iro, Johannes Zenk

Angaben zur Veröffentlichung / Publication details:

Bozzato, Alessandro, Victoria Hertel, Klaus Bumm, Heinrich Iro, and Johannes Zenk. 2009. "Salivary simulation with ascorbic acid enhances sonographic diagnosis of obstructive sialadenitis." *Journal of Clinical Ultrasound* 37 (6): 329-32. <https://doi.org/10.1002/jcu.20595>.

Nutzungsbedingungen / Terms of use:

licgercopyright

Dieses Dokument wird unter folgenden Bedingungen zur Verfügung gestellt: / This document is made available under the following conditions:

Deutsches Urheberrecht

Weitere Informationen finden Sie unter: / For more information see:

<https://www.uni-augsburg.de/de/organisation/bibliothek/publizieren-zitieren-archivieren/publizieren>



Salivary Simulation with Ascorbic Acid Enhances Sonographic Diagnosis of Obstructive Sialadenitis

Alessandro Bozzato, MD, Victoria Hertel, MD, Klaus Bumm, MD, Heinrich Iro, MD, Johannes Zenk, MD

Department of Otorhinolaryngology, Head & Neck Surgery, University of Erlangen-Nuremberg; FAU Medical School, Waldstrasse 1, D-91054 Erlangen, Germany

ABSTRACT: *Purpose.* High-frequency ultrasound (US) is routinely used to evaluate various diseases of the salivary glands. Normally, the duct network of the submandibular and parotid glands is not visible during US assessment. In obstructive sialadenitis of the parotid and submandibular glands, localization of the obstacle is often difficult.

Methods. In a case-control study, the sonographic visibility of the duct before and after stimulation with oral ascorbic acid (vitamin C) was compared with sialendoscopy as the gold standard. Twenty male and 23 female patients suffering from salivary gland diseases were included in this study and compared with 25 healthy volunteers. US examination of the parotid and submandibular glands was performed before and after oral ascorbic acid stimulation. Changes in visibility of the main excretory duct were recorded and US diagnoses were compared with results of sialendoscopy.

Results. In 7 of 25 controls, the main duct became partially visible after stimulation. In the group of 43 patients, the main duct was depicted before stimulation in 27 patients (63%). After ascorbic acid stimulation, the main duct became visible in 41 patients (95%). Grading the stimulated duct dilation by measuring diameters at different points revealed no correlation with the underlying type of pathology.

Conclusions. Application of ascorbic acid prior to diagnostic US examination facilitates the sonographic evaluation of obstructive salivary gland diseases. © 2009 Wiley Periodicals, Inc. *J Clin Ultrasound* 37:329–332, 2009; Published online in Wiley InterScience (www.interscience.wiley.com). DOI: 10.1002/jcu.20595

Keywords: salivary gland; ultrasonography; sialolithiasis; sialendoscopy; ascorbic acid; parotid; submandibular gland

High-frequency ultrasound (US) examination is presently the method of choice for salivary gland imaging.^{1,2} Magnetic resonance imaging, magnetic resonance sialography, and conventional sialography can visualize the ductal system but are time consuming and expensive and thus less suitable for daily routine usage. In normal subjects, the draining ductal network cannot be identified on US. If the draining duct system is blocked due to sialolithiasis or ductal stenosis, the distended proximal ductal network becomes visible, with the dilated duct appearing as a tubular anechoic structure. Intraductal material often appears as hyperechoic foci casting distal acoustic shadow.³

Despite the typical symptoms, as many as 10% of all patients with recurrent preprandial swelling of the major salivary glands do not show sialolithiasis or other signs of obstructive alteration during initial US examination or clinical investigation.^{4,5} Improved US imaging of the ductal system is desirable in the light of various treatment options that range from minimally invasive measures to open surgical interventions, depending on the accurate diagnosis.

In magnetic resonance sialography, citric acid is routinely used to stimulate saliva production and enable visualization of the draining ductal system of parotid and submandibular glands.^{6–8} The aim of this prospective study was to evaluate the clinical impact of saliva stimulation with ascorbic acid in the US assessment of salivary gland obstruction.

PATIENTS AND METHODS

A total of 43 patients suffering from recurrent preprandial swelling of the submandibular or

parotid gland were included in this study. The study received approval from our IRB, and all participants gave informed consent prior to the examinations. A total of 25 age-matched healthy volunteers with no history of parotid or submandibular gland disease formed the control group.

The US examination included a thorough scan of the bilateral parotid and submandibular glands using an Acuson Antares scanner (Siemens Medical Solutions, Malvern, IA) with a VF10–5 multifrequency transducer.

Both parotid and submandibular glands were scanned in transverse and longitudinal planes. Special attention was paid to identifying any distension of the main excretory duct as a sign of obstruction. A hyperechoic focus with distinct acoustic shadowing within the ductal network was diagnosed as salivary gland calculus (Figure 1). If calculus was present, its location was documented as intraglandular, extraglandular, or intraductal. A distended duct without evidence of calculus was considered due to a stenosis, and its position within the ductal network recorded. Any distended duct was measured at the point of maximal dilatation.

Then, 200 milligrams of ascorbic acid powder was applied sublingually, and the patient was instructed to spread the powder in the oral cavity. Twenty seconds later, a repeat US investigation was started and lasted for about 120 seconds. In the control group, 12 parotid and 13 submandibular glands were randomly reexamined after ascorbic acid application. In the 43 patients, the ductal network of the affected gland was reexamined and findings documented on digital printouts and short video clips (15 seconds). Two examiners rated the visibility of the salivary ducts as visible or not visible, the type and location of any observed disease, and whether the stimulation improved the diagnostic quality of the images. In all patients with symptomatic obstructive disorders (periprandial swelling of the salivary gland), a sialendoscopy was performed following the US investigation to reach a definitive diagnosis. The US diagnosis was verified by office-based sialendoscopy if a stone or stenosis was seen on US.

RESULTS

In none of the 25 controls was any duct visible in the parotid and submaxillary gland prior to ascorbic acid application in seven subjects (28%), the main duct of the submandibular or parotid gland became partially visible after stimulation

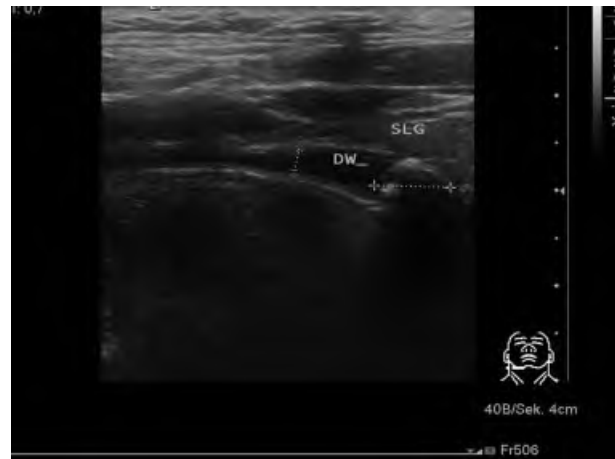


FIGURE 1. Sialolithiasis of the right submandibular gland. Oblique sonogram of the right submandibular gland shows the calculus (calipers) blocking the distended duct (DW). Abbreviation: SLG, sublingual gland.

but could not be demonstrated in its entire course. No changes in parenchymal gland echotexture were observed. There were no side effects of the ascorbic acid ingestion.

The 43 patients included 20 men and 23 women, with a mean age of 43.6 years (range, 18–78 years). In 14 of the 43 patients (33%), the submandibular gland and, in 29 cases (67%), the parotid gland was affected. In all 43 patients, only one salivary gland was affected. On US, the entire main duct was visible before ascorbic acid stimulation in 27 of 43 cases (63%). After stimulation, the entire main duct was visible in 41 of 43 cases (95%). In all 41 cases, the stimulation was thought by both examiners to improve the US diagnosis of ductal pathology (Figures 2 and 3), even in cases where the main duct was already visible on prestimulation examinations. Objective grading of the main duct dilation by measuring duct diameter at different points revealed no correlation with the type of disease (i.e., stenosis vs. calculi). There were 20 duct stenoses, 21 calculi, and 1 case of a combination of calculus and stenosis (Table 1). In one patient with a swollen right submandibular gland, the duct was not seen on US examination before and after stimulation. The sialendoscopy revealed no obstruction of the duct.

In another patient without duct visibility after stimulation, US showed bilateral hypoechoic atrophic parotid glands. The patient had a history of xerostomy for a period of 12 years, and an immunologic cause, rather than obstruction, was suggested and later corroborated by serologic tests.

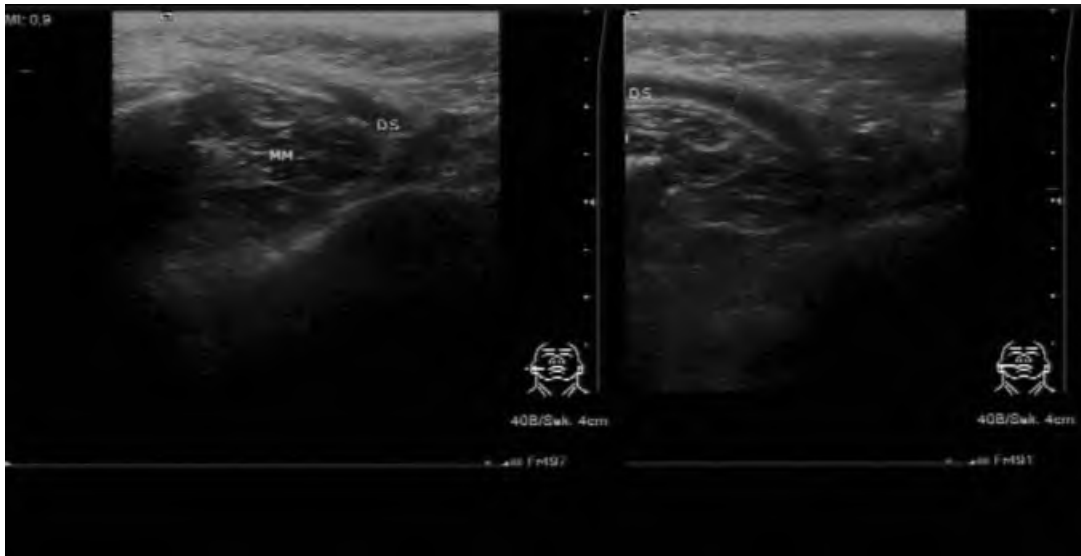


FIGURE 2. Ascorbic acid stimulation in a patient with distal Stensen's duct stenosis. Left: Transverse sonogram of the right parotid gland before stimulation shows minimally enlarged duct close to the ostium. Right: Sonogram obtained 60 seconds after stimulation shows the entire duct. Abbreviations: DS, Stensen's duct; MM, masseter muscle.

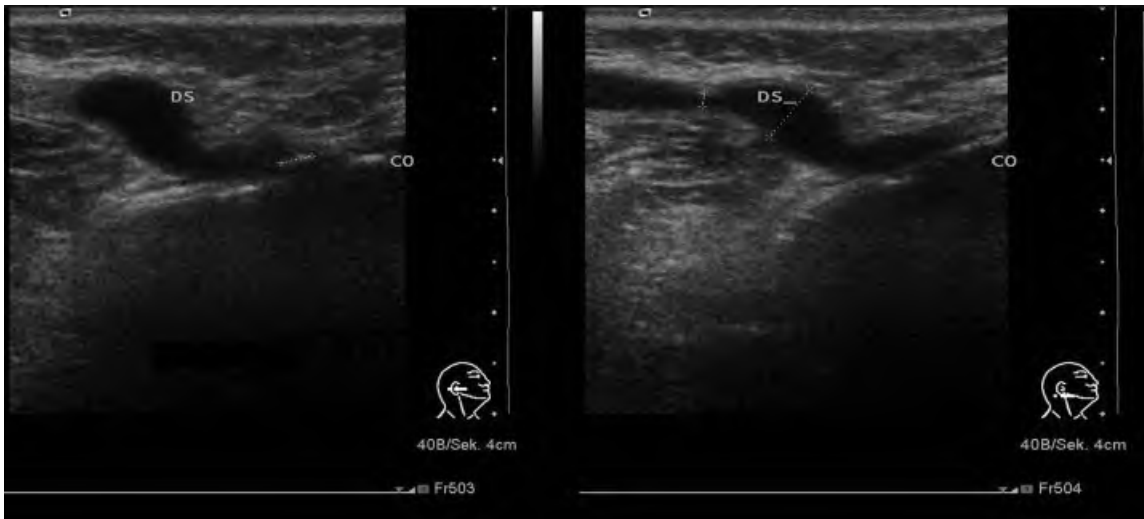


FIGURE 3. Ascorbic acid stimulation in a patient with Stensen's duct stenosis. Left: Transverse sonogram shows dilated duct near the ostium. Right: Transverse sonogram 60 seconds after ascorbic acid application shows the entire duct and detects a second narrowing (and calipers) delineated. Abbreviations: DS, Stensen's duct, CO, oral cavity.

DISCUSSION

US has become the imaging modality of choice in the evaluation of salivary glands as it is widely available and noninvasive. The US depiction of a dilated duct generally confirms the diagnosis of obstructive disease in a few minutes. However, it is not always possible to make a definitive diagnosis in patients with inflammatory and nonneoplastic swelling of the major salivary glands, despite the use of high-frequency US equipment.⁴ Reasons for the lack of US visibility of the main

duct may be a recent clinical examination, including bimanual palpation and milking of the duct system or drainage of the saliva by the pressure exerted by the US probe during the examination. Sialendoscopy generally allows a definitive diagnosis by allowing direct visualization of the ductal system.⁹ However, therapeutic options offered by this minimally invasive technique are optimized by the accurate preprocedural imaging of the cause of obstruction.

In patients suffering from obstructive disease, ascorbic acid stimulation improved the diagnostic

TABLE 1
Results of Stimulation with Ascorbic Acid on Duct
Visibility in Obstructive Salivary Gland Conditions
(Sialolithiasis and Duct Stenosis) Involving 29 Parotid
and 14 Submandibular Glands

	Duct		Sialolithiasis	No Obstruction
	Total	Stenosis		
Parotid gland				
Before stimulation				
Duct visible	20	18	3	0
Duct not visible				
After stimulation	9	0	8	1
Duct visible	27	18	10	0
Duct not visible	2	0	1	1
Submandibular gland				
Before stimulation				
Duct visible	7	0	7	0
Duct not visible	7	2	4	1
After stimulation				
Duct visible	13	2	11	0
Duct not visible	1	0	0	1

quality of the sonograms in 95% of our cases, facilitating selection of treatment options. Ascorbic acid stimulation was not effective in visualizing the main salivary gland duct in healthy volunteers, as expected.¹⁰ Ascorbic acid stimulation prolonged the examination time by only a few minutes with no side effects. Our data suggest that if a patient does not show duct dilation after ascorbic acid stimulation, there is no significant obstructive cause.

In conclusion, oral application of ascorbic acid improved the US visualization of the salivary gland ducts in the case of obstruction and should be used routinely in patients with the clinical picture of obstructive salivary gland disease, with a negative test virtually excluding the diagnosis of obstruction.

REFERENCES

1. Andretta M, Tregnaghi A, Prosenikliev V, et al. Current opinions in sialolithiasis diagnosis and treatment. *Acta Otorhinolaryngol Ital* 2005;25:145.
2. Gritzmann N, Rettenbacher T, Hollerweger A, et al. Sonography of the salivary glands. *Eur Radiol* 2003;13:964.
3. Alyas F, Lewis K, Williams M, et al. Diseases of the submandibular gland as demonstrated using high resolution ultrasound. *Br J Radiol* 2005;78:362.
4. Koch M, Zenk J, Iro H. Diagnostic and interventional sialoscopy in obstructive diseases of the salivary glands. *HNO* 2008;56:139.
5. Koch M, Zenk J, Bozzato A, et al. Sialoscopy in cases of unclear swelling of the major salivary glands. *Otolaryngol Head Neck Surg* 2005;133:863.
6. Morimoto Y, Ono K, Tanaka T, et al. The functional evaluation of salivary glands using dynamic MR sialography following citric acid stimulation: a preliminary study. *Oral Surg Oral Med Oral Pathol Oral Radiol Endod* 2005;100:357.
7. Tanaka T, Ono K, Habu M, et al. Functional evaluations of the parotid and submandibular glands using dynamic magnetic resonance sialography. *Dentomaxillofac Radiol* 2007;36:218.
8. Petridis C, Ries T, Cramer MC, et al. MR sialography: evaluation of an ultra-fast sequence in consideration of a parallel acquisition technique and different functional conditions in patients with salivary gland diseases [in German]. *Rofa* 2007;179:153.
9. Salerno S, Lo Casto A, Comparetto A, et al. Sialodochoplasty in the treatment of salivary-duct stricture in chronic sialoadenitis: technique and results. *Radiol Med (Torino)* 2007;112(1):138.
10. Zenk J, Hosemann WG, Iro H. Diameters of the main excretory ducts of the adult human submandibular and parotid gland: a histologic study *Oral Surg Oral Med Oral Pathol Oral Radiol Endod* 1998;85:576.