

Role of sialoscopy in the treatment of Stensen's duct strictures

Michael Koch, Heinrich Iro, Johannes Zenk

Angaben zur Veröffentlichung / Publication details:

Koch, Michael, Heinrich Iro, and Johannes Zenk. 2008. "Role of sialoscopy in the treatment of Stensen's duct strictures." *Annals of Otology, Rhinology & Laryngology* 117 (4): 271-78. <https://doi.org/10.1177/000348940811700406>.

Nutzungsbedingungen / Terms of use:

licgercopyright

Dieses Dokument wird unter folgenden Bedingungen zur Verfügung gestellt: / This document is made available under the following conditions:

Deutsches Urheberrecht

Weitere Informationen finden Sie unter: / For more information see:

<https://www.uni-augsburg.de/de/organisation/bibliothek/publizieren-zitieren-archivieren/publizieren>



Role of Sialoscopy in the Treatment of Stensen's Duct Strictures

Michael Koch, MD; Heinrich Iro, MD, PhD; Johannes Zenk, MD, PhD

Objectives: The origin of strictures of Stensen's duct often remains unclear, but chronic recurrent parotitis may be one associated disease. Failure of conservative therapy leads to a recommendation of parotidectomy in a high percentage of cases. Nowadays, development of new, minimally invasive methods may lead to a fundamental change in the treatment regimen.

Methods: We retrospectively evaluated 39 patients who presented with symptomatic strictures of Stensen's duct from 2002 to 2005. Sialoscopy was performed with semirigid endoscopes. Therapy consisted of irrigation and intraductal infusion of cortisone. If possible, interventional sialoscopy was carried out as the first-line procedure. If indicated, operative procedures of the duct were performed.

Results: After irrigation and intraductal medication, 17.9% of the patients were free of symptoms. Interventional sialoscopy was carried out in 74.4%, with a success rate of 75.9%. Operative duct procedures (extended papillotomy or resection of papilla stricture with duct reinsertion) were carried out in 23% of cases. In 5.1% of the total cases, parotidectomy was unavoidable.

Conclusions: Sialoscopy-based methods play a central role in gland-preserving treatment of strictures of Stensen's duct. Sialoscopy has proven to be a fast, useful, and relatively safe therapeutic tool with a high success rate. Parotidectomy is the last choice in symptomatic cases.

Key Words: obstruction, salivary gland, sialoscopy, Stensen's duct, stricture, treatment.

INTRODUCTION

The symptom of obstructive diseases of the salivary glands is recurrent painful swelling of the major salivary glands, especially after food intake. Strictures of Stensen's duct rarely cause the obstruction, and the reason remains unclear in nearly half of all cases, but chronic recurrent parotitis or other obstructive diseases of the parotid gland characterized by inflammation with eosinophilic reaction seem to be associated conditions. Other reasons may be infectious or granulomatous diseases, autoimmune diseases, radiotherapy, or radiiodine treatment.¹⁻⁴ Obstruction leads to reduced salivary flow, ascending duct infection, and formation of mucous or fibrinous plaques. Ductal wall changes, especially strictures, are the consequence.^{1,5} The treatment of those strictures is difficult, and the results are unsatisfying. Many reports deal with therapy of chronic parotitis, but publications that deal only with therapy of strictures are rare.⁵⁻⁹

Although clinical differentiation seems to be difficult, the therapies are quite similar.^{1,10} In about half

of cases, anti-inflammatory conservative therapy is no cure, but a relatively normal life can be achieved without invasive therapy.¹ Therapeutic irrigation with saline solution or contrast medium^{11,12} and intraductal application of various medications^{11,13} further improve therapeutic effects. In about 50% of cases, the disease does not respond to conservative measures and more aggressive therapy is indicated.^{1,10} More invasive methods used are duct ligation and operative duct procedures such as meatotomy or sialodochoplasty with duct reinsertion.^{1,10,14-16}

At present, new methods have appeared to support gland-preserving therapy, and minimally invasive therapeutic regimens have been developed. Radiologically controlled techniques such as balloon dilation have been used successfully to treat strictures of Stensen's duct.^{6-9,17,18}

The development of sialendoscopy provides an effective method for treating parotid gland diseases by inserting miniature surgical instruments, by providing minimally invasive interventional therapy, and by injecting medications into the duct and/or

From the Department of Otorhinolaryngology-Head and Neck Surgery, Friedrich Alexander University of Erlangen-Nuremberg, Erlangen, Germany.

Presented at the meeting of the American Academy of Otolaryngology-Head and Neck Surgery Foundation and the Otolaryngology Exposition, Toronto, Canada, September 17-20, 2006.

Correspondence: Michael Koch, MD, Dept of Otorhinolaryngology-Head and Neck Surgery, Friedrich Alexander University of Erlangen-Nuremberg, Waldstrasse 1, D-91054 Erlangen, Germany.

TABLE 1. CAUSES OF STRICTURES OF STENSEN'S DUCT IN 39 PATIENTS

Pretreatment or Associated Disease	Patients	
	No.	%
Manipulation of papilla		
Other reasons	4	10.3
Sialolithiasis	1	2.6
Partial parotidectomy (pleomorphic adenoma)	2	5.2
After treatment of sialolithiasis		
Extracorporeal shock wave lithotripsy	2	5.2*
Abscess incision	1	2.6
Allergy	3	7.7*
Autoimmune disease	3	7.7
Bruxism (chewing of mucosa of papilla region)	2	5.2
After radioiodine treatment	1	2.6
Suspected cause	19	48.7*
No obvious cause	20	51.3
Total	39	100

*Combined in one patient.

gland under direct vision.^{5,17,19-23} If complaints persist, parotidectomy is recommended in up to 40% of the cases.^{1,10,24-28}

This retrospective study describes our experiences in the treatment of 39 patients with symptomatic strictures of Stensen's duct treated in the 3.5 years between 2002 and 2005.

METHODS

Patients and Diagnosis. From 2002 to 2005, more than 600 patients were treated for obstructive salivary gland diseases. Thirty-nine patients had strictures of Stensen's duct, including 23 female and 16 male patients (age, 16 to 74 years; median, 49 years; average, 51.3 years). The patients who presented with combined strictures and sialolithiasis were excluded.

All patients had a history of recurrent swelling of the parotid gland, significantly reducing their quality of life. The time interval from the beginning of the complaints to presentation in our department ranged from 6 months to more than 20 years. The cause of the strictures was unclear in 51.2% of the patients (20 of 39). Nineteen patients had complaints due to prior therapy or had a history of conditions that are considered to be associated with obstructive parotid gland disease (Table 1). Twenty-two patients (56.4%) reported symptoms that had lasted longer than 12 months before presentation; in these cases, chronic recurrent parotitis may be considered as a possible cause. All patients had been treated in other institutions and were sent for further diagnosis and therapy.

Clinical examination showed enlarged and painful glands. In 6 cases, complete scarring of the pa-

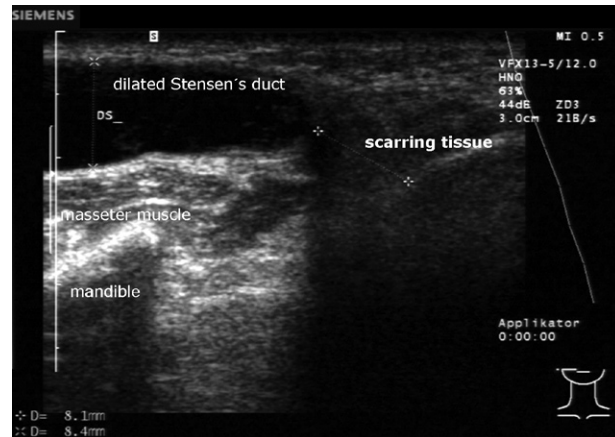


Fig 1. Ultrasound shows dilated Stensen's duct ("mega-ductus") due to stricture of papilla. Extent of scar can be measured exactly (10 mm).

pilla with a narrowed ostium was observable.

All patients were examined by ultrasound (Sono-line Elegra, 7.5 MHz, Siemens Medical Solutions, Issaquah, Washington). Typical sonographic signs were duct dilation, observable as an echo-poor band next to the masseter muscle, and a reduced echogenicity of the gland parenchyma in all cases (Fig 1).

To confirm the suspected diagnosis, we performed sialoscopy. Different types of semirigid endoscopes (sialoscopes; Polydiagnost Company, Pfaffenhofen, Germany, and Storz Company, Tuttlingen, Germany^{20,23}) were used, with diameters between 0.7 and 1.6 mm. The endoscopes suited for interventional therapy have two channels: one for irrigation and one for introduction of instruments (0.4 to 0.8 mm; Fig 2). The optical resolution ranged from 3,000 to 6,000 pixels. Various instruments, such as a wire basket, grasping forceps, a drill, and a balloon, which have diameters ranging from 0.38 to 0.75 mm, can be inserted through the working channel.^{20,23,29} Most sialoscopies were performed under local anesthesia; general anesthesia was restricted to certain cases (pediatric patients, noncompliance, etc). Before the sialoscope could be inserted, the papilla had to be dilated with custom-made dilators of variable diameters. Details regarding the technique of sialoscopy are described elsewhere.^{20,23} Sialoscopy was performed not only to prove and directly visualize the diagnosis, but also to classify the stricture (Fig 3) before performing simultaneous interventional therapy.

Treatments. While the diagnosis was confirmed by sialoscopy, the first step of therapy could be performed in the same procedure. This basic treatment consisted of duct dilation by the endoscope itself, duct irrigation during sialoscopy with saline solu-

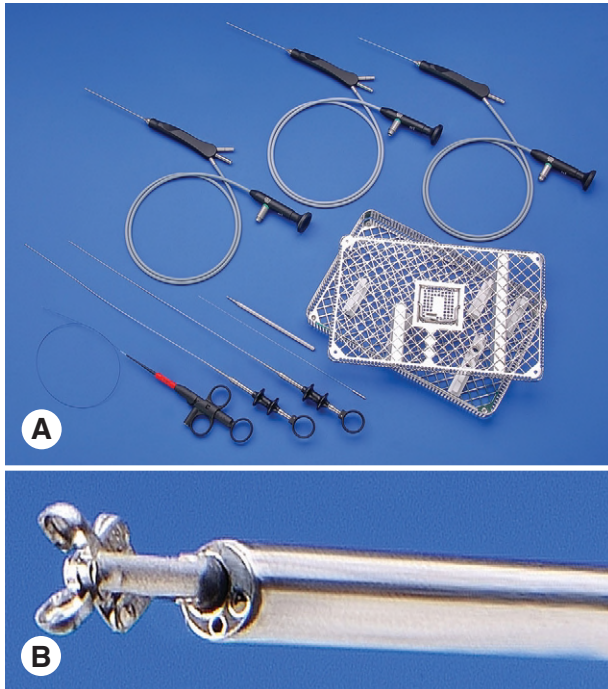


Fig 2. A) Sialoscopes with 2 working channels and B) instrument (grasp) in situ (Storz-Set).

tion, and application of cortisone into the duct after confirming the diagnosis with sialoscopy. So that it would not be washed out together with the irrigation solution shortly after the procedure, prednisolone (50 mg) was injected into the duct 2 hours after the procedure. Intraductal injections of prednisolone were continued weekly for 6 to 10 weeks. Also, routine systemic doses of anti-inflammatory medications (serrapeptase 20 mg 3 times per day and piroxicam 20 mg 2 times per day) were administered. In cases of intense inflammation, additional antibiotic medication (roxithromycine 300 mg 3 times per day or ampicillin with sulbactam 3 g 3 times per day for

7 to 10 days) was prescribed. Gland massage and a sialagogue were routinely recommended.

Interventional sialoscopy was performed simultaneously with the diagnostic procedure to dilate strictures and remove mucous or fibrinous plugs. Under direct vision and use of various instruments such as a microdrill, grasping forceps, wire basket, or high-pressure balloon (Fig 2), strictures were dilated until the lumen was wide enough to admit the endoscope. The aim was to dilate the duct to a width of at least 1 mm and to reestablish unhindered salivary gland flow (Fig 4).

Operative procedures of Stensen's duct were carried out when interventional sialoscopy was not successful or not possible, as in a case of scarred strictures of the papilla after extended papillotomy or distal duct slitting. The length of the duct obliteration could be estimated by ultrasound (Fig 1). In case of scarred strictures with duct obliteration, resection of the distal part of the duct was carried out, followed by reinsertion of the duct, which included suturing of the duct epithelium to the buccal mucosa (Fig 5). If necessary, stent implantation was performed. The stents were fixed with absorbable sutures (Vicryl 5-0, Johnson & Johnson International, St Stevens-Woluwe, Belgium) to the buccal mucosa and left in situ for 6 to 10 weeks (Figs 5C and 6B). We used custom-made stents of various lengths (20 to 40 mm) and sizes (4.5F to 6F) that were made of polyurethane (Sialotech Company, Ashkalon, Israel; Fig 6A,B). The correct position of the stent could be ascertained during and after operation by ultrasound (Fig 6C). Parotidectomy was used in therapy-resistant cases.

RESULTS

Ultrasound and Sialoscopic Findings. The diag-

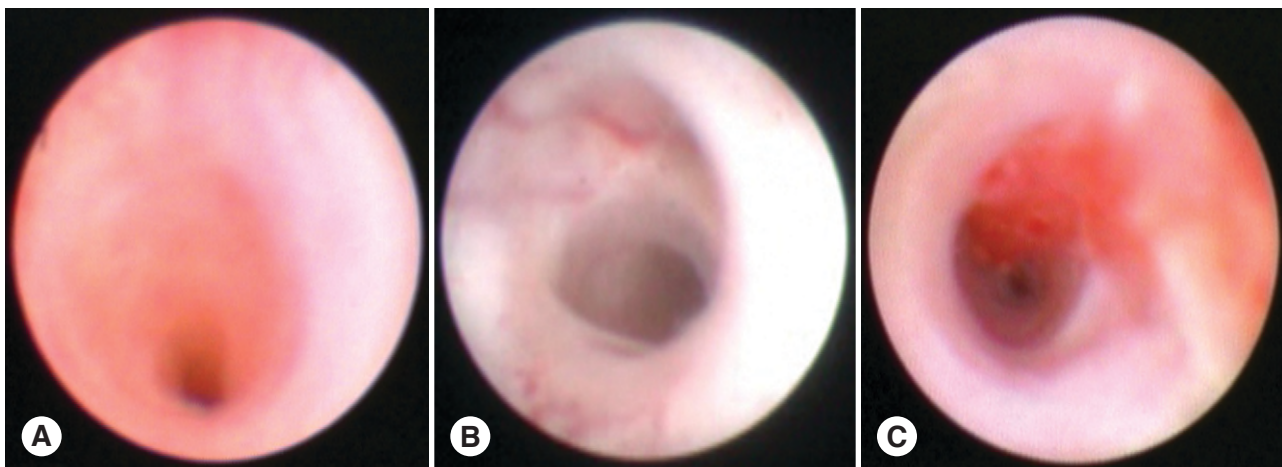


Fig 3. Sialoscopic findings of strictures of Stensen's duct. A) Stricture with predominantly inflammatory reaction. B) Relative stricture that could be passed by endoscope. C) Filiform fibrotic stricture with mucous plug.

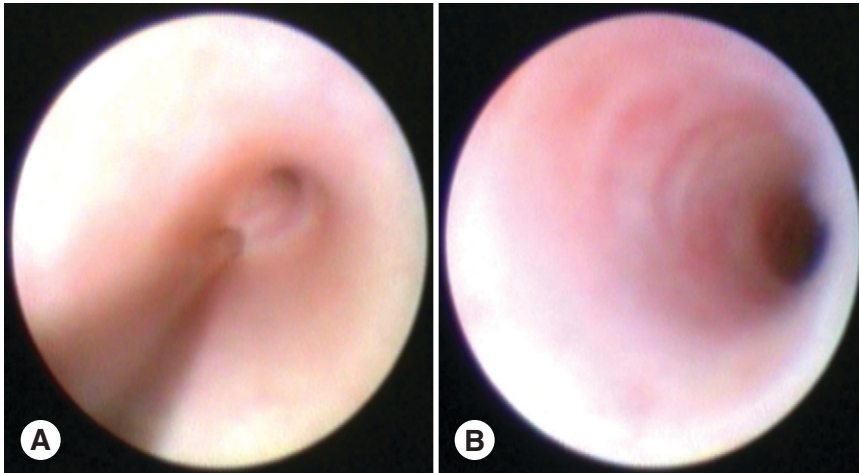


Fig 4. Interventional sialoscopy of stricture of Stensen's duct dilated with wire basket. **A)** Before dilation. **B)** After dilation.

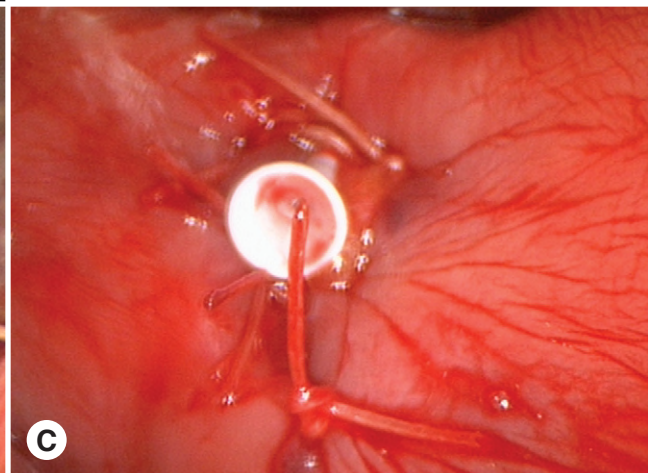
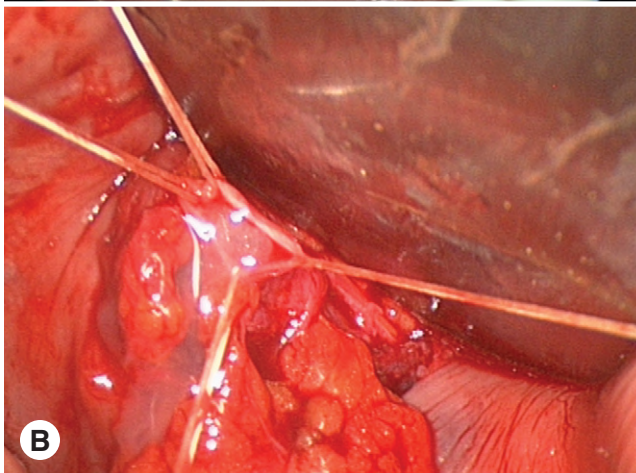
nosis that was suspected on ultrasound showed a high correlation with the correct clinical diagnosis disclosed by sialoscopy (Spearman's correlation coefficient 0.55; $p = .01$).

Sialoscopy showed consistently throughout all patients remarkable local or diffuse ductal changes

with signs of a thickened epithelial layer that included both stenotic and nonstenotic regions. Three main types of strictures could be differentiated with respect to their appearance and the extent. First, some strictures were dominated by intense inflammation with edema of the epithelium and with fibrinous discharge into the duct and mucous or fibrinous plaques

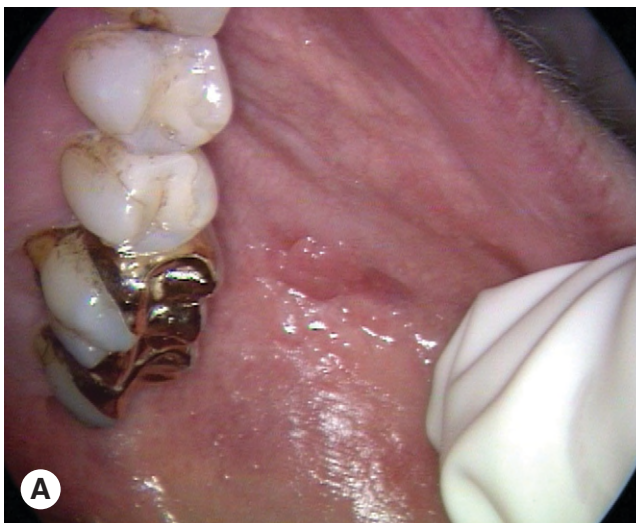

Fig 5. Duct slitting and reinsertion procedure with stent implantation. **A)** Scarred papilla before operation. **B)** After duct resection and reinsertion sutures. **C)** After stent implantation.



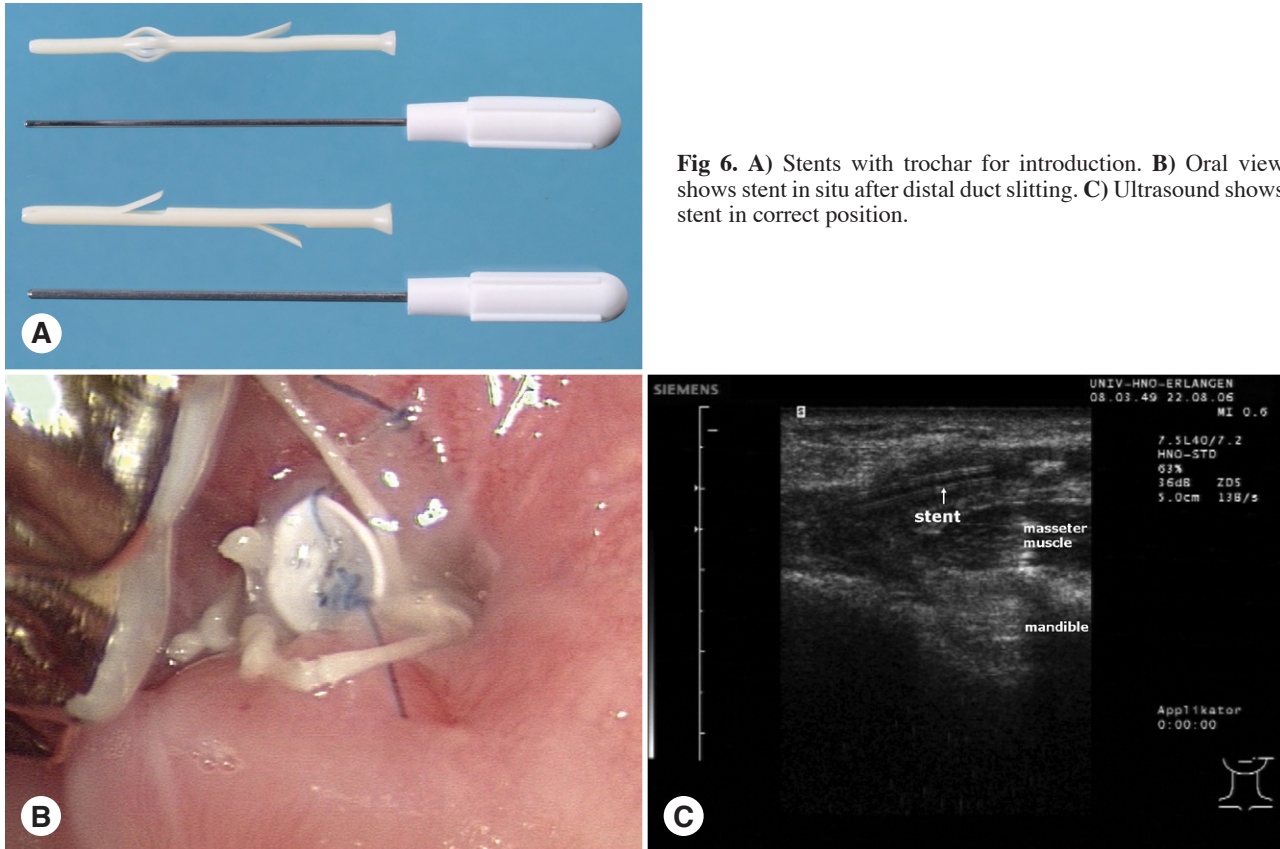


Fig 6. A) Stents with trochar for introduction. B) Oral view shows stent in situ after distal duct slitting. C) Ultrasound shows stent in correct position.

obstructing the duct lumen (combined inflammatory and fibrotic strictures; Fig 3A). Second, some strictures showed circular and weblike fibrotic formations that impeded maneuvering. Narrowing of the duct diameter was maximally 50%, and those areas could be passed by an endoscope with a diameter of 0.7 mm without forced power.²⁹ Therefore, those were called “relative strictures” (Fig 3B). Third, further narrowing of the duct lumen down to filiform strictures was observed most frequently and had to be dilated by the endoscope itself and/or other instruments (Fig 3C). In most cases, the strictures had a length of 1 to 2 cm.

Procedures and Treatment Results. Sialoscopies were performed in 38 patients under local anesthesia; in 1 case general anesthesia was necessary (16-

year-old boy with additional duct reinsertion). All procedures were well tolerated by the patients. The maximum times required were 20 minutes for the diagnosis, 45 minutes for additional interventional sialoscopy, and 60 minutes for operative duct procedures. No complications were observed.

In 3 patients, insertion of the endoscope was successful only after operative duct procedures (3 of 39; Table 2). Six patients had more than 1 sialoscopy (range, 2 to 4), and in 6 patients both glands were evaluated.

Therapy was adapted to the sialoscopic findings (Fig 3). In 17.9% (7 of 39) of sialoscopy-controlled procedures, anti-inflammatory therapy was successful and prevented progress of the disease in inflammatory and relative strictures.

Interventional sialoscopy with dilation of extended up to filiform strictures had to be performed in 29 patients (74%). Five patients had 2 procedures and 2 patients had 3 procedures because of therapy-resistant strictures (Table 2). The success rate of this therapy was 75.8% (22 of 29 procedures), representing 56.4% of all cases (22 of 39 patients).

In 23% of the patients (9 of 39), operative duct procedures were necessary, and they had a success rate of 67% (6 of 9; Table 2). Duct resection and re-

TABLE 2. PATIENTS AND OUTCOMES AFTER DIAGNOSTIC SIALOSCOPY, INTERVENTIONAL SIALOSCOPY, AND OPERATIVE DUCT PROCEDURES

Treatment	Patients	Success	Parotidectomy
Diagnostic sialoscopy (n = 39)*	100% (39/39)	17.9% (7/39)	
Interventional sialoscopy (n = 29)	74.4% (29/39)	75.9% (22/29)	2.6% (1/39)
Duct procedure (n = 9)	23.1% (9/39)	66.7% (6/9)	2.6% (1/39)

*In 3 patients, possible only after operative duct procedure.

insertion was performed in 5 cases (in 3 cases combined with stent implantation; Fig 5). Slitting of the distal part of Stensen's duct was carried out in 4 patients (in 3 of these cases combined with stent implantation; Fig 6).

Altogether, in 94.9% of cases, the parotid gland tissue was preserved and regenerated fully. In 5.1% of patients (2 of 39), parotidectomy could not be avoided (1 patient after repeated interventional sialoscopy on both sides after a 4-year period; 1 patient with complete duct obliteration after abscess incision due to sialolithiasis).

After the therapy, 92.3% of all patients (36 of 39; cases after parotidectomy included) reported improvement of symptoms with a good quality of life or were free of complaints. The results were well controlled and verified with ultrasound with respect to the local condition, as well as to parenchymal changes.²⁰

DISCUSSION

Strictures of Stensen's duct are not very frequent and the cause often is not clear, as in nearly 50% of our patients. Chronic (recurrent) parotitis may be one major cause.¹ Some authors have reported on isolated obstructive gland disease that was characterized by fibrinous plaques and marked eosinophilic reaction without allergic or autoimmune disease. Similar cases were observed in some of our patients, and these observations support the hypothesis of an obstructive gland disease that is dominated by eosinophilic infiltration. Whether this represents the early onset of chronic recurrent parotitis or an isolated disease that distinguishes it from the latter is not yet clear. When no underlying disease can be found, existence of a disease other than chronic recurrent parotitis that is limited to the gland should be taken into account.^{3,4,20}

The diagnosis of strictures in our patients was based on ultrasound examination and sialoscopy.²⁰ By ultrasound, indirect signs of stricture consisting of duct dilation without signs of sialolithiasis can be demonstrated (Fig 1). Alternatively, sialography has been established in many centers as the gold standard and is used with high success rates.^{5-9,13,17,21,22,26} Ultrasound is a cost-effective, fast, noninvasive, and highly predictive diagnostic tool, if performed adequately. Our results showed a highly significant correlation between suspected strictures and sialoscopic findings ($p = .01$). However, the quality of diagnosis is dependent on the experience of the examiner, and beyond this, stones that are less mineralized may not be recognized. The main advantage of sialography compared to ultrasound is that the

number and also the length of strictures can be estimated more adequately. Compared to ultrasound, however, it is an invasive procedure associated with irradiation, potential allergic reactions due to application of contrast medium, and additional costs. If performed adequately, both ultrasound and sialography are valuable tools in establishing the diagnosis of duct strictures of the major salivary glands.

Obstructive parotitis, especially a stricture of Stensen's duct, is difficult to treat. Successful treatment not only improves local symptoms and general quality of life, but also seems to resolve some associated symptoms of the autonomic nervous system.^{1,26,30} Systemic anti-inflammatory treatment that consists of administration of antibiotics and especially hydrocortisone is the established first-line therapy.^{1,10,26} Local treatment such as irrigation of the duct with contrast medium or saline solution and intraductal application of medications¹¹⁻¹³ was also recommended. However, these measures are not successful in as many as 40% to 50% of all cases, and further therapy is necessary.^{1,10} Publications that report results of operative duct procedures have reported high failure rates.^{1,10,14-16}

Further development of minimally invasive methods led to a revolution in the management of salivary gland diseases and has been proven to be useful in reaching the goal of preserving the gland, as well as permanent resolution of symptoms, with minimal morbidity.¹⁷ Radiologically controlled interventional duct dilation^{6-9,17,18} has shown good results and a success rate of more than 80%, but is performed only under fluoroscopic control. Interventional sialoscopy enables manipulation under direct visualization. The technical advances and improvements in new endoscopes with respect to size and optical and material features have consequently led to a widened spectrum of indications for diagnostic and interventional sialoscopy.^{5,10,17,19-23} Strictures of Stensen's duct are especially suited for this treatment, with success rates as high as 90%.^{5,20} Although it should be reserved only as the therapy of last choice, parotidectomy is still one of the most recommended treatments in chronic symptomatic obstructive parotid disease.^{1,10,24-28}

In our diagnostic concept, ultrasound plays an important role as our first-line diagnostic tool. Duct dilation and echogenic changes of gland parenchyma are signs of strictures that can be diagnosed by this method (Fig 1). When stricture is suspected on ultrasound, sialoscopy can establish the diagnosis and characterize the disorder (Fig 3).²⁰

Another advantage is that treatment can be carried out in the same procedure. Endoscopically con-

trolled conservative anti-inflammatory treatment improved symptoms and prevented progress of the disease in 17.9% of our patients, in particular in cases of fibrotic strictures that were superinfected and dominated by inflammation and in cases of limited fibrotic strictures ("relative strictures"; Fig 3A,B). The endoscope itself alone led to a significant dilation of the duct. Interventional sialoscopy is the first-line operative treatment for strictures that exceed more than 50% of the lumen up to filiform strictures (Fig 3C). Interventional sialoscopy was effective in dilating strictures in 75.8% of all procedures, and 56.4% of all patients were treated successfully with it as single-mode therapy.

In cases of failure of sialoscopic therapy, operative duct procedures as the next therapeutic option were performed with good results. Of these patients, 67% are now free of symptoms. This rate compares favorably with reported results.^{10,14-16,25} Stent implantation, and especially an adequate operative technique, reduces the risk of recurrent stricture.^{5,14} In cases of distal duct stricture, it seems to be important to perform an anastomosis of the duct epithelium to the buccal mucosa in a duct reinsertion procedure after resection of the obliterated duct. Cohen

et al¹⁴ reported 1 patient who was free of symptoms after repeated operative procedures, and emphasized that success seems to be connected to suturing mucosa to mucosa on the whole circumference of the orifice and creating a wide opening. Our results point in the same direction. After duct reinsertion, whether with or without stent implantation, all patients were free of complaints. Parotidectomy was carried out in 5.1% of our patients. These data compare favorably with rates of parotidectomy of up to 40% in other reports.^{10,24,25,27,28}

In conclusion, our concept of gland-preserving therapy is dominated by ultrasound- and sialoscopy-based methods. Intensive conservative measures are followed by extensive use of a spectrum of minimally invasive techniques. Parotidectomy was performed only as the last choice after a step-by-step progression to more aggressive treatments. This therapy regimen showed excellent results, with a gland preservation rate well over 90% and a low rate of complications, and it met with a high rate of acceptance and compliance by the patients. Gland-preserving, minimally invasive measures should be tried in every case, and parotidectomy should be limited only to therapy-resistant symptomatic cases.

REFERENCES

1. Baumash HD. Chronic recurrent parotitis: a closer look at its origin, diagnosis, and management. *J Oral Maxillofac Surg* 2004;62:1010-8.
2. Newkirk KA, Ringel MD, Wartofsky L, Burman KD. The role of radioactive iodine in salivary gland dysfunction. *Ear Nose Throat J* 2000;79:460-8.
3. Chikamatsu K, Shino M, Fukuda Y, Sakakura K, Furuya N. Recurring bilateral parotid gland swelling: two cases of sialodochitis fibrinosa. *J Laryngol Otol* 2006;120:330-3.
4. Qi S, Liu X, Wang S. Sialoendoscopic and irrigation findings in chronic obstructive parotitis. *Laryngoscope* 2005;115:541-5.
5. Nahlieli O, Shacham R, Yoffe B, Eliav E. Diagnosis and treatment of strictures and kinks in salivary gland ducts. *J Oral Maxillofac Surg* 2001;59:484-92.
6. Buckenham T, Guest P. Interventional sialography using digital imaging. *Australas Radiol* 1993;37:76-9.
7. Drage NA, Brown JE, Escudier MP, Wilson RF, McGurk M. Balloon dilatation of salivary duct strictures: report on 36 treated glands. *Cardiovasc Intervent Radiol* 2002;25:356-9.
8. Roberts DN, Juman S, Hall JR, Jonathan DA. Parotid duct stenosis: interventional radiology to the rescue. *Ann R Coll Surg Engl* 1995;77:444-6.
9. Waldman DL, Westesson PL, Hengerer AS. Balloon dilatation of parotid duct stenosis. *J Vasc Interv Radiol* 1998;9:167-8.
10. Motamed M, Laugharne D, Bradley PJ. Management of chronic parotitis: a review. *J Laryngol Otol* 2003;117:521-6.
11. Antoniadis D, Harrison JD, Epivatianos A, Papanayotou P. Treatment of chronic sialadenitis by intraductal penicillin or saline. *J Oral Maxillofac Surg* 2004;62:431-4.
12. Galili D, Marmary Y. Juvenile recurrent parotitis: clinicoradiologic follow-up study and the beneficial effect of sialography. *Oral Surg Oral Med Oral Pathol* 1986;61:550-6.
13. Bowling DM, Ferry G, Rauch SD, Goodman ML. Intraductal tetracycline therapy for the treatment of chronic recurrent parotitis. *Ear Nose Throat J* 1994;73:262-74.
14. Cohen D, Gatt N, Olschwang D, Perez R. Surgery for prolonged parotid duct obstruction: a case report. *Otolaryngol Head Neck Surg* 2003;128:753-4.
15. Münzel M, Meister P. On the ligation of Stenon's duct in chronic-recurrent parotitis [in German]. *Laryngol Rhinol Otol (Stuttg)* 1977;56:902-6.
16. Nichols RD. Surgical treatment of chronic suppurative parotitis. A critical review. *Laryngoscope* 1977;87:2066-81.
17. McGurk M, Escudier MP, Thomas BL, Brown JE. A revolution in the management of obstructive salivary gland disease. *Dent Update* 2006;33:28-30, 33-6. [Erratum in *Dent Update* 2006;33:83.]
18. Brown JE. Minimally invasive techniques for the treatment of benign salivary gland obstruction. *Cardiovasc Intervent Radiol* 2002;25:345-51.
19. Katz P. New method of examination of the salivary glands: the fiberscope [in French]. *Inf Dent* 1990;72:785-8.
20. Koch M, Zenk J, Bozzato A, Bumm K, Iro H. Sialoscopy in cases of unclear swelling of the major salivary glands. *Otolaryngol Head Neck Surg* 2005;133:863-8.
21. Marchal F, Dulguerov P, Becker M, Barki G, Disant F, Lehmann W. Specificity of parotid sialendoscopy. *Laryngoscope* 2001;111:264-71.

22. Nahlieli O, Baruchin AM. Long-term experience with endoscopic diagnosis and treatment of salivary gland inflammatory diseases. *Laryngoscope* 2000;110:988-93.
23. Zenk J, Koch M, Bozzato A, Iro H. Sialoscopy — initial experiences with a new endoscope. *Br J Oral Maxillofac Surg* 2004;42:293-8.
24. Amin MA, Bailey BM, Patel SR. Clinical and radiological evidence to support superficial parotidectomy as the treatment of choice for chronic parotid sialadenitis: a retrospective study. *Br J Oral Maxillofac Surg* 2001;39:348-52.
25. Moody AB, Avery CM, Walsh S, Sneddon K, Langdon JD. Surgical management of chronic parotid disease. *Br J Oral Maxillofac Surg* 2000;38:620-2.
26. Nahlieli O, Bar T, Shacham R, Eliav E, Hecht-Nakar L. Management of chronic recurrent parotitis: current therapy. *J Oral Maxillofac Surg* 2004;62:1150-5.
27. O'Brien CJ, Murrant NJ. Surgical management of chronic parotitis. *Head Neck* 1993;15:445-9.
28. Sadeghi N, Black MJ, Frenkiel S. Parotidectomy for the treatment of chronic recurrent parotitis. *J Otolaryngol* 1996;25:305-7.
29. Zenk J, Hosemann WG, Iro H. Diameters of the main excretory ducts of the adult human submandibular and parotid gland: a histologic study. *Oral Surg Oral Med Oral Pathol Oral Radiol Endod* 1998;85:576-80.
30. Gear KJ, Hay KD, Stumpel J. Treatment of parotid ductal stenosis and concomitant resolution of autonomic symptomatology. *Oral Surg Oral Med Oral Pathol Oral Radiol Endod* 2002;94:632-5.