

Neck lymph nodes: prediction by computer-assisted contrast medium analysis?

**Johannes Zenk, Alessandro Bozzato, Joachim Hornung, Frank
Gottwald, Christina Rabe, Sandra Gill, Heinrich Iro**

Angaben zur Veröffentlichung / Publication details:

Zenk, Johannes, Alessandro Bozzato, Joachim Hornung, Frank Gottwald, Christina Rabe, Sandra Gill, and Heinrich Iro. 2007. "Neck lymph nodes: prediction by computer-assisted contrast medium analysis?" *Ultrasound in Medicine & Biology* 33 (2): 246–53. <https://doi.org/10.1016/j.ultrasmedbio.2006.08.005>.

NECK LYMPH NODES: PREDICTION BY COMPUTER-ASSISTED CONTRAST MEDIUM ANALYSIS?

JOHANNES ZENK,* ALESSANDRO BOZZATO,* JOACHIM HORNUNG,* FRANK GOTTWALD,*
CHRISTINA RABE,[†] SANDRA GILL,* and HEINRICH IRO*

*Department of Otorhinolaryngology, Head and Neck Surgery; and [†]Institute for Medical Informatics, Biometry and Epidemiology, University of Erlangen-Nuremberg, Erlangen, Germany

INTRODUCTION

Evaluation of cervical lymph nodes during staging of malignancy and posttherapeutic evaluation of cervical status in patients with head and neck tumours are among the most difficult and frequent requests made to ultrasonographers. Moreover, diagnosis of ipsilateral or bilateral lymph node metastases determines further therapeutic procedures and, at the same time, reduces the 5-y survival rate to 50%, or even 25% (Som 1987). Furthermore, primary ultrasound evaluation of new enlarged lymph nodes in patients with no history of risk factors or tumour diseases is of almost equal importance (Rubaltelli et al. 2004). Clinical examination with palpation, B-scan and colour-coded Doppler ultrasonography, or power Doppler ultrasound, together achieve sensitivities and specificities of as high as 90%. In some studies, they

may even exceed 90% depending on the type of study and the experience of the investigator (Ahuja and Ying 2005; Dragoni et al. 1999; Maurer et al. 1997; Steinkamp et al. 2002; Wu et al. 2000). Currently, the most important criteria in B-scan sonography are the shape and size (diameter/length, Solbiati Index), infiltration of surrounding structures, inhomogeneous internal echo patterns and the presence or absence of echo-rich hilar structures (Ahuja and Ying 2005; Delorme et al. 1997; Rubaltelli et al. 2004; Schroder et al. 1998; Solbiati et al. 1988; Steinkamp et al. 1998; Tschammler et al. 1995; Van den Brekel et al. 1998; Wu et al. 2000). Difficulties may arise with lymph nodes of a size <15 mm because the characteristics mentioned are often missing (Giancarlo et al. 1998). With colour Doppler and power Doppler examination, the pattern, the amount and the distribution of lymph node perfusion can be demonstrated, thus yielding additional information concerning the malignant potential of cervical lymph nodes (Ariji et al. 1998; Dragoni et al. 1999; Issing et al. 1999; Steinkamp et al. 2002; Wu et al. 2000). These alterations are a

Address correspondence to: J. Zenk, M.D., Department of Otorhinolaryngology, Head and Neck Surgery, University of Erlangen-Nuremberg, Waldstrasse 1, D-91054 Erlangen, Germany. E-mail: johannes.zenk@hno.imed.uni-erlangen.de

consequence of global changes during tumour invasion of lymph nodes, mainly because of tumour angiogenesis (Ellegala et al. 2003; Moritz et al. 2000; Valentin 1997). The introduction and use of ultrasound contrast medium usually improved the demonstration of vascular architecture in lymph nodes and, thus, led to a better evaluation of criteria for malignant or benign changes (Chikui et al. 2000; Moritz et al. 2000). Up to now, nearly all colour-coded and power Doppler studies have been based on subjective or semiquantitative evaluations. A study from our own group on the contrast medium kinetics of Levovist gave initial evidence that objective characteristics may significantly improve differentiation between benign and malignant lymph nodes (Zenk et al. 2005). In the present prospective study, the value of contrast medium kinetics in cervical lymph nodes using the contrast medium SonoVue (sulfur hexafluoride) from Bracco (Alta Pharma, Konstanz, Germany) has been tested and compared with the previously recognized criteria of B-scan power Doppler ultrasound. In addition, special software was used for an automated evaluation and measurement of specific quantitative parameters of contrast medium behaviour, with the aim of establishing new criteria for differentiating metastatic spread to cervical lymph nodes from lymph nodes with inflammatory changes.

MATERIALS AND METHODS

Sixty patients were recruited into our study between January and September 2005. They were all investigated for enlarged lymph nodes of unclear origin or, in the course of tumour therapy, either for local lymph node excision or neck dissection. In all patients, the relevant marked lymph nodes were removed surgically after palpation and sonographic investigation, and then processed histologically.

The study was approved by the Ethics Committee (no. 2975). Written informed consent was obtained from all patients.

All ultrasound investigations were carried out using the Sonoline Elegra Advanced probe (Siemens Medical Solutions, Erlangen, Germany) and a high-resolution broadband ultrasound transducer (7.5L40, 5-10 MHz). The lymph nodes were measured in three dimensions and classified according to the following sonographic criteria:

- Size (maximum diameter).
- Shape: round (length/cross-section diameter [CSD] <2) or oval (length/CSD >2).
- Perfusion in the power Doppler (hilus, marginal, mixed, no perfusion). Here a simplified classification according to Tschammler et al. (1995) was applied.

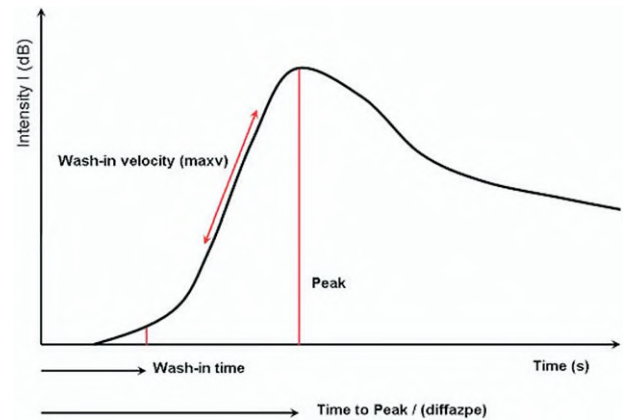


Fig. 1. Idealized wash-in and wash-out curve measured by the software AXIUS ACQ6, with the parameters used for statistical analysis: intensity I measured in dB; wash-in time (s): time after start of recording in which the intensity increases to 10% of the maximum increase in intensity compared with baseline; wash-in velocity (maxv) (dB/s): rate of increase in contrast medium; peak (dB): The peak dB value compared with the baseline; time to Peak / (diffazpe) (s): time from start of recording to peak.

A second part of the ultrasound examinations consisted of the use of contrast-enhanced computer-assisted perfusion analysis of the tumour using the AXIUS ACQ6 analysis software (Siemens Medical Solutions, Mountainview, CA, USA). This is an integrated function for contrast-enhanced tissue visualization and analysis. Demonstration of the time-dependent changes in pixel intensity allows evaluation of the perfusion status and quantitation of the tissue blood supply. The wash-in and wash-out data were recorded and evaluated in three selected regions-of-interest (ROIs) in the central, peripheral and total cross-section of the lymph node, which varied in size (and location depending on the size and shape of the examined node 2-20 mm) and the findings in the power Doppler sonography (Figs. 1 and 2). The parameters determined were:

- Intensity I (in dB).
- Wash-in time (in s) = time after start of recording in which the intensity increases to 10% of the maximum increase in intensity compared with baseline.
- Wash-in velocity (in dB/s) = rate of increase in contrast medium.
- Peak (in dB) = the peak dB value compared with the baseline.
- Time to peak (in s) = time from start of recording to peak.

After switching to the contrast harmonic imaging mode, the following constant settings were chosen: sub-sampling rate 8, frame rate 30/s and power setting 3%.

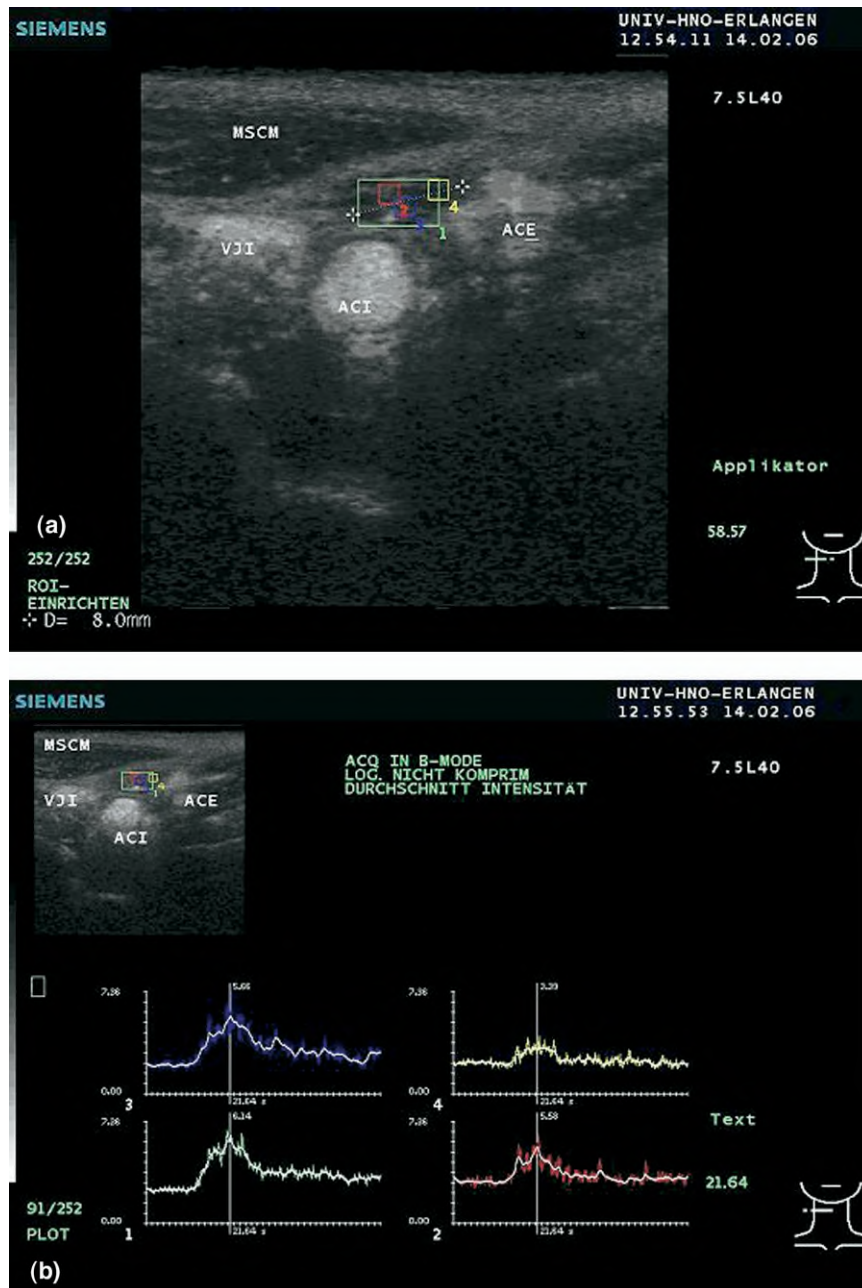


Fig. 2. (a) Colour differentiated ROIs are shown in the peripheral, central and whole lymph node area. (b) Lymph nodes after definition of ROIs (AXIUS ACQ6) with the relevant contrast medium wash-in curves. ACI, internal carotid artery; ACE, external carotid artery; VJI, internal jugular vein; MSCM, sternocleidomastoid muscle.

With intravenous access at the elbow, the patients were given SonoVue (Bracco) at a dosage of 8 μmL granules in 0.9% saline solution as a bolus over 5 s, followed by 10 mL of saline solution. Digital documentation of the ultrasound examination was conducted immediately before and as many as 90 s after the contrast medium injections (252 individual frames). A second identical measurement of the same lymph node was repeated after 15 min.

The postoperative prepared lymph node samples corresponding to the ultrasound levels were embedded in paraffin, sectioned, stained with hematoxylin and eosin and examined and reported on by an experienced pathologist. Correspondence of histologic slices to ultrasound images was assured by preoperative marking of the skin area above the respective lymph node. In addition, the sonographer was identical to the surgeon in most cases or present at the time of operation and was also responsible for the first cut into the node.

Table 1. Distribution of maximum diameter of lymph nodes and malignancy

	Lymph nodes		Ratio Benign/ Malignant	Total
	Benign	Malignant		
0-10mm	9 (23.68%)	1 (4.55%)	90% / 10%	10
11-20mm	21 (55.26%)	9 (40.91%)	70% / 30%	30
21-30mm	4 (10.53%)	6 (27.27%)	40% / 60%	10
31-40mm	4 (10.53%)	5 (22.73%)	44% / 56%	9
>40mm	0 (0.00%)	1 (4.55%)	0% / 100%	1
Total	38	22		60

For demonstration of the vascular supply, representative sections were also stained with an antibody binding to the endothelial marker CD34 (Immunotech, Marseilles, France).

The vascular diameter and length were determined to explore possible correlations between perfusion behavior of the tumours and vascular characteristics. For each specimen, four regions were estimated at 100 times (1 mm²) magnification.

Two criteria were used for evaluation. The first was the number of microvessels per mm². In the individual regions, the stained endothelial cells or cell clusters were identified, evaluated as microvessels and summed. Demonstration of a lumen was not mandatory. Second, vessels with a diameter >0.1 mm (macrovasculars) were also determined in the same four defined regions, and the sum was counted as the overall number of vessels in the preparation sections.

In the statistical analysis, sensitivity, specificity and the Youden index (as an additional single value for the accuracy of the test procedure with values between 0 and 1: $YI = \text{sensitivity} + \text{specificity} - 1$; Youden (1950)) were calculated to evaluate the prediction capability of the ultrasound methods with regard to the malignancy of lymph nodes as given by the pathologist. Fisher's exact test was used to assess the statistical significance of the relationship between qualitative subjective sonomorphologic parameters and malignancy of lymph nodes. The Wilcoxon Mann-Whitney *U* test was used to compare the distribution of quantitative parameters among benign and malignant lymph nodes. Quantitative parameters were further evaluated by receiver operator characteristics (ROC) analysis. Optimal cut-points were chosen so as to maximize the Youden index. Parameters that performed with promise (best ROC/area under the curve [AUC]) were then included in a multivariate logistic regression analysis. Different logistic regression models based on different subsets of variables were computed and resulting AUCs of different models were

Table 2. Shape of lymph nodes and malignancy

Shape	Lymph nodes		Ratio Benign/ Malignant	Total
	Benign	Malignant		
Oval	34 (89.47%)	9 (40.91%)	79% / 21%	43
Round	4 (10.53%)	13 (59.09%)	24% / 76%	17
Total	38	22		60

then compared using the nonparametric method of DeLong et al. (1988).

Analysis was carried out using the "R" statistical program with the additional package "rocr" (R Development Core Team 2005).

RESULTS

Of a total of 60 investigated lymph nodes, 22 (36.7%) were diagnosed as metastases from a squamous cell carcinoma, whereas 38 lymph nodes showed acute or chronic reactive changes. Regarding the size of the lymph nodes, the probability of malignant change was considerably increased with increasing size ($p = 0.0473$, Fischer's exact test) as expected (Table 1).

Taking into account the shape of the lymph nodes, the nodes with reactive changes were significantly more often oval-shaped, whereas lymph nodes with metastases were more likely to be round ($p < 0.001$, Table 2). However, 10% ($n = 4$) of all lymph nodes with reactive changes were round, and 41% ($n = 9$) of all malignant lymph nodes were oval in shape.

Considering the qualitative perfusion distribution as seen in power Doppler mode, as an additional parameter in the diagnostic procedure, showed that perfusion was increased in the hilus of all lymph nodes (68.3%). For malignant lymph nodes, marginal or diffuse perfusion was more frequent than for benign lymph nodes in the group investigated (27.3% and 18.2% vs. 5.3% and 5.3%). This association was significant ($p = 0.0089$, Table 3). However, 10% of the benign lymph nodes

Table 3. Perfusion pattern and malignancy

Perfusion	Lymph nodes		Ratio Benign/ Malignant	Total
	Benign	Malignant		
Hilus	29 (76.32%)	12 (54.55%)	70% / 30%	41
Marginal	2 (5.26%)	6 (27.27%)	25% / 75%	8
Diffuse	2 (5.26%)	4 (18.18%)	33% / 67%	6
None	5 (13.16%)	0 (0.00%)	100% / 0%	5
Total	38	22		60

Table 4. Classification rules and statistical analysis

Combination	Misclassification	Sensitivity (95% CI)	Specificity (95% CI)	Youden index
Shape round	(13) 0.2167	0.5909 (0.36-0.79)	0.8947 (0.75-0.97)	0.4856
Shape round and perfusion (Perfusion not hilar and diameter \geq 25 mm) or shape round	(12) 0.2000	0.5909 (0.36-0.79)	0.9211 (0.79-0.98)	0.5120
(Perfusion not hilar and diameter \geq 25 mm) or (shape round and perfusion)	(10) 0.1667	0.7273 (0.50-0.89)	0.8947 (0.75-0.97)	0.6219
	(9) 0.1500	0.7273 (0.50-0.89)	0.9211 (0.79-0.98)	0.6484

showed marginal or diffuse perfusion and 54.5% of all lymph nodes with metastases had hilar perfusion alone.

Applying certain classification criteria to this group of patients, *i.e.*, by defining certain variables that separate benign from malignant lymph nodes, showed that different variables gave different values for sensitivity, specificity and the Youden index. This revealed suitable variables for defining the malignant potential. For instance, round or oval shape alone gave a sensitivity of 59% and a specificity of 89.5%, with a misclassification rate (rate of false-positive or false-negative classification of lymph nodes) of 13 lymph nodes (21.7%). The lowest misclassification rate of nine lymph nodes (15%) was achieved by a combination of perfusion characteristics, shape and size, with a sensitivity of 72.7% and a specificity of 92% (Youden index 0.64). Table 4 shows the mean statistical parameters in relation to the classification criteria.

Analyzing the contrast medium kinetics during sonography, the parametric variables wash-in time, time to peak, maximum value and mean transit time were determined in various regions of the lymph nodes (whole lymph node, hilum, central, peripheral). This showed that significant differences in perfusion behavior were only evident in the hilar region. Malignant lymph nodes had a shorter wash-in time and time to peak (Table 5).

Using the new objective data for contrast medium wash-in in ROC curve analysis, and calculating the op-

timal cut points for differentiation between benign and malignant changes, the maximum sensitivities varied from 77.3% to 81.8% and specificities varied from 47.4% to 60.5% (Table 6).

To compare the diagnostic power of subjective and objective parameters, various logistic regression models were calculated using the malignancy/benignity as the dependent variable and different parameters as the independent variables.

In model 1, the four best variables from the “objective” perfusion measurements were used (wash-in hilum, wash-in total cross-section of lymph node, peak, increase).

In model 2, objective and previously recognized parameters for defining malignant changes were combined (wash-in time, peak, increase; shape, perfusion pattern [hilum, margin, central, diffuse, none], maximum diameter).

In model 3, the previously recognized parameters were used alone (shape, perfusion pattern [hilum, margin, central, diffuse, none], maximum diameter).

These models were used to calculate the likelihood for a lymph node being malignant, and this was used for classification.

Figure 3 shows the ROCs for the three models investigated. It reveals that using the continuously-measured “objective” variables either alone or in combination does not increase the accuracy of diagnosing malig-

Table 5. Comparison of distribution of perfusion measurements in benign and malignant lymph nodes regarding node hilum

Region	Variable	Malignancy	N	Median	Mean	STD	Min	Q1	Q3	Max	p value
Hilus	Wash-in time	Benign	38	14.77	16.29	8.53	2.14	12.62	19.04	49.62	0.0478*
		Malignant	22	13.08	12.98	7.81	1.69	7.73	14.99	37.39	
	Peak	Benign	38	26.07	30.09	14.43	3.76	20.08	35.94	74.16	
		Malignant	22	21.45	23.76	10.81	8.11	18.42	27.21	64.29	
	Wash-in velocity	Benign	38	3.84	5.18	3.47	0.58	2.12	7.79	12.01	
		Malignant	22	3.79	4.72	3.92	0.08	1.07	7.76	13.50	
	MTT	Benign	38	38.17	40.77	17.90	7.21	34.43	46.36	130.14	
		Malignant	22	37.15	40.28	15.84	8.96	31.64	47.48	88.86	

*Statistically significant.
MTT, Mean transit time.

Table 6. Optimal cut points from ROC analysis for contrast medium kinetics variables

Variable	Cut point	Sensitivity	Specificity	Youden Index	AUC
Wash-in time (hilus)	<15.90	0.818	0.474	0.292	0.655
Time to peak (hilus)	<24.55	0.682	0.605	0.287	0.654
Maximum increase (central LN)	<5.73	0.773	0.553	0.325	0.651

LN, Lymph node.

nant changes in lymph nodes in this group of patients. The AUC for models 2 and 3 differ significantly from the AUC of model 1 ($p = 0.0017$ and $p = 0.0077$). However, there is no significant difference between models 2 and 3 ($p = 0.3035$).

As to the association between the vascular distribution and perfusion characteristics, there was no significant correlation between vessel thickness, vessel diameter and the perfusion pattern or wash-in variables.

DISCUSSION

Despite developments in imaging procedures, pre-operative staging of cervical lymph nodes in patients with head and neck tumours is one of the most difficult tasks for the diagnostician. The correct diagnosis is cru-

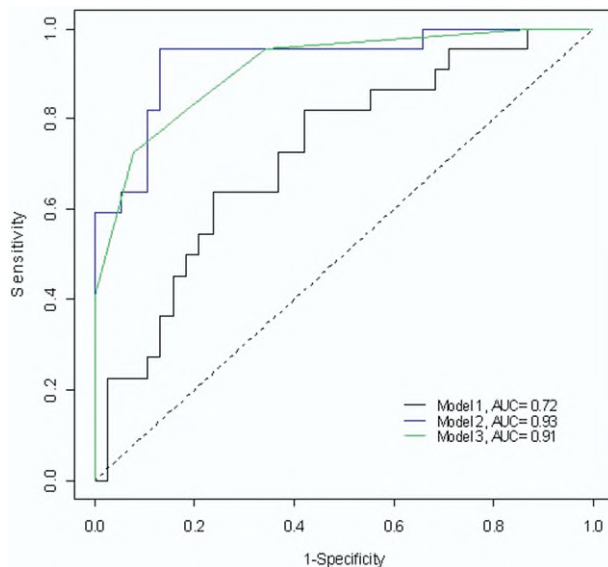


Fig. 3. ROC curves from logistic regression analysis. The AUC is shown for three parameter combinations. Model 1: objective parameters only (wash-in time, peak, wash-in time, increase). Model 2: mixture of subjective criteria and contrast medium characteristics (wash-in time, peak, wash-in time, increase; shape, perfusion pattern, maximum diameter). Model 3: mixture of relevant objective and subjective criteria (shape, perfusion pattern, maximum diameter).

cial for the patient because it determines the future therapy and prognosis. The surgeon has to cope with a dilemma of “over-treatment” because of the risk of overlooking malignant lymph nodes, as well as of overlooking malignant lymph nodes, thus significantly worsening the patient’s prognosis by delaying treatment.

For B-scan sonography, there are well-established criteria for evaluating lymph nodes as we already explained in the introduction. The application of colour-coded ultrasound and power Doppler sonography has resulted in the definition of many different perfusion patterns to distinguish whether a lymph node is enlarged because of inflammation or malignant deposits (Ahuja and Ying 2004, 2005; Giovagnorio et al. 1997; Tschammler et al. 2002; Wu et al. 1998). All of these methods yield sensitivities between 55% and 85%, and specificities of 47% to 91% (Wu et al. 1998). The literature gives conflicting views on whether native colour-coded sonography or power Doppler sonography is more suitable for defining the vascular architecture of lymph nodes. Although in more recent studies, Hamper et al. (1997) and Schulte-Altendorneburg et al. (2003) favor power Doppler, Ahuja and Ying (2004) did not find any difference in the use of the two methods.

In the classification of our patient group using different variables, we reproduced exactly the values using parameters from the literature (size, shape and perfusion characteristics), giving a maximum mean sensitivity of 72.7% and a mean specificity of 92.5% (Youden index 0.65), thus similar to published values.

Moritz et al. (2000) reported an increased sensitivity and specificity of 100% and 98%, respectively, in 94 lymph nodes using ultrasound contrast medium. Schroder et al. (1998) were able to define and classify the vascular architecture in 23% of all lymph nodes, investigated only after administration of contrast medium. In the present study, only five lymph nodes (13%) showed no vascular architecture in power Doppler, and all of these were classified as benign on histology. In contrast, other authors have reported no improvement in predictive power from using ultrasound contrast medium. They suggest that this is because of increased vascularization of lymph nodes together with a significant increase in the rate of artifacts. This can distract the observer, making less notice of the substantial vascular patterns (Schulte-Altendorneburg et al. 2003).

To free ultrasound examination from observer subjectivity, attempts have been made to find objective parameters that allow differential diagnosis independent of the investigator. In Doppler sonography, for instance, the pulsatility and resistance indices (PI, RI) have been used to support differentiation. Although no difference was found between PI and RI in malignant and benign lymph nodes (Benzel et al. 1996), Issing et al. (1999)

reported that using a cut point of PI <0.6 for metastases increased the specificity significantly to 92%. Ho et al. (2001) studied data for RI and PI and concluded that, depending on the method chosen, there were relatively large variations in RI (0.69–0.88) and PI (1.28–2.34) in the same lymph nodes. They called for future better standardization in examination technique to ensure comparability of studies. Ying et al. (2004) reported on a cut point for RI >0.8 for differentiation of metastases from lymphomas, as well as for PI >1.5 for differentiation of metastases from tuberculous lymph node disease.

Another way to objectify contrast medium-assisted sonography has been described by our group in a study of the kinetics of the ultrasound contrast medium Levovist® in neck lymph nodes (Zenk et al. 2005).

Although the new objective parameters concerning the kinetics of contrast medium in neck lymph nodes reported here for the first time are statistically significant, their predictive power is not yet reliable enough for routine clinical use. The logistic regression analysis showed that they did not enhance conventional ultrasound morphologic parameters.

The more favorable results of the semiquantitative parameters may be a result of operator experience, which incorporates many other poorly measurable parameters. It is also possible that this may be a function of the particular patient group used. These two factors may be responsible for the somewhat discordant predictions, with regard to the differentiation of malignancy by ultrasound.

Therefore, it is important to define classification criteria that are independent of the observer, and to validate these in large groups of patients. Based on raw ultrasound data, computer-guided self-learning analysis systems, such as the one described by Scheipers et al. (2005), may lead to identification of investigator-independent classification characteristics.

Acknowledgement—This work was supported by the Wilhelm-Sander-Foundation (no. 2004.014.1).

REFERENCES

- Ahuja AT, Ying M. Evaluation of cervical lymph node vascularity: A comparison of colour Doppler, power Doppler and 3-D power Doppler sonography. *Ultrasound Med Biol* 2004;30:1557–1564.
- Ahuja AT, Ying M. Sonographic evaluation of cervical lymph nodes. *AJR Am J Roentgenol* 2005;184:1691–1699.
- Ariji Y, Kimura Y, Hayashi N, et al. Power Doppler sonography of cervical lymph nodes in patients with head and neck cancer. *Am J Neuroradiol* 1998;19:303–307.
- Benzel W, Zenk J, Winter M, Iro H. Colour Doppler ultrasound studies of benign and malignant lymph nodes. *HNO* 1996;44:666–671.
- Chikui T, Yonetsu K, Nakamura T. Multivariate feature analysis of sonographic findings of metastatic cervical lymph nodes: contribution of blood flow features revealed by power Doppler sonography for predicting metastasis. *Am J Neuroradiol* 2000;21:561–567.
- DeLong ER, DeLong DH, Clarke-Pearson DL. Comparing the areas under two or more correlated receiver operating characteristic curves: A nonparametric approach. *Biometrics* 1988;44:837–845.
- Delorme S, Dietz A, Rudat V, et al. Prognostic significance of colour Doppler findings in head and neck tumours. *Ultrasound Med Biol* 1997;23:1311–1317.
- Dragoni F, Cartoni C, Pescarmona E, et al. The role of high resolution pulsed and colour Doppler ultrasound in the differential diagnosis of benign and malignant lymphadenopathy. *Cancer* 1999;85:2485–2490.
- Eichhorn T, Schroeder HG, Glanz H, Schwerk WB. Histologically controlled comparison of palpation and sonography in the diagnosis of cervical lymph node metastases. *Laryngol Rhinol Otol* 1987;66:266–274.
- Ellegala DB, Leong-Poi H, Carpenter JE, et al. Imaging tumour angiogenesis with contrast ultrasound and microbubbles targeted to $\alpha_v\beta_3$. *Circulation* 2003;108:336–341.
- Giancarlo T, Palmieri A, Giacomarra V, Russolo M. Pre-operative evaluation of cervical adenopathies in tumours of the upper aerodigestive tract. *Anticancer Res* 1998;18:2805–2809.
- Giovagnorio F, Caiazzo R, Avitto A. Evaluation of vascular patterns of cervical lymph nodes with power Doppler sonography. *J Clin Ultrasound* 1997;25:71–76.
- Hamper UM, DeJong MR, Caskey CI, Sheth S. Power Doppler imaging: Clinical experience and correlation with colour Doppler US and other imaging modalities. *Radiographics* 1997;17:499–451.
- Ho SS, Metreweli C, Ahuja AT. Does anybody know how we should measure Doppler parameters in lymph nodes? *Clin Radiol* 2001;56:124–126.
- Issing PR, Kettling T, Kempf HG, Heermann R, Lenarz T. Ultrasound evaluation of characteristics of cervical lymph nodes with special reference to colour Doppler ultrasound. A contribution to differentiating reactive from metastatic lymph node involvement in the neck. *Laryngorhinootologie* 1999;77:566–572.
- Maurer J, Willam C, Schroeder R, et al. Evaluation of metastases and reactive lymph nodes in Doppler sonography using an ultrasound contrast enhancer. *Invest Radiol* 1997;32:441–446.
- Moritz JD, Ludwig A, Oestmann JW. Contrast-enhanced colour-coded Doppler sonography for evaluation of enlarged cervical lymph nodes in head and neck tumours. *AJR Am J Roentgenol* 2000;174:1279–1284.
- R Development Core Team. R: A language and environment for statistical computing. R Foundation for Statistical Computing, Vienna, Austria, 2005. Available at: <http://www.R-project.org>
- Rubaltelli L, Khadivi Y, Tregnaghi A, et al. Evaluation of lymph node perfusion using continuous mode harmonic ultrasonography with a second-generation contrast agent. *J Ultrasound Med* 2004;23:829–836.
- Scheipers U, Siebers S, Gottwald F, et al. Sonohistology for the computerized differentiation of parotid gland tumours. *Ultrasound Med Biol* 2005;31:1287–1296.
- Schroder RJ, Maurer J, Hidajat N, et al. Signal-enhanced colour-coded duplex sonography of reactively and metastatically enlarged lymph nodes. *Rofo* 1998;168:57–63.
- Schulte-Altendorneburg G, Demharter J, Linne R, et al. Does ultrasound contrast agent improve the diagnostic value of colour and power Doppler sonography in superficial lymph node enlargement? *Eur J Radiol* 2003;48:252–257.
- Solbiati L, Rizzatto G, Belotti E. High resolution sonography of cervical lymph nodes in head and neck cancer: Criteria for differentiation of reactive versus malignant nodes. *Radiology* 1988;169:113.
- Solbiati L, Osti V, Cova L, Tonolini M. Ultrasound of thyroid, parathyroid glands and neck lymph nodes. *Eur Radiol* 2001;11:2411–2424.
- Som PM. Lymph nodes of the neck. *Radiology* 1987;165:593–600.
- Steinkamp HJ, Maurer J, Cornehl M, et al. Recurrent cervical lymphadenopathy: differential diagnosis with colour-duplex sonography. *Eur Arch Otorhinolaryngol* 1994;251:404–409.

- Steinkamp HJ, Mueffelmann M, Bock JC, et al. Differential diagnosis of lymph node lesions: A semiquantitative approach with colour-Doppler ultrasound. *Br J Radiol* 1998;71:828–833.
- Steinkamp HJ, Wissgott C, Rademaker J, Felix R. Current status of power Doppler and colour-coded Doppler sonography in the differential diagnosis of lymph node lesions. *Eur Radiol* 2002;12:1785–1793.
- Tschammler A, Knitter J, Wittenberg G, Krahe TH, Hahn D. Quantification of lymph node perfusion using colour duplex ultrasonography. *Rofo* 1995;163:203–209.
- Tschammler A, Beer M, Hahn D. Differential diagnosis of lymphadenopathy: Power Doppler vs colour Doppler sonography. *Eur Radiol* 2002;12:1794–1799.
- Valentin L. Gray scale sonography, subjective evaluation of the colour Doppler image and measurement of blood flow velocity for distinguishing benign and malignant tumours of suspected adnexal origin. *Eur J Obst Gynecol Reprod Biol* 1997;72:63–72.
- Van den Brekel MW, Castelijns JA, Snow GB. The size of lymph nodes in the neck on sonograms as a radiologic criterion for metastasis: How reliable is it? *AJNR Am J Neuroradiol* 1998;19:695–700.
- Vassallo P, Wernecke K, Roos N, Peters PE. Differentiation of benign from malignant superficial lymphadenopathy: The role of high-resolution US. *Radiology* 1992;183:215–220.
- Wu CH, Hsu MM, Chang YL, Hsieh FJ. Vascular pathology of malignant cervical lymphadenopathy: Qualitative and quantitative assessment with power Doppler ultrasound. *Cancer* 1998;83:1189–1196.
- Wu CH, Lee MM, Huang KC, et al. A probability prediction rule for malignant cervical lymphadenopathy using sonography. *Head Neck* 2000;22:223–228.
- Ying M, Ahuja A, Brook F. Accuracy of sonographic vascular features in differentiating different causes of cervical lymphadenopathy. *Ultrasound Med Biol* 2004;30:441–447.
- Youden WJ. Index for rating diagnostic tests. *Cancer* 1950;3:32–35.
- Zenk J, Bozzato A, Steinhart H, Greess H, Iro H. Metastatic and inflammatory cervical lymph nodes as analyzed by contrast-enhanced colour-coded Doppler ultrasonography: Quantitative dynamic perfusion patterns and histopathologic correlation. *Ann Otol Rhinol Laryngol* 2005;114:43–47.