

CLINICAL TECHNIQUES AND TECHNOLOGY

New Endoscopic Instruments for Paranasal Sinus Surgery

Klaus Bumm, MD, Jochen Wurm, MD, Christopher Bohr, MD, Johannes Zenk, MD, PhD, and Heinrich Iro, MD, PhD, Erlangen-Nuremberg, Erlangen, Germany

BACKGROUND: Minimally invasive endoscopic and microscopic procedures represent state of the art paranasal sinus surgery techniques in both diagnostic and surgical fields. To combine favorable aspects of both techniques, we evaluated the clinical applicability and effectiveness of multifunctional microendoscopes, providing multiple features to ensure highest accuracy and surveillance when performing crucial steps in paranasal sinus surgery.

METHODS: The study included both anatomic experiments on cadaveric heads and clinical tests on patients undergoing routine paranasal surgery. The systems applicability was evaluated in procedures approaching the frontal and sphenoid sinus. Three different endoscopes, 2 straight and the other 1 with a 90° angle, were tested. They integrate canals for flushing and suction and a working canal for either drilling or obtaining biopsies with a miniaturized forceps. For stereotactic feedback, the applicability in combination with a computer-navigation system was evaluated.

RESULTS: Anatomic tests were performed to optimize illumination and to test drilling features and forceps biopsies. In all cases, the frontal sinus ostium and the sphenoid sinus anterior wall was easily identified and enlarged by drilling under visual and stereotactic control. Continuous suction and irrigation ensured a constant visual surveillance by removing drilling debris and blood. Best suited for multifunctional endoscopic surgery were drill heads with a cylinder shape, for placing bore holes along the Z axis, and spherical drill heads, for refurbishing and enlarging drill holes.

CONCLUSION: These new instruments have proven their applicability in paranasal sinus surgery. Multifunctional endoscopic procedures were deemed best suited for maneuvers requiring highest precision, such as the surgery of the frontal and sphenoid sinus. © 2005 American Academy of Otolaryngology–Head and Neck Surgery Foundation, Inc. All rights reserved.

There is a growing trend toward the use of interventional techniques in endoscopic paranasal sinus surgery. With the ongoing evolution in the field of endoscopy and micro-mechanics, new devices are introduced regularly.^{1,2} A great number of new devices have so far been applied, but none has yet shown to be superior and entirely satisfactory compared with the operative strategies as introduced by Messerklinger³ and Wigand et al.^{4–6} Simmen⁷ introduced a 4-handed endoscopic technique. Draf and Samii⁸ described a microscopic approach and the benefit of drills in paranasal sinus surgery. It enables the surgeon to use both hands for maneuvering variable instruments. Unlike in microscopic sinus surgery, the use of drills in endoscopic surgery has so far been hampered by impaired vision because of a constant flow of water.⁹ Addressing this issue, Iro and Zenk¹⁰ developed a curved frontal sinus endoscope and found it useful for better visualization during sinus surgery. Our experience with the frontal sinus endoscope led to the idea of combining endoscopy with features for instrumental maneuvering. The concept is not new. A micropressure suction-irrigation system for a 1-handed transseptal approach to the pituitary gland already had been introduced by Abe.¹¹ However, its design is set for pituitary gland surgery, and it has no applicability for paranasal sinus surgery.

A multifunctional concept for endoscopic sinus surgery should incorporate not only drills but also miniaturized forceps for obtaining biopsies when needed. Encouraged by our positive experience with the setup for frontal sinus surgery, we also developed a setup for surgery of the sphenoid sinus and possibly the ethmoids. To combine endoscopy with computer navigation, all endoscopes were

From the Department of Otorhinolaryngology–Head and Neck Surgery, Friedrich-Alexander-University Erlangen-Nuremberg, Erlangen, Germany. Supported by the Bayerische Forschungsstiftung [BFS], grant 588/03. Reprint requests: Klaus Bumm, MD, Department of Otorhinolaryngology–

Head and Neck Surgery, Friedrich-Alexander-University Erlangen-Nuremberg, Waldstrasse 1, D-91054, Germany.

E-mail address: klaus.bumm@hno.imed.uni-erlangen.de.




Figure 1 Multifunctional endoscopes: (A) Sinus straight drill 6000-pixel endoscope. (B) Sinus straight drill 30,000-pixel endoscope. (C-E) Modular components consisting of the endoscope shaft with its working canals and the loading module with standardized Luer lock connections. Endoscopic instruments: (1) cylindrical drillhead (4-mm diameter), (2) cylindrical drillhead (2-mm diameter), (3) spherical drillhead (3-mm diameter), and (4) biopsy forceps.

equipped with a referencing tool for stereotactic navigation. The present study evaluates the feasibility, efficacy, and safety of these multifunctional microendoscopes.

MATERIAL AND METHODS

Surgical Instruments

All instruments used in this study are commercially available and certified medical products. Technical specifications are described in brief according to information provided by the manufacturer (Polydiagnost GmbH, Pfaffenhofen, Germany). Working canals are equipped with standardized Luer-lock connections at the proximal end of the handle. The optical systems are glass fibers with a 0° direct view, variable field of view angle, and integrated fiber optical illumination.

Sinus straight drill 6000-pixel endoscope (SSD 6000). The endoscope is an all-in-1 system. It has an overall length of 200 mm and a working length of 120 mm. The endoscope shaft has a 3.6-mm diameter and harbors 4 canals: 1 for the fiber optic, 1 working canal (1.9 mm diameter), and 2 for irrigation and suction (0.6-mm diameter each). The overall diameter of the endoscope shaft is 3.6 mm. The optical system consists of a 6000-pixel fiber optic with 0° direct view. The overall field of view angle is 70°. The illumination depth is more than 3 cm (Fig 1A).

Sinus straight drill 30,000-pixel endoscope (SSD 30,000; Neuroptic). The modular endoscope has an overall length of 226 mm with a working length of 153 mm. The endoscope shaft with a diameter of 5 mm harbors 4 canals: 1 for the fiber optic, 1 working canal for instrument applications (2.25 mm diameter), and 2 irrigation and suction canals (1.1-mm diameter each). The endoscope's optical system has a 30,000-pixel glass fiber with a 0° direct view. The illumination depth is more than 4 cm. The overall field of view angle is 105° (Fig 1B-E).

Sinus curved drill 6000-pixel endoscope (SCD 6,000). The endoscope, like the SSD 6000, is an all-in-1 system. It has the same specifications as the sinus straight drill. The only difference is that its shaft has a 90° angle (Fig 2).

Power source, drill heads, and forceps. Available instruments for all endoscopes include scissors, forceps, electrical drills, laser fibers, and electrodes. We used both cylindrical and spherical-shaped drill heads. For reduced vibrations during drilling procedures, the drill's edge was strutted to fit the endoscope's working canal with a 0.1-mm fetch. All drills were available with different-sized drill heads (Fig 1). For working with the SCD 6000, drills and forceps have a flexible shaft and can be inserted easily in the working canal. The mobile power source delivers variable torque and speeds up to 10,000 rpm. The operator controls the speed either by hand or by a foot-operated switch. Constant flush is ensured by sterile saline irrigation. The rate of flow can be



Figure 2 SCD 6000-pixel endoscope.

adjusted according to the requirements of the surgical field. For reducing extensive weight on the instrument, the drill's engine was not directly mounted on the endoscope. As an interposition, we used a drill extension shaft that connects to the drill's engine and the endoscope.

Computer Navigation

For stereotactic control we used the Brainlab Vector-Vision2 (BrainLAB, Helmstetten, Germany) setup. All endoscopes were tightly connected to a referencing star for optical tracking. The endoscope's tip, either the drill

or forceps, was registered with the computer navigation system, and therefore all endoscope movements are displayed on the navigational system. If required, the endoscopic video can be displayed on the navigation screen (Fig 3).

Patients and Cadaveric Tests

This study was conducted in accordance with the guidelines of the Ethics Committees of the University of Erlangen-Nuremberg. All patients were informed of the possible discomfort and risks of the surgical treatment. Routine paranasal sinus surgery was performed in 10 patients under general anesthesia. Surgical procedures were identical in cadaveric heads and patients. Anatomic tests (Fig 4) were performed on two 5% formaldehyde-fixed cadaveric heads. All specimens are part of the department's anatomic inventory.

The following surgical procedures were performed with all prior mentioned instruments: resection of the sphenoid sinus' anterior wall, opening and enlargement of the frontal sinus ostium, and biopsies of various tissues from the ethmoids and frontal sinus.

Results were rated postoperatively according to the instrument's effectiveness in approaching the surgical site, instrument performance, and illumination. Biopsies were taken from the frontal sinus mucosa and from the ethmoids in 5 cases. For completion after approaching the frontal and

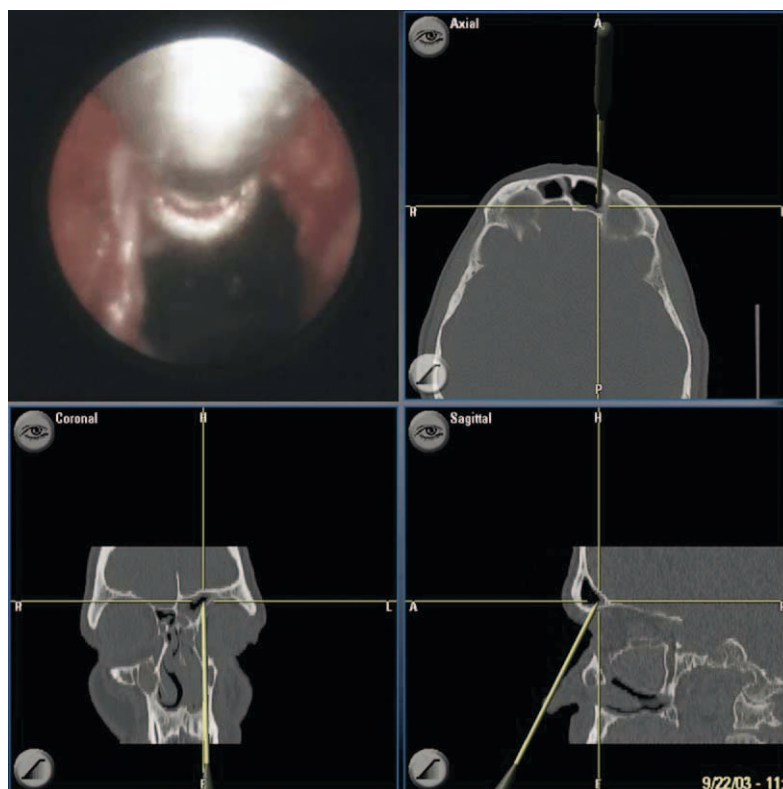


Figure 3 Intraoperative screenshot of the navigation system: Endoscopic picture of the SCD 6000 enlarging the frontal sinus ostium (upper left) with corresponding axial, coronal, and sagittal CT sections.

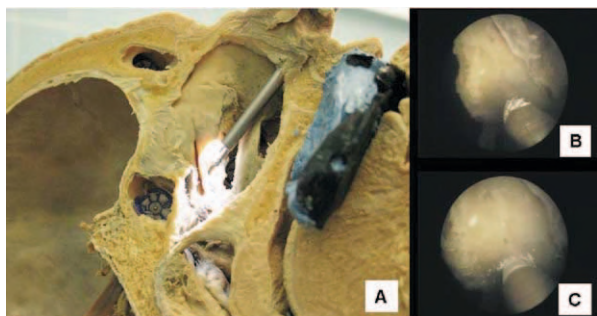


Figure 4 Anatomic experiment with cylindrical drill heads: illumination tests on anatomical paranasal sinus specimen (A). Drilling tests on the sphenoid sinus anterior wall (B, C).

sphenoid sinus, standard surgical techniques were carried out according to Wigand's method.

RESULTS

The intraoperative setup with the connected drill extension shaft and irrigation and suction tubes is assembled before surgery under sterile conditions. The surgeon operates the instrument with 1 hand, leaving the other hand free for supportive tasks such as operating additional suction tips, probes, or specula. There were no differences observed in terms of maneuverability and general performance in anatomic and clinical tests. The main difference was the sometimes-impaired visibility in patients, when blood clots or drilling debris had to be removed from the endoscope by means of irrigation. Results regarding the applicability are reported and discussed together (Table 1).

The SSD 6000 was applied for sphenoidotomies. Bony structures could be removed easily with either cylindrical or spherical drill heads. Compared with the SSD 30,000, this drill exhibited a smaller field of view and reduced overall vision. With a view angle of 70°, visibility was sometimes impaired when using spherical drills because of light reflections on the drill head's surface. Reflections could be lessened by reducing light source intensity at the cost of subsequently decreased surgical site illumination. Because of its smaller diameter, handling and maneuverability within the nasal cavity was smoother with this drill compared with the case of the larger SSD 30,000.

The SSD 30,000 was used for the same surgical procedure as the SSD 6000 with equal applicability. However, it exhibited a much higher illumination and therefore a greater overview of the surgical field. Reflections on the drill head's surface were observed just as with the SSD 6000 endoscope; however, they seemed less troubling in respect to the greater field of view and higher picture resolution.

The curved SCD 6000 for frontal sinus surgery was used for identification and enlargement of the frontal sinus ostium. Initial steps such as uncinectomy and anterior ethmoid sinusotomy were performed according to Wigand's tech-

nique with standard instruments. Insertion of the SCD 6000 endoscope in the nasal cavity was easy without damage to the middle turbinate. Visibility was equal to the SSD 6000 endoscope, and the ostium as target structure was always fully captured by the 70° visibility angle. For opening and enlargement of the frontal ostium, we used spherical drill heads with fine molding burs as well as diamonds for polishing. Because of the rigidity of the endoscopes, smaller bony edges easily can be overcome by either milling or dilation. The passage of the instrument into the frontal sinus was achieved in all cases without problems. Biopsies were obtained with stereotactic guidance. A biopsy location in the frontal sinus was marked in the navigational software before surgery. After opening the frontal sinus, the endoscope was referenced with the navigation system. The forceps was inserted after referencing and could be deployed through the working canal under navigational and visual control (Fig 3). All targeted sites were accessible by this technique.

Drilling features were variable in performance and consistent for the used drill head. Spherical diamond drill heads were used with great success for tasks such as opening and enlarging an ostium. The frontal sinus ostium was best enlarged with a spherical and coarse milling bur because of the relatively hard texture of surrounding bony structures. Cylindrical drill heads as well as diamond-coated spherical drill heads had proven insufficient for this task. Diamond-coated drill heads did not show a sufficient ablation effect. Cylindrical drill heads, originally designed for drilling sharply edged holes, were used for initial penetration of the sphenoid sinus anterior wall. When using cylindrical drills, bore holes were sharply edged, and no bony splintering was evident. However, when using coarse milling burs, a rotational drift was observed on plain bony surfaces. Therefore,

Table 1
Instrument performance in paranasal sinus surgery

Drill type and head	Sphenoid sinus	Frontal sinus	Visibility/illumination
SSD 6000			
Cylindrical 2	+++	NP	++
Cylindrical 3	+++	NP	+
Spherical 3	+	NP	++
Spherical 5	+	NP	+
SSD 30,000			
Cylindrical 2	+++	NP	+++
Cylindrical 3	+++	NP	+++
Spherical 3	+	NP	+++
Spherical 5	+	NP	++
SCD 6000			
Cylindrical 2	NP	++	++
Cylindrical 3	NP	++	+
Spherical 3	NP	+++	++
Spherical 5	NP	+++	+

SSD, sinus straight drill; SCD, sinus curved drill; NP, not possible; +, adequate; ++, good; +++, excellent.

sufficient pressure had to be applied to ensure adequate drill grip with minimal rotational drift. Once the sphenoid sinus was punctured and had been explored endoscopically, the bore hole was best enlarged by using spherical diamond-coated drill heads, resulting in a complete sphenoidotomy.

On both anatomic as well as clinical tests, the ethmoids proved to be not the ideal field of application for these instruments. When approaching the frontal and sphenoid sinus, only minimal volumes had to be ablated. The necessary time to remove all bony septa and possibly polyps by means of either drilling or forceps was disproportionate to possible benefits. However, obtaining biopsies within the ethmoids with either the SSD 6000 or SSD 30,000 was very well possible and highly accurate in all cases.

Additional feedback was provided by the navigation system. Because of insufficient real-time feedback when running the video signal through the navigation system, we chose to view the endoscopic picture not in the upper left video box of the navigation screen but rather on an external monitor. All instruments were registered and navigated with standard clamps that come with the navigation system. Registration was easy and never took longer than 1 minute at maximum. Observed accuracies were identical to standards in paranasal sinus surgery.

DISCUSSION

There has been much advancement in the field of paranasal sinus surgery over the past decades, and by now endoscopic and microscopic sinus surgery are considered routine in the treatment of chronic sinusitis.¹² When performing sinus surgery, the surgeon operates under visual control either by using the endoscopes ocular or a connected video screen.¹³ By using different-degree endoscopes, a direct view at most places within the surgical field is ensured. However, some sites, such as the frontal sinus and lower parts of the maxillary sinus, are not even visually accessible with standard endoscopic procedures. With the introduction of a specialized 90° endoscope, a direct view into the frontal sinus was accomplished.¹⁰ Endoscopic operating techniques vary from institution to institution; however, they all share the aspect of a 2-handed approach, in which the surgeon operates with 1 hand while ensuring visual surveillance by maneuvering the endoscope with his other hand. The potential benefit of having both hands available for manipulating tasks already was addressed by Simmen.⁷ He introduced a 4-handed endoscopic technique, in which an assistant operates the endoscopic camera while the surgeon uses both hands for maneuvering his instruments. Despite the potential monetary issues involved in having 2 persons on a surgical site, the technique emphasizes the benefit of using both hands for manipulating tasks.

In contrast to endoscopic sinus surgery, microscopic approaches do not allow a complete visual surveillance of the entire paranasal sinus system. However, when applicable, it allows the surgeon to use both hands for manipulating tasks.

The need for highly precise maneuvers in terms of possible complications is most evident when operating on the frontal and sphenoid sinus.¹⁴⁻¹⁶ Most difficulties for the inexperienced surgeon have been observed when approaching these structures.¹⁷ The wide range of surgical options pinpoint the need for techniques using today's possibilities in terms of maximum surveillance and highest possible accuracy.^{12,18,19} Even though all components of our system already existed before this study, the combined application and evaluation so far has not been made and is addressed in the present study.

According to the presented investigation, there are some prerequisites for using multifunctional endoscopy for paranasal sinuses in terms of the applicable operating site. Each endoscope revealed shortcomings in certain aspects of a complete paranasal sinus operation. Straight-endoscopic instruments, like the SSD 30,000 and SSD 6000, were perfectly fit for sphenoid sinus surgery and biopsies within the ethmoids but could not be used for frontal sinus surgery. Accordingly, the curved SCD 6000 was perfectly fit for frontal sinus surgery but not for a sphenoidotomy. However, it was fit for obtaining biopsies from the lower compartments of the maxillary sinus.

In terms of illumination and visibility, cylindrical drills were superior to spherical drills, and larger-caliber fiber optic endoscopes were superior to lesser caliber devices. Instrument caliber size showed reciprocal characteristics in terms of maneuverability within the paranasal sinuses. As suspected, drill features of spherical and cylindrical heads were entirely different. Whereas cylindrical heads showed great performances in placing accurate bore holes, their milling features were negligible. This was surprising because we had a milling profile placed on the cylinder side. An explanation might be that not enough pressure could be applied for a continuous and even milling procedure. Performing biopsies with the SCD 6000 endoscope under stereotactic control was easily done. The guided approach to lateral recesses in the frontal sinus especially was possible. The only areas not easily accessible with this technique were the bottom of the frontal sinus and very high uprising frontal sinus recesses.

The convenience when using these instruments in combination with a computer navigation system is obvious. Navigated biopsies in all portions of the frontal sinus recesses were carried out. This feature is of special interest when extensive tumor spread has to be evaluated. As for applications in cases with nasal polyps, experiments evaluating the combination of multifunctional endoscopy with microdebridors (shavers) currently are underway.

CONCLUSION

We developed a setup of new endoscopic instruments that combine favorable aspects of standard techniques for

paranasal sinus surgery. Of all steps in paranasal sinus surgery, only some can be seen as a proper field of application. Among suited procedures are the fenestration of the frontal sinus and the resection of the sphenoid sinus' anterior wall. According to our results, the system improved intraoperative accuracy and now routinely is used at our institution.

REFERENCES

1. Christmas Jr DA, Krouse JH. Powered instrumentation in functional endoscopic sinus surgery. I: Surgical technique. *Ear Nose Throat J* 1996;75:33–6, 39–40.
2. Grevers G. A new surgical system for endoscopic paranasal sinus surgery. *Laryngorhinootologie* 1995;74:266–8.
3. Messerklinger W. Diagnosis and endoscopic surgery of the nose and its adjoining structures. *Acta Otorhinolaryngol Belg* 1980;34:170–6.
4. Wigand ME, Steiner W, Jaumann MP. Endonasal sinus surgery with endoscopic control: from radical operation to rehabilitation of the mucosa. *Endoscopy* 1978;10:255–60.
5. Wigand ME. Transnasal, endoscopic sinus surgery for chronic sinusitis. I. A biomechanical concept of the endonasal mucosa surgery. *HNO* 1981;29:215–21.
6. Wigand ME. A suction irrigation endoscope for surgery of the sinuses and skull base. *HNO* 1981;29:102–3.
7. Simmen D. Progress in endonasal microsurgery of the paranasal sinuses. *Laryngorhinootologie* 2000;79:645–7.
8. Draf W, Samii M. Surgical treatment of malignant tumors of the paranasal sinuses with involvement of the base of the skull. *Strahlenther Onkol* 1989;165:474–7.
9. Chandra RK, Schlosser R, Kennedy DW. Use of the 70-degree diamond burr in the management of complicated frontal sinus disease. *Laryngoscope* 2004;114:188–92.
10. Iro H, Zenk J. A new device for frontal sinus endoscopy: first clinical report. *Otolaryngol Head Neck Surg* 2001;125:613–6.
11. Abe T. New devices for direct transnasal surgery on pituitary adenomas. *Biomed Pharmacother* 2002;56(Suppl 1):171s–7s.
12. Stammberger H. Surgical treatment of nasal polyps: past, present, and future. *Allergy* 1999;54(Suppl 53):7–11.
13. Bera SP, Rao L. Nasal endoscopy in chronic/recurrent sinusitis. *Auris Nasus Larynx* 1997;24:171–7.
14. Friedman M, Landsberg R, Schults RA, Tanyeri H, Caldarelli DD. Frontal sinus surgery: endoscopic technique and preliminary results. *Am J Rhinol* 2000;14:393–403.
15. Sprinzel GM, Menzler A, Eckel HE, et al. Bone density measurements of the paranasal sinuses on plastinated whole-organ sections: anatomic data to prevent complications in endoscopic sinus surgery. *Laryngoscope* 1999;109:400–6.
16. Rauchfuss A. Complications of endonasal surgery of the paranasal sinuses. Special anatomy, pathomechanisms, surgical management. *HNO* 1990;38:309–16.
17. Marks SC. Learning curve in endoscopic sinus surgery. *Otolaryngol Head Neck Surg* 1999;120:215–8.
18. Sugiura N, Ochi K, Komatsuzaki Y, et al. Powered endoscopic marsupialization for recurrent sphenoid sinus mucocele: a case report. *Auris Nasus Larynx* 2003;30(Suppl):S107–10.
19. Dolan RW, Chowdhury K. Diagnosis and treatment of intracranial complications of paranasal sinus infections. *J Oral Maxillofac Surg* 1995;53:1080–7.