

Fat Obliteration in Paranasal Sinuses: A Comparative Magnetic Resonance Imaging and Histopathologic Study

Jannis Constantinidis; Cristopher Bohr; Holger Greess; Thomas Aigner; Johannes Zenk; Emmanuel Prokopakis; Heinrich Iro

Objectives: To assess postoperative changes after fat tissue obliteration of the paranasal sinuses with the use of magnetic resonance imaging (MRI) and correlate the findings with correspondent histology. **Study Design:** By using an animal model with fat obliteration of the maxillary paranasal sinus. **Methods:** We correlated postoperative changes of the fatty tissues by means of histopathologic analysis and MRI. The study group included 15 rabbits undergoing autologous fat tissue obliteration of their maxillary paranasal sinus. After 1 month (n = 5), 3 months (n = 5), and 6 months (n = 5), both MRI and histopathologic evaluations of the fatty tissue status were performed. Contrast enhanced MRI was used to identify vital fat tissue. Subsequently, MRI findings were compared with a correspondent histologic status and proliferative factors such as angio- and osteogenesis and presence of abundant granulocytes, macrophages, and giant cells. **Results:** After a period of 6 months, the obliteration sites in all animals showed vital fat tissues, whereas at 1 month after surgery, vital fat tissue was rarely observed. The microscopic appearance of the obliteration tissue after 1 month was characterized by fat tissue necrosis and distinct tissue reactions including blood vessel dilatation, abundant macrophages, granulocytes, and lymphocytes. MRI after 1 month showed a clear contrast enhancement because of the hyperemia and inflammation reaction. **Conclusion:** Fat tissue transplants used for obliteration of paranasal sinuses are almost completely de-

graded after transplantation and replaced by vital fat tissue over a period of at least 6 months. Contrast enhanced MRI is a well-suited technique for follow-up imaging and assessing the transplant vascularization and tissue remodeling status. **Key Words:** Fat obliteration, bony cavity, paranasal sinus.

INTRODUCTION

The performance of autologous fat transplants in augmentation of head and neck soft tissue defects has been previously described.¹ Little is known about the histologic performance of fat tissue after obliteration of bony cavities such as the paranasal sinuses.²

The obliteration of paranasal sinuses with fat tissue is an often-performed technique in treatment of chronic frontal sinusitis.³⁻⁶ In some cases, however, severe postoperative pain and paresthesia are observed. To date, these complications are still a challenging dilemma in terms of diagnosis and treatment. Computer tomographic (CT) imaging is a well-documented technique to assess bony cavity structures and the tissue obliteration extent. However, fatty tissues in CT imaging are highly hypodense and can easily be mistaken for air. In the past, density measurements were often falsified because of a partial volume effect, therefore hampering adequate obliteration status assessments.⁷ When using T1 magnetic resonance imaging (MRI) and multiplanar reconstruction, this partial volume effect can be minimized. Fat tissue suppression features in most MRIs enable a good tissue evaluation⁸ but allow no differentiation between vital and necrotic fat, neither mucocele recurrences nor necrotic oil cysts.⁹ Because no comparative data exist that links MRI findings with correspondent microscopic histology, us of MRIs in assessing postoperative obliteration tissue status has to be viewed with reservation. This study aims to distinguish the fat tissue dynamics after bony cavity obliteration, such as a paranasal sinus, by means of histopathologic and MRI techniques.

From the Department of Otorhinolaryngology (J.C., E.P.), Aristotle University, Thessaloniki, Greece; the Department of Otorhinolaryngology (C.B., J.Z., H.I.), University of Erlangen-Nuremberg, Germany; the Institute of Diagnostic Radiology (H.G.), University of Erlangen-Nuremberg, Germany; and the Department of Pathology (T.A.), University of Erlangen-Nuremberg, Germany.

Jannis Constantinidis and Cristopher Bohr contributed equally to this manuscript.

Send Correspondence to Dr. Jannis Constantinidis, Department of Otorhinolaryngology—Head and Neck Surgery, Aristotle University of Thessaloniki, 54 006 Thessaloniki, Greece. E-mail address: janconst@otenet.gr

MATERIALS AND METHODS

An Animal Model

All animal experiments were performed with internal review board and ethics committee approval. Before surgery, animals were put under general anesthesia with intramuscular Ketamine (50 mg/kg) and Xylazine (4 mg/kg) injections.

The rabbits paranasal sinus system is comparable with humans', although its maxillary sinus is divided by two bony septa in three compartments.¹⁰ The study group consisted of 15 rabbits (3.1–3.5 kg) undergoing paranasal maxillary sinus obliteration using autologous abdominal fat tissue. Surgery was performed in all cases to the left maxillary sinus, whereas the right sinus was used as internal control. In all subjects, the right maxillary sinus was not opened, and it was used as control for the MRI study. Osteoplastic flap procedures were performed in all subjects. All mucosa was removed, and the bony internal table was abraded by microscopic control (Fig. 1). The upper compartment of the maxillary sinus was obliterated with abdominal fat tissue separated from the remaining bony cavity and paranasal sinus system by a galea periosteum free graft.

MRI Examination

After a postoperative period of 1, 3, and 6 months, all animals received MRI scans of the head. After MRI, one group of animals was killed while its paranasal sinus system in toto removed and histologically examined.

MRI was performed on a 1.5 Tesla scanner (Gyrosan ACS NT Phillips Hamburg, Germany, Magnetom Symphony, Siemens Medical, Erlangen, Germany). All animals were put under general anesthesia for MRI with the above-mentioned technique. Images were obtained in T1 spin-echo sequence with and without dynamic contrast enhancement, as well as T2 turbo spin-echo and T2 turbo-fast spin-echo fat tissue suppres-

sion technique. Contrast enhancement was performed with 0.2 mL/kg gadolinium-DTPA (Magnevist, Schering, Berlin, Germany) administered intravenously into the rabbits ear vein. Eight contrast enhancement measurements were taken, each for 10 seconds. A marked region of interest was determined for measuring the intensity versus time graph gadolinium-DTPA enhancement parameters. The following parameters were evaluated:

- T1 sequence with contrast enhancement: gadolinium-DTPA uptake (yes/no);
- T2 sequence: signal intensity of obliteration fat: (high signal, intermediate signal, low signal);
- Gadolinium-DTPA dynamic contrast studies in regions of interest: (intensity vs. time graph) time of signal increase, maximum signal, signal decrease.

Histopathologic Examination

For histopathologic examination, all animals were first anesthetized and subsequently killed by a lethal intrapulmonary T61 injection. An entire specimen block containing the bony paranasal sinuses was removed, fixed in 5% formaldehyde according to standard protocols, and embedded in paraffin. Sections of 6 μ m thick were stained in hematoxylin-eosin and Elastika-van-Gieson according to standard histologic protocols. A chloracetate-esterase reaction was used for identifying polymorphic nucleated granulocytes (Table I).

RESULTS

T1 sequence MRIs after administering gadolinium-DTPA showed clear and uniform patterns of contrast enhancement in all examinations after 1, 3, and 6 months. One month after surgery, all specimens showed a homog-

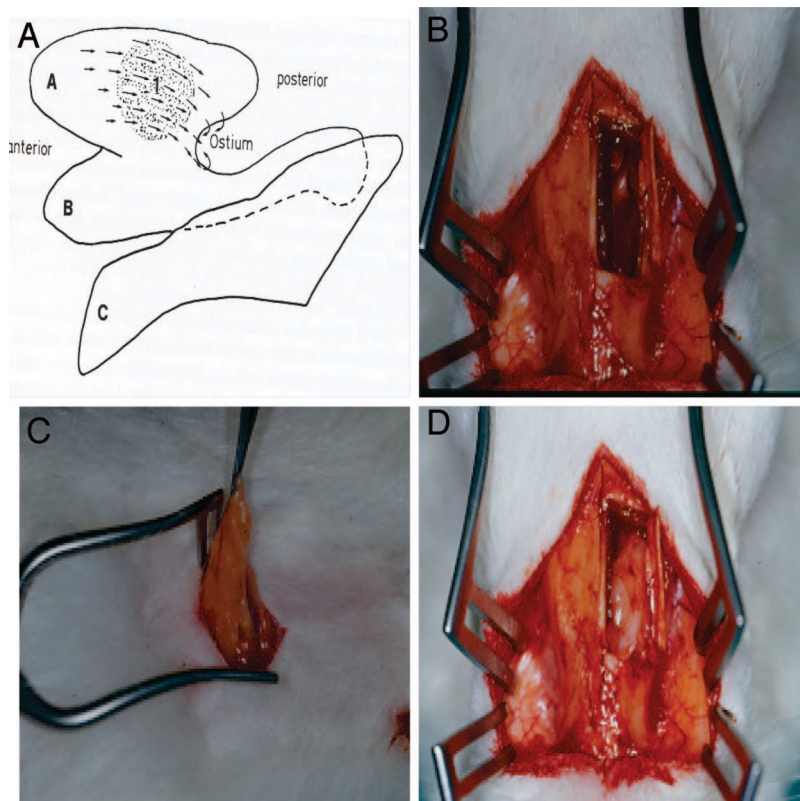


Fig. 1. Fat obliteration of a rabbit's left maxillary sinus. (A) Graphic of a rabbit's maxillary sinus with three compartments (A, B, C within graphic). (B) Osteoplastic surgical approach. (C) Abdominal fat harvesting. (D) Obliteration after mucosa removal.

TABLE I.
Overview of Results from Microscopic Evaluation after Obliteration (n = 15 maxillary sinuses).

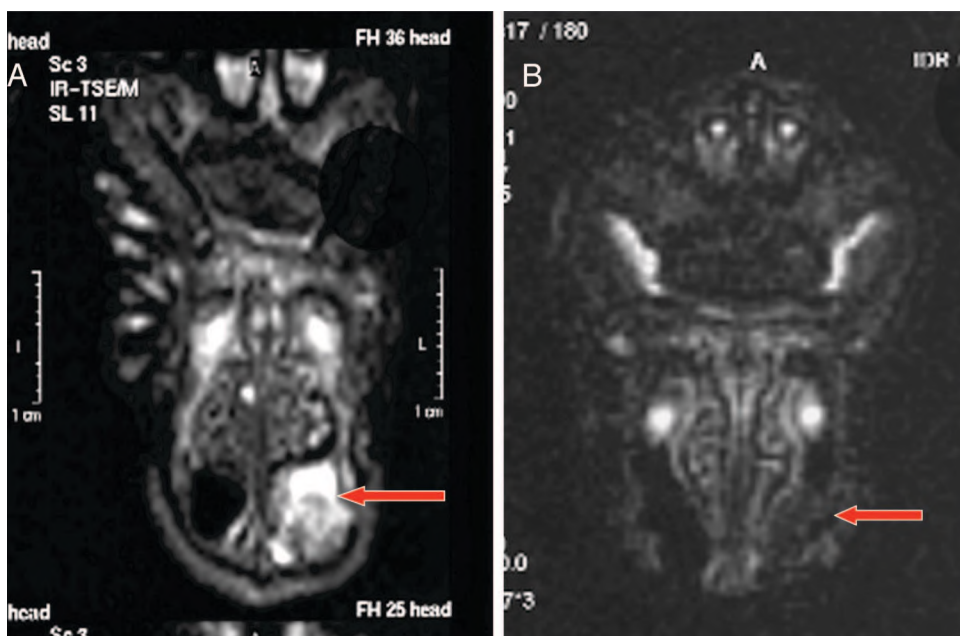
Animals/Time after Obliteration	Fat Absorption	Vessels	Macrophages	Lymphocytes	Giant Cells	Granulocytes	Fibrous Tissue	New Fat	Bone Formation
A1/1M	++	+++	+++	++	++	++	++	-	-
A2/1M	+++	+++	++	++	++	+	++	-	-
A3/1M	+++	+++	+++	++	++	+	++	-	-
A4/1M	+++	+++	++	++	++	+	++	+	+
A5/1M	++	+++	++	++	++	+	++	+	+(+)
A6/3M	+	++	+(+)	-	+	-	+(+)	++	++
A7/3M	+	++	++	(+)	+	-	++	++	+
A8/3M	++	++	+(+)	(+)	+	-	+(+)	++	+
A9/3M	++	++	+(+)	-	+(+)	-	+(+)	+(+)	+
A10/3M	+	++	+(+)	-	+	-	+(+)	++	+
A11/6M	-	+	(+)	-	-	-	+	+++	+
A12/6M	-(+)	+(+)	+	-	+	-	(+)	++(+)	++
A13/6M	+	+(+)	-	(+)	-	-	+	++(+)	+
A14/6M	-	+	(+)	-	(+)	-	+(+)	++	+(+)
A15/6M	-	+(+)	+(+)	-	+	-	+	+++	++

Histologic assessment of the vessels: + = normal, +(+) = slightly increased, ++ = increased, +++ = very increased.
Cells' number (macrophages, lymphocytes, giant cells, granulocytes): - = absent, (+) = increased, + = focal, +(+) = focal increased, ++ = multifocal, +++ = diffuse.
Fibrous tissue, fat absorption, new fat, bone formation: - = absent, (+) = <5%, + = 5-20%, +(+) = 20-40%, ++ = 40-60%, ++(+) = 60-80%, +++ = >80%.
A = animal, M = month after surgery.

enous and strong signal enhancement in T1-weighted images at the obliteration site. Three months after surgery, the signal becomes inhomogeneous with clear low-signal areas, indicating resorption and remodeling activity. Six months after surgery, all specimens exhibited a rather uniformly weak signal pattern at the obliteration sites (Fig. 2). The nonobliterating sinus was always normal in MRI after 1, 3, and 6 months, respectively.

Dynamic contrast perfusion analysis showed in all cases a steep incline in perfusion after 5 to 9 seconds, with a subsequent plateau phase. The incline parameters varied when compared with the time after surgery. The group of animals killed 1 month after obliteration had a median signal increase of 449 (range 430 - 499) units, the group killed 3 months after obliteration had a median incline parameter of 401 (range 338 - 541) units, and the group

Fig. 2. Magnetic resonance image (T2-fat suppression sequence) after obliteration shows necrotic fat tissue as white areas after 1 month and vital fat tissue as black areas after 6 months. (A) One month postoperatively. (B) Six months postoperatively.



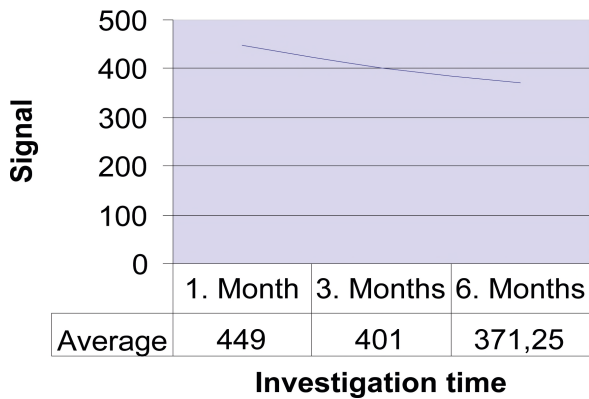


Fig. 3. Magnetic resonance image contrast enhanced signal parameters over time.

killed 6 months after obliteration had a median signal increase of 371 (range 353 - 391) units (Figs. 3 and 4).

Already, 1 month after obliteration, microscopic analysis revealed no residual vital fat tissue. The obliterated sinus was mostly filled with extensive fatty tissue necrosis areas and populated with giant cells as well as foam cells. Interestingly, some areas were also populated with infiltrations of clustered neutrophil granulocytes. The presence of granulocytes was confirmed in all cases by additional chloracetate-esterase-reaction staining (Table I) (Fig. 5). In a more diffuse distribution pattern, small clusters of lymphocytes were also observed. Although most of the obliteration tissue consisted of necrosis, a few areas already exhibited vital fat tissue next to granulation tissue with a high microvessel density. On the peripheral areas, where fat tissue was in contact with the bony internal table, clear clusters with ongoing osteoblastic re-

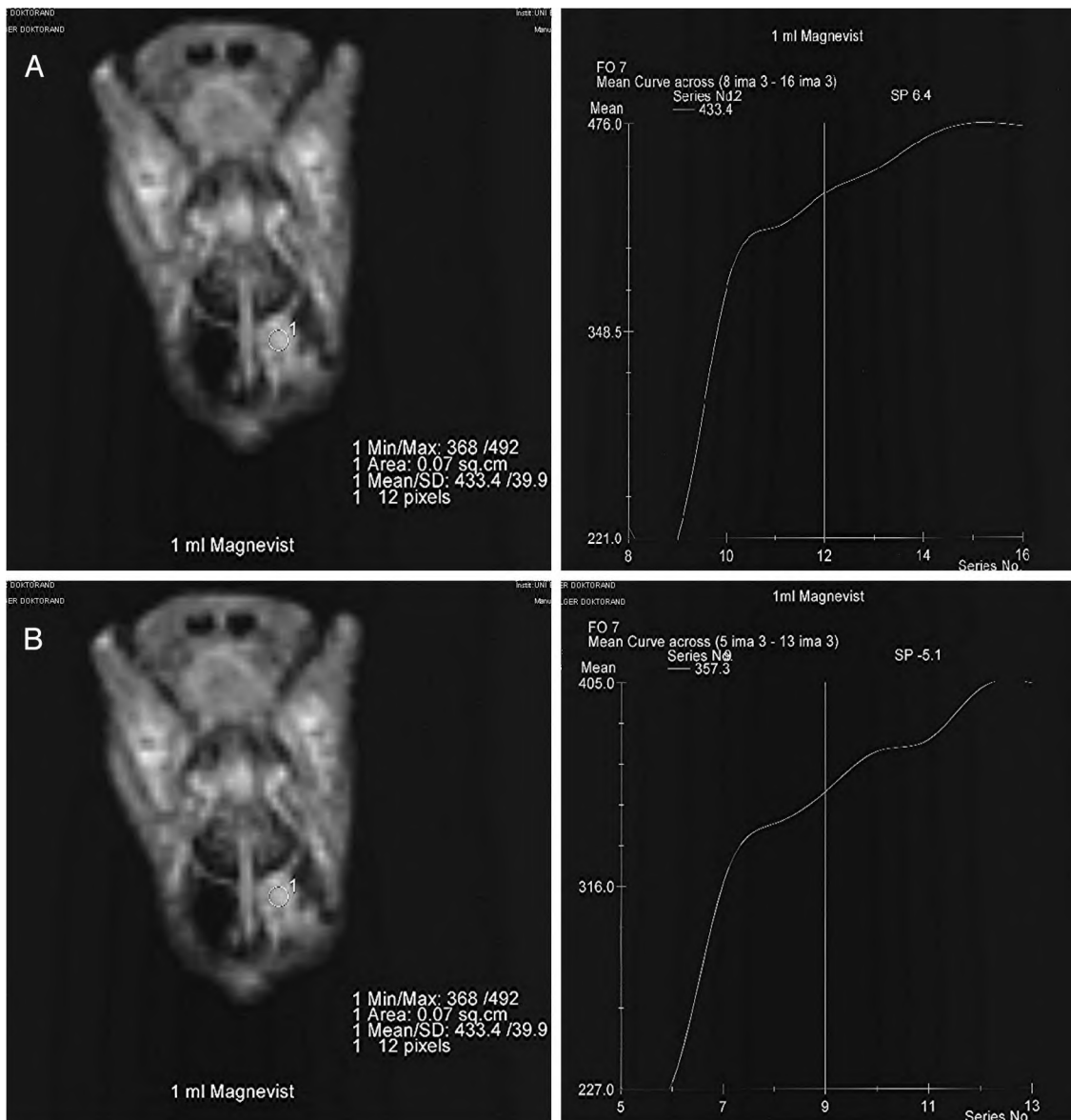


Fig. 4. Perfusion graph after 1 (A) and 6 (B) months.

modeling activity were noticed. After a period of 3 months, the number of areas with postnecrotic fat resorption were scarce and replaced by emerging areas of fat tissue synthesis. Almost no granulocyte or lymphocyte clusters were found and were associated with marked decrease of the overall blood vessel density when compared with microscopic findings 1 month after obliteration. Obliteration sites 6 months after surgery showed close to zero postnecrotic fat-resorption areas, and the microscopic picture was dominated by ripe fat tissue and newly built lamellar bone at the bony cavity walls (Fig. 6). At this point, vital fat tissue constitutes for 70% to 90% of volume of the obliterated site, with fibroses tissue and newly built bone in 10% to 30%. No mucoceles were observed.

DISCUSSION

Independently of the transplantation site, fat grafts have a common denominator, which is its unpredictability. Its easiness to handle and limited tissue reaction make it an appealing choice for the surgeon. However, its long-term fate is almost always impossible to predict. Shortly after transplantation, necrotic cells are absorbed, replaced by granulation tissue, and later transformed into connective tissue and oil cyst.¹

Peer¹¹ described the biologic process and fate of free fat transplants in the abdominal wall. He mentioned that fat tissue is absorbed to a varying extent and replaced by connective tissue. The extent to which fat is replaced by connective tissue was dependent on the extent of trauma to the fat tissue. The more stress is applied to the transplant, the more connective tissue replacement was observed, whereas postoperative infections could result in a total loss of the transplant. Smahel¹² published his experience and observations of free fat transplants from animal models. In rats, he transplanted abdominal fat subcutaneously to their backs. He showed that fat-tissue high metabolic activity and revascularization was partial in all

cases. In parts of the transplant with no vascular supply, he observed the emergence of oil cysts and necroses. Furthermore, the fat tissue initiated a host-versus-graft reaction with macrophageal phagocytosis rather than plain resorption. He concluded that the transplants fate depends on the transplantation site's vascularization capability.

Our results indicate the following three phases of fat tissue reaction after transplantation: 1) necrotic phase, 2) remodeling phase, and 3) tissue neogenesis. Right after transplantation, the tissue is subject to ischemia with subsequent insufficient nutritional feed. As shown previously, postoperative ischemia will lead to the increased expression of angiogenic factors, such as vascular endothelial growth factor¹³ and promote vascular growth from the outer rim of the bony walls. It is suggested that the postoperative ischemia is at its maximum after the first 3 days after transplantation. Immediately after ischemia, necrotic isles will appear throughout the transplant, resulting in a noticeable volume loss.¹⁴ Fat tissue located on the transplant's outer rim might survive the initial remodeling phase and be subjected to apoptosis at a later point of time, up to 1 month after transplantation. It is well known that several factors such as cytokines, insulin, corticoids, and high temperature promote apoptosis of fat tissue.¹⁵ Increased apoptosis in transplants can therefore be explained as a cytokine-mediated process after postoperative inflammation and pronounced foreign body reaction.

But how does fat neogenesis take place? This issue is controversially discussed, and many explanation attempts have been made. The most recognized thesis proposes a "cell survival theory."¹ It implies the survival of progenitor cells that, after neovascularization, proliferate and build a cornerstone population of new adipocytes. A downside of this theory is that the ischemia period (multiple days) between transplantation and neovascularization is far

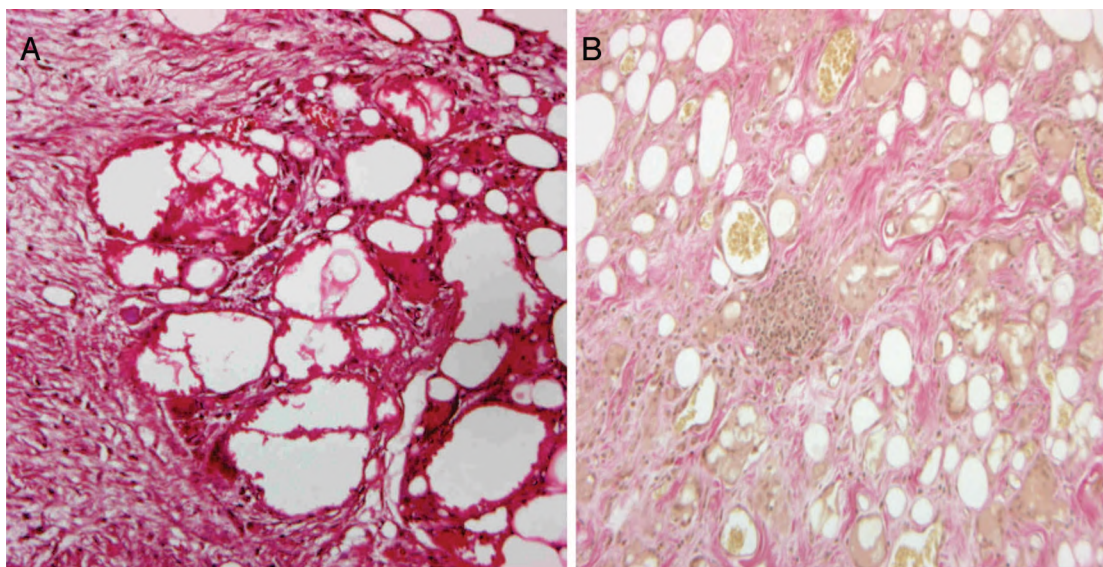


Fig. 5. Microscopic images of an obliterated maxillary sinus after 1 month. (A) Extensive fatty tissue necrosis. (B) Infiltration with macrophages, granulocytes, and giant cells.

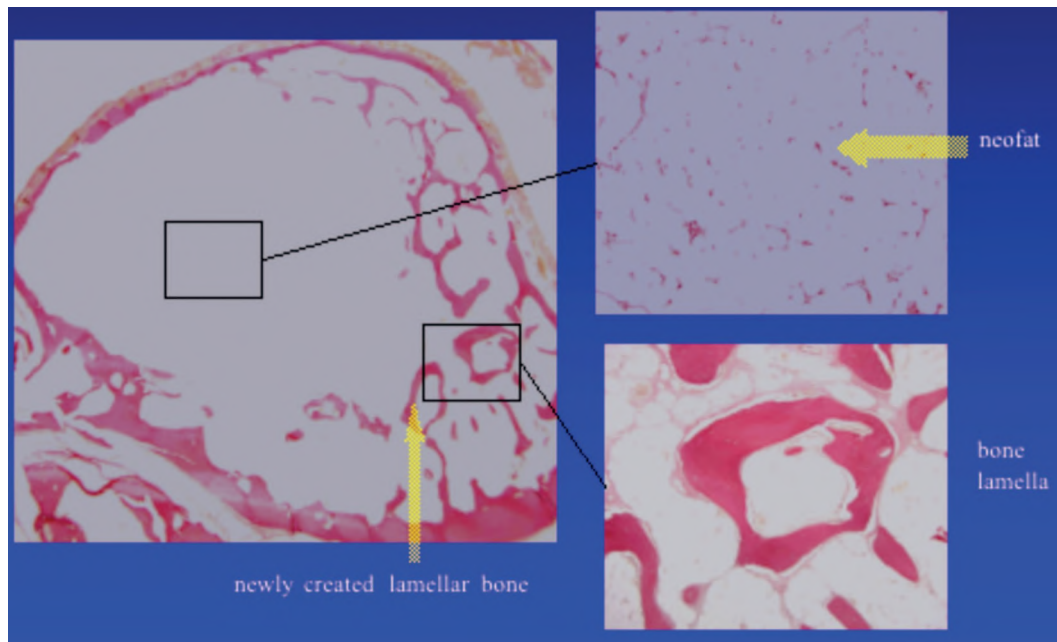


Fig. 6. Microscopic image of an obliterated maxillary sinus after 6 months shows vital fat tissue (thick arrow) and new created lamellar bone (arrow).

longer than the ischemia tolerance (a few hours) of fat tissue. Therefore, we propose an alternative theory of tissue neogenesis in free fat transplants in favor of pluripotent stem cells originating from the ingrowing granulation tissue. It has been clearly shown that differentiation from mesenchymal stem cells to adipocytes is possible.¹⁶

In contrast with the cell survival theory, our theory allows an explanation for the emergence of new adipocytes in the area of complete necrosis. As far as the observed loss of volume after transplantation is concerned, previous studies reported a 20% to 80% decrease in volume after free fat transplantation.¹⁴ In our study, 6 months after transplantation, we observed a 1% to 30% decrease in volume when compared with the initial size. We concur with previous studies that the surgical technique as well as transplant handling plays the major role in transplant tissue survival. Of equal importance was the prerequisite for a sufficient blood supply.¹⁷ The removal of the internal bony table before transplantation has to be viewed not in terms of a prolonged transplant life span but rather in terms of an improved source for angiogenesis. For the internal table removal, we used a Rosen drill and not a diamond drill because the latter might clog small bony canals with drilling debris and therefore seal them, subsequently inhibiting sufficient vascularization.⁴

MRI has proven to be a reliable technique for assessing transplant tissues. Vital fat tissue is depicted as hyperdense in T1 sequences and hypodense when using a fat suppression algorithm.^{8,9,18} Scar or granulation tissue after necrosis are easily detected in T1 sequences as gray or dark areas. T2 sequences with fat suppression features 1 month after transplantation show a homogenous and hyperdense signal, representing an almost complete necrosis and the beginning of postinflammatory tissue remodel-

ing. Our results are in concordance with observations made by Loevner and colleagues,¹⁹ who followed up on 13 patients with fat obliteration of the frontal sinus. They interpreted hyperdense signals in T2 fat suppression imaging as inflammation and granulation tissue. The rather inhomogeneous MRI pattern 3 months after surgery is related to the beginning of fat neogenesis. Six months after surgery, a hyperintense signal can be seen throughout the transplant.

Contrast MRI results indicate a decrease in the maximum plateau values. This correlates with microscopic findings in terms of overall microvessel density. One month after surgery, microscopic images showed high microvessel density caused by hyperemic granulation tissue. With increasing fat tissue neogenesis, the hyperemic pattern is increasingly reduced and after 6 months, and parameters of a normal fat tissue perfusion pattern were observed. Contrast MRI is therefore a valuable tool in assessing transplant vascularization and allows an indirect quantification of fat tissue neogenesis.

BIBLIOGRAPHY

1. Billings E, May J. Historical review and present status of free graft autotransplantation in plastic and reconstructive surgery. *Plast Reconstr Surg* 1989;83:368–381.
2. Montgomery WW, Pierce DL. Anterior osteoplastic fat obliteration for frontal sinus: clinical and animal studies. *Trans Am Acad Ophthalmol Otolaryngol* 1963;67:46–57.
3. Rohrich RJ, Mickel TJ. Frontal sinus obliteration: in search of the ideal autogenous material. *Plast Reconstr Surg* 1995; 95:580–585.
4. Weber R, Draf W, Constantinidis J. Osteoplastic macroscopic and microscopic frontal sinus surgery. *Am J Rhinol* 1994; 8:247–251.
5. Weber R, Draf W, Keerl R, Constantinidis J. Aspects of frontal sinus surgery. III. Indications and results of osteoplas-

- tic frontal sinus surgery. *HNO* 1995;43:414–420.
6. Mendians AE, Marks SC. Outcome of frontal sinus obliteration. *Laryngoscope* 1999;109:1495–1498.
 7. Catalano PJ, Lawson W, Som P, Biller HF. Radiographic evaluation and diagnosis of the failed frontal osteoplastic flap with fat obliteration. *Otolaryngol Head Neck Surg* 1991;104:225–234.
 8. Tien RD. Fat suppression MR-imaging in neuroradiology. *AJR* 1992;158:369–379.
 9. Weber R, Draf W, Keerl R, et al. Osteoplastic frontal sinus surgery with fat obliteration: technique and long-term results using magnetic resonance imaging in 82 operations. *Laryngoscope* 2000;110:1037–1044.
 10. Kumlien J, Schiratzki H. The vascular arrangement of the sinus mucosa. A study in rabbits. *Acta Otolaryngol* 1985;99:122–132.
 11. Peer LA. Transplantation of fat. In: *Reconstructive Plastic Surgery*. Philadelphia: WB Saunders, 1977:251–261.
 12. Smahel J. Experimental implantation of adipose tissue fragments. *Br J Plast Surg* 1989;42:207–211.
 13. Hausman GJ, Richardson RL. Adipose tissue angiogenesis. *J Anim Sci* 2004;82:925–934.
 14. Nishimura Toshiro, Hashimoto Harumi, Nakanishi Isao, Furukawa Mitsuru. Microvascular angiogenesis and apoptosis in the survival of free fat grafts. *Laryngoscope* 2000;110:1333–1338.
 15. Prins JB, Walker NI, Winterford CM, Cameron DP. Apoptosis of human adipocytes in vitro. *Biochem Biophys Res Commun* 1994;201:500–504.
 16. Pittinger MF, Mackay AM. Multilineage potential of adult human mesenchymal stem cells. *Science* 1999;284:143–147.
 17. Schiffman MA, Mirrafati S. Fat transfer techniques: the effect of harvest and transfer methods on adipocyte viability and review of the literature. *Dermatol Surg* 2001;27:819–826.
 18. Keerl R, Weber R, Kahle G, Draf W, et al. Magnetic resonance imaging after frontal sinus surgery with fat obliteration. *J Laryngol Otol* 1995;109:1115–1119.
 19. Loevner LA, Yousem DM, Lanza DC, Kennedy DW. MR evaluation of frontal sinus osteoplastic flaps with autogenous fat grafts. *AJNR* 1995;16:1721–1726.