

# METASTATIC AND INFLAMMATORY CERVICAL LYMPH NODES AS ANALYZED BY CONTRAST-ENHANCED COLOR-CODED DOPPLER ULTRASONOGRAPHY: QUANTITATIVE DYNAMIC PERFUSION PATTERNS AND HISTOPATHOLOGIC CORRELATION

JOHANNES ZENK, MD

ALESSANDRO BOZZATO, MD

HOLGER GREESS, MD

HELMUT STEINHART, MD

HEINRICH IRO, MD

ERLANGEN, GERMANY

Use of contrast-enhanced color-coded Doppler (ultra)sonography (CCDS) in evaluating enlarged lymph nodes has been subject to numerous attempts to define criteria for differentiation between benign and malignant lesions. Evaluation of dynamic perfusion patterns with contrast-enhanced CCDS in cervical lymph nodes offers new possibilities of differential diagnosis. A total of 28 patients with clinically enlarged lymph nodes were included in this study. Contrast-enhanced CCDS was performed on each patient. The color signals from nodes <15 mm in diameter were analyzed with a specialized computer program. Each node was later examined through immunohistochemical staining. Vascularization as shown by unenhanced CCDS was significantly greater in metastatic lymph nodes than in reactively enlarged lymph nodes (8.66% versus 2.81%;  $p = .01$ ). The maximum vascularization area after contrast injection did not show any significant change (26.61% versus 28.63%;  $p = .75$ ). Comparison of values obtained before and after contrast enhancement showed the largest relative increase in vascularization in inflammatory lymph nodes, from a factor of 19.55 to a factor of 10.03 ( $p = .025$ ). Dynamic values such as contrast enhancement, behavior of dynamic values referred to time, and the evaluated vascularized area did not show any significant difference. The metastatic lymph nodes (5.46 versus 3.33;  $p = .007$ ) predominantly consisted of large blood vessels. The increased vascularization in the unenhanced CCDS examination of metastatic lymph nodes seems to be associated with the increased number of large blood vessels. An increased vessel density, due to a greater number of total vessels, is related to an inflammatory process. Color Doppler mapping has been proven to depict useful aspects distinguishing benign from malignant lymph nodes of the neck; however, a definitive differentiation between lymph nodes involved with malignancy and inflammatory changes remains difficult.

**KEY WORDS** — diagnosis, head and neck, tumor, ultrasonography.

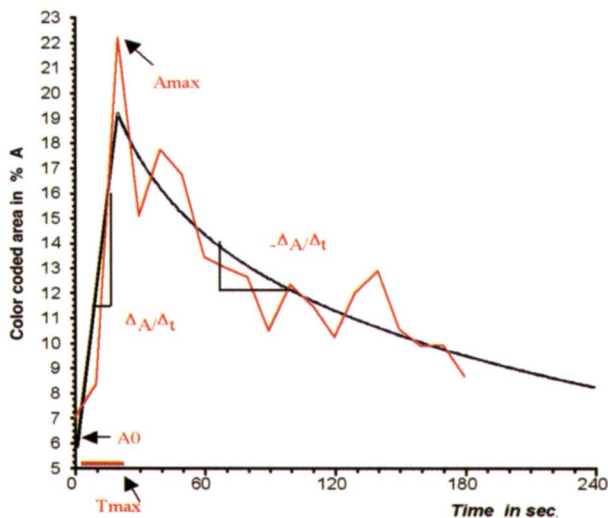
## INTRODUCTION

Assessing enlarged cervical lymphatic nodes in pretherapeutic cancer staging and routine follow-up examinations after head and neck surgery poses a daily challenge for the ultrasound examiner. Not restricted to the location of the primary tumor, the diagnosis of ipsilateral metastases reduces the statistical 5-year survival rate to 50%, and in cases of bilateral cervical metastases, the rate is as little as 25%.<sup>1</sup> In combination with subtle clinical examination, modern high-resolution B-scan and color-coded Doppler (ultra)sonography (CCDS) is reported to reach sensitivity and specificity as high as 90%, depending on the study design and operator experience.<sup>2-6</sup> So far, the common features of B-scan differentiation are shape, transverse-to-longitudinal ratio, infiltration of adjacent tissue, inhomogeneous echogenicity, and intranodal necrosis.<sup>2,7-12</sup> In lymph nodes with a diameter of less than 15 mm, the diagnostic reliability decreases, as the aforementioned characteristics are less frequently seen.<sup>13,14</sup> The use of CCDS to examine

structure, intensity, and localization of feeding vessels is reported to provide additional helpful indicators in the determination of suspected malignancy.<sup>2-4,15-17</sup> Along with the introduction of novel ultrasound contrast media, this technique already provides a high level of confidence in judging vascular patterns that are supposed to indicate malignant growth and thus facilitate differential diagnosis, especially in larger lymph nodes.<sup>17-19</sup> This assumption is based on the hypothesis that tumor neoangiogenesis in malignant lymph nodes leads to distinct perfusion patterns and vascular architecture.<sup>18-22</sup> To judge the type and amount of intranodal vasculature remains an individual task. The aim of this prospective study in the differentiation of lymph nodes was, therefore, to evaluate a new parameter: quantitative dynamic perfusion with contrast-enhanced CCDS. Additionally, the ultrasonography results were compared with and verified by standard histologic and immunohistochemical techniques. The displayed technique provides a new quantitative parameter that avoids the

From the Departments of Otorhinolaryngology-Head and Neck Surgery (Zenk, Bozzato, Steinhart, Iro) and Radiology (Greess), University of Erlangen-Nuremberg, Erlangen, Germany.

**CORRESPONDENCE** — Johannes Zenk, MD, Dept of Otorhinolaryngology-Head and Neck Surgery, University of Erlangen-Nuremberg, Waldstrasse 1, D-91054 Erlangen, Germany.



**Fig 1.** A0 — percent contribution of color-coded signal area to calculated entire lymph node area before contrast agent application; Amax — percent contribution of maximum color-coded area after administration of contrast agent; Tmax — period of time lapse in seconds between contrast agent injection and appearance of maximum color Doppler signal area; Amax/A0 — calculated relative enhancement in color-coded area after application of contrast agent, quotient of Amax/A0;  $\Delta A/\Delta t$  — plotted gradient of color-coded signal up to point of inflection (%/s);  $-\Delta A/\Delta t$  — negative gradient of regression curve after Amax (%/s).

need to determine the intranodal vascular pattern, which is a qualitative judgment made by the ultrasound examiner.

#### MATERIALS AND METHODS

We included 28 patients with sonographically assessed lymph nodes with a diameter of less than 15 mm in this study. All subjects were scheduled for extirpation or neck dissection of primary squamous cell carcinoma of the hypopharynx, oropharynx, or supraglottic area (stage T1 to T3). No patient showed signs of acute inflammatory disease of the upper respiratory tract. The patient group consisted of 23 male and 5 female subjects with a mean age of 55.9 years (range, 29 to 77 years). All participating patients gave their written consent. Histologic evaluation classified 15 extirpated enlarged lymph nodes as the result of an inflammatory process and 13 as the result of metastatic transformation originating from squamous cell carcinoma of the head and neck. Enlarged lymph nodes were selected up to a maximum diameter of 15 mm. In the case of multiple enlargements, a jugular node was preferred. One node was examined in each patient to avoid bias by rest enhancement of subsequent contrast agent applications. Lymph nodes were systematically examined with B-mode sonography, CCDS, and finally contrast-enhanced CCDS. We used a Sonoline Elegra (Siemens Medical Solutions, Erlangen) with a 7.5-MHz linear phase array ultra-

sound probe. The ultrasound device settings remained unchanged during all investigations to minimize bias due to different technical device parameters and also included the blooming effect of initial contrast agent arrival. The ultrasonograms were stored on videotapes and digitally recorded on computer disks. Analysis of the color-coded pixel information was performed with a specific computer-based image processor (Cap-Image, Dr Zeintl, Heidelberg, Germany). For contrast enhancement, we used a water-soluble, pulmonary-stable contrast agent (4-g portion of Levovist, Schering, Berlin, Germany) that was administered intravenously over a period of 10 seconds.

During ultrasonographic investigation, video images were continuously acquired over a period of 4 minutes; the first one showed the precontrast perfusion. For assessing intranodal color-coded information, we selected every 10 seconds of the middle of a systolic phase for optimum depiction of vessel perfusion. Earlier, the boundaries of affected lymph nodes had been manually circumscribed as regions of interest and marked to define an exact area for the subsequent color signal measurements. For later identification of selected nodes during surgery, the exact position and orientation was indicated on the patient's skin. The computer algorithm was able to measure color-coded pixel information in the defined region of interest and compute flooding and washout of the contrast agent in the 24 images. For statistical analysis, the nonparametric Wilcoxon U test for independent samples was used. Calculations were performed with the SPSS 7.5 and SAS 6.12 package. The estimated statistical significance was set at  $p < .05$ .

**Static and Dynamic Parameters.** To compare interindividual color-coded signals, we calculated the color-coded area and expressed it as a percentage of the whole delineated lymph node area. The calculated values are shown in Fig 1.

**Assessment of Microvessel Density.** Tissue specimens taken during surgery were marked for their original orientation to ensure that the histologic examination corresponded to the ultrasonogram. This was achieved by marking the sonographically assessed node position on the patient's skin. The lymph nodes that were to undergo biopsy were routinely formalin-fixed and embedded in paraffin. The pattern of vascularization was investigated by immunohistochemistry with antibodies to specific vascular cell antigens (CD-31 and factor VIII-related antigen). Vascular size and vessel density of the colored slices were finally analyzed by routine histologic procedures. Under magnification ( $\times 100$ ), 4 regions ( $1 \text{ mm}^2$ ) per slice and per specimen were examined. Microvessels and macrovessels were counted separately; a cutoff

TABLE 1. DYNAMIC PARAMETERS OF CONTRAST AGENT BEHAVIOR IN INFLAMMATORY AND METASTATIC LYMPH NODES

	<i>Inflammatory Lymph Nodes</i>	<i>Metastatic Lymph Nodes</i>	<i>p</i>
A0 (%)	2.81 ± 5.59	8.66 ± 9.17	.01
Amax (%)	26.61 ± 18.74	28.63 ± 19.33	.75
Tmax (s)	56.00 ± 28.23	55.39 ± 35.73	.85

Data are mean ± SD.  
 A0 — contribution of color-coded signal area to calculated entire lymph node area before contrast agent application; Amax — contribution of maximum color-coded area after administration of contrast agent; Tmax — period of time lapse between contrast agent injection and appearance of maximum color Doppler signal area.

value of 0.1 mm was used to differentiate between microvessels and macrovessels.

RESULTS

The 28 lymph nodes examined had a mean diam-

eter of 11 mm (range, 4 to 14 mm). The area of color-coded information in metastatic lymph nodes before contrast injection (A0) was found to be higher than that in inflammatory lymph nodes. The postcontrast comparison of the color-coded area (Amax) and the velocity required to reach maximum contrast enhancement (Tmax) showed no significant difference in the two entities (Table 1 and Fig 2).

The mean relative increase of the color-coded area after contrast medium application (Amax/A0) was calculated as an increase by a factor of 19.55 (SD, 18.90) for the reactively altered lymph nodes, in contrast to malignant nodes, which had a calculated increase by a factor of 10.03 (SD, 14.07). Inflammatory lymph nodes showed a greater mean relative increase in the color-coded area than did metastases (p = .025).

Fig 2. Transverse images of metastatic lymph node laterally located by carotid artery bifurcation A) before and B) after application of contrast agent. SCM — sternocleidomastoid muscle, CCA — common carotid artery. Green line indicates region of interest, and color-coded information is outlined with yellow.

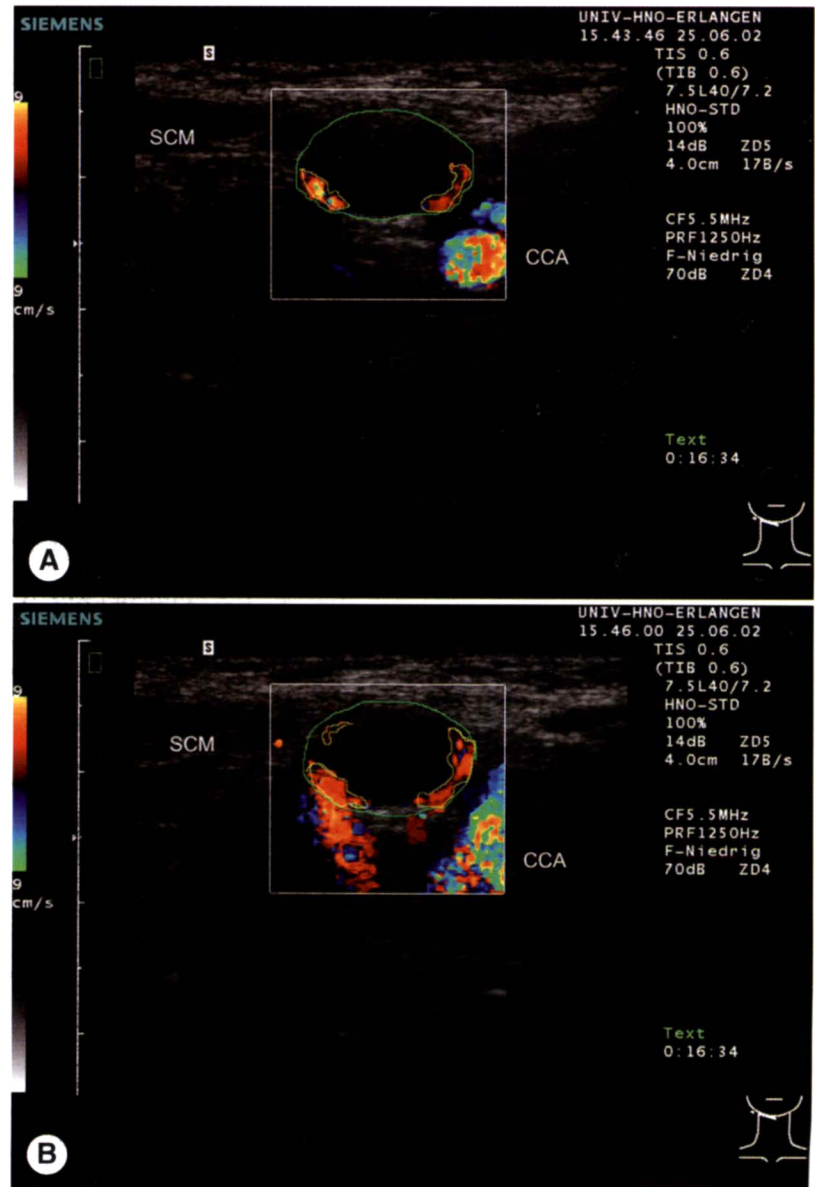


TABLE 2. MEAN NUMBERS OF MACROVESSELS AND MICROVESSELS FOUND IN INFLAMMATORY AND METASTATIC LYMPH NODES

	<i>Inflammatory Lymph Nodes</i>	<i>Metastatic Lymph Nodes</i>	<i>p</i>
Microvessels <.01 mm	42.2 ± 18.7	42.07 ± 16.04	.7171
Macrovessels ≥.01 mm	3.33 ± 1.85	5.46 ± 1.91	.007

Data are mean ± SD.

The gradient of the CCDS signal plot up to the point of maximum contrast saturation ( $\Delta A/\Delta t$ ) showed no significant ( $p = .618$ ) difference between the two groups. Reactively enlarged nodes increased by 0.55%/s (SD, 0.61%/s), whereas cervical metastases had a mean elevation of 0.51%/s (SD, 0.64%/s).

The negative gradient of contrast agent washout ( $-\Delta A/\Delta t$ ) was calculated as  $-27.96\%/s$  (SD, 22.45%/s) in benign nodes. The signals of the metastatic nodes decreased with a gradient of  $-18.83\%/s$  (SD, 16.19%/s). For this dynamic parameter, no statistically significant difference could be found ( $p = .294$ ). With regard to the type of vessels, a statistically greater number of macrovessels in metastatic nodes was confirmed ( $p = .007$ ; Table 2).

## DISCUSSION

Despite advances in imaging techniques, a definite verification of cervical metastases or inflammation is still not achievable; the most accepted criteria remain size (short and long axis lengths) and morphological features such as abnormal echogenicity, necrosis, and infiltrative growth in B-scan sonography.<sup>2</sup> CCDS techniques have been used to increase the diagnostic impact by showing the presence of the hilus and the type of hilar perfusion along with Doppler spectral analysis of intranodal vessels.<sup>4,17</sup> The impact of each of these predictive ultrasonographic criteria has not yet been evaluated in the same way and is often associated with the dimension of the node. The presence of metastases in cervical lymph nodes with a diameter of less than 10 mm in head and neck tumors is estimated at 15% to 75%. We intentionally chose lymph nodes with a diameter of less than 15 mm, as these are known to present particular difficulty in differential diagnosis. In our study we therefore found no nodes with focal necrosis or infiltrative signs. We aimed to set up new objective criteria to differentiate lymph node perfusion patterns and to assess small intranodal vessels. Progression of malignant cells is known to be accompanied by intratumoral neoangiogenesis.<sup>21</sup> When studied histologically, tumor perfusion reveals a significant correlation between vessel density and metastatic propagation; a typical vascularization pattern would therefore be a helpful diagnostic marker.<sup>21-24</sup> In accor-

dance with many other study groups, we observed significant differences in perfusion patterns between benign and malignant lymph nodes.<sup>6,25-27</sup> Before application of a contrast agent, we detected a color-coded signal that was lower in intensity in reactively enlarged lymph nodes than in metastatic nodes. A possible explanation for this particular phenomenon might be the onset of peripheral malignant infiltration induced by neoplastic vascular growth of macrovessels.<sup>26</sup> Although we did not differentiate between peripheral and centrally located vessels, we found through histologic assessment that malignant lymph nodes had a greater number of macrovessels than did inflammatory nodes (5.46 versus 3.33;  $p = .007$ ). The latter, in contrast, appeared to possess a high density of microvessels, which are not depicted on unenhanced ultrasonography because of their minimal size and flow velocity. Therefore, we accordingly noted a mean relative increase in the color-coded area in regard to inflammatory lymph nodes after contrast agent application.

In contrast to earlier investigators, we were able to directly compare and analyze vessels from immunohistochemical specimens with color-coded information. Measurement of a relative increase in the color-coded area has the advantage that the size of the lymph node is less important. Unexpectedly, the behavior of the contrast agent in relation to time (flooding and washout) revealed no significant difference, despite the different vascular architectures noted. We therefore agree with Ellegala et al<sup>20</sup> that the extent of tumor angiogenesis may possibly not be reflected by perfusion because of the low functional efficiency of the malignant tumor vessels. We therefore cannot corroborate the hypothesis that an increased number of macrovessels correlates to a greater signal boost. It has to be mentioned that in 2 cases, a metastatic lymph node showed characteristics of an inflammatory vessel pattern, demonstrating that perfusion analysis might lead to a false-negative diagnosis.

Our results indicate that a benign lesion is more probable when a lymph node displays a low precontrast perfusion and a steep postcontrast increase. We conclude that in cases of small lymph nodes with a size of less than 15 mm, assessment of quantitative lymph node perfusion may provide additional information in differentiating between benign and malignant lymph nodes, but does not allow a safe determination of node status. Unenhanced CCDS appears to remain the primary assessment measure. For further evaluation, prospective clinical trials with a large number of patients and implementation of currently available real-time contrast-specific imaging modalities, such as low mechanical index or ensemble contrast imaging, has to be initiated.

ACKNOWLEDGMENTS — Many thanks to Klaus Bumm, MD, and Stuart Irwin for the revision of the English manuscript.

## REFERENCES

1. Som PM. Lymph nodes of the neck. *Radiology* 1987;165:593-600.
2. Wu CH, Lee MM, Huang KC, Ko JY, Sheen TS, Hsieh FJ. A probability prediction rule for malignant cervical lymphadenopathy using sonography. *Head Neck* 2000;22:223-8.
3. Dragoni F, Cartoni C, Pescarmona E, et al. The role of high resolution pulsed and color Doppler ultrasound in the differential diagnosis of benign and malignant lymphadenopathy: results of multivariate analysis. *Cancer* 1999;85:2485-90.
4. Steinkamp HJ, Wissgott C, Rademaker J, Felix R. Current status of power Doppler and color Doppler sonography in the differential diagnosis of lymph node lesions. *Eur Radiol* 2002;12:1785-93.
5. Steinkamp HJ, Mathe F, Treisch J, Hosten N, Neumann K, Felix R. Histologisch kontrollierte Studie zur Wertigkeit der Sonographie und der Palpation zum Nachweis und Ausschluß von Halslymphknotenvergrößerungen und -metastasen. *Aktuelle Radiol* 1991;1:312-8.
6. Mäurer J, Willam C, Schroeder R, et al. Evaluation of metastases and reactive lymph nodes in Doppler sonography using an ultrasound contrast enhancer. *Invest Radiol* 1997;32:441-6.
7. Schröder RJ, Mäurer J, Hidajat N, et al. Signalverstärkte farbkodierte Duplexsonographie reaktiv und metastatisch Vergrößerter Lymphknoten. *Rofo Fortschr Geb Röntgenstr Neuen Bildgeb Verfahr* 1998;168:57-63.
8. Cosgrove D. Ultrasound contrast enhancement of tumours. *Clin Radiol* 1996;51(suppl 1):44-9.
9. Tschammler A, Knitter J, Wittenberg G, Krahe TH, Hahn D. Quantifizierung der Lymphknotenperfusion mittels farbkodierter Duplexsonographie. *Rofo Fortschr Geb Röntgenstr Neuen Bildgeb Verfahr* 1995;163:203-9.
10. Steinkamp HJ, Mueffelman M, Böck JC, Thiel T, Kenzel P, Felix R. Differential diagnosis of lymph node lesions: a semi-quantitative approach with colour Doppler ultrasound. *Br J Radiol* 1998;71:828-33.
11. Delorme S, Dietz A, Rudat V, Zuna I, Bahner ML, van Kaick G. Prognostic significance of color Doppler findings in head and neck tumors. *Ultrasound Med Biol* 1997;23:1311-7.
12. van den Brekel MWM, Castelijns JA, Snow GB. The size of lymph nodes in the neck on sonograms as a radiologic criterion for metastasis: how reliable is it? *AJNR Am J Neuroradiol* 1998;19:695-700.
13. Wang Q, Takashima S, Takayama F, et al. Detection of occult metastatic lymph nodes in the neck with gray-scale and power Doppler US. *Acta Radiol* 2001;42:312-9.
14. Giancarlo T, Palmieri A, Giacomarra V, Russolo M. Pre-operative evaluation of cervical adenopathies in tumours of the upper aerodigestive tract. *Anticancer Res* 1998;18:2805-9.
15. Arijii Y, Kimura Y, Hayashi N, et al. Power Doppler sonography of cervical lymph nodes in patients with head and neck cancer. *AJNR Am J Neuroradiol* 1998;19:303-7.
16. Issing PR, Ketting T, Kempf HG, Heermann R, Lenarz T. Sonographische Dignitätsbeurteilung von Halslymphknoten unter besonderer Berücksichtigung der Farbdopplersonographie. Ein Beitrag zur Abgrenzung reaktiver von metastatisch befallenen Lymphknoten des Halses. *Laryngorhinootologie* 1999;78:566-72.
17. Chikui T, Yonetsu K, Nakamura T. Multivariate feature analysis of sonographic findings of metastatic cervical lymph nodes: contribution of blood flow features revealed by power Doppler sonography for predicting metastasis. *AJNR Am J Neuroradiol* 2000;21:561-7.
18. Jecker P, Engelke JC, Westhofen M. Über die Einsatzmöglichkeit eines Signalverstärkers für die Duplexsonographie in der Hals-Nasen-Ohrenheilkunde. *Laryngorhinootologie* 1998;77:289-93.
19. Moritz JD, Ludwig A, Oestmann JW. Contrast-enhanced color Doppler sonography for evaluation of enlarged cervical lymph nodes in head and neck tumors. *AJR Am J Roentgenol* 2000;174:1279-84.
20. Ellegala DB, Leong-Poi H, Carpenter JE, et al. Imaging tumor angiogenesis with contrast ultrasound and microbubbles targeted to  $\alpha v\beta_3$ . *Circulation* 2003;108:336-41.
21. Weidner N, Folkman J, Pozza F, et al. Tumor angiogenesis: a new significant and independent prognostic indicator in early-stage breast carcinoma. *J Natl Cancer Inst* 1992;84:1875-87.
22. Valentin L. Gray scale sonography, subjective evaluation of the color Doppler image and measurement of blood flow velocity for distinguishing benign and malignant tumors of suspected adnexal origin. *Eur J Obstet Gynecol Reprod Biol* 1997;72:63-72.
23. Lee WJ, Chu JS, Houg SJ, Chung MF, Wang SM, Chen KM. Breast cancer angiogenesis: a quantitative morphologic and Doppler imaging study. *Ann Surg Oncol* 1995;2:246-51.
24. Luska G, Lott D, Risch U, von Boetticher H. Befunde der Farb-Doppler-Sonographie bei Tumoren der Brustdrüse. *Rofo Fortschr Geb Röntgenstr Neuen Bildgeb Verfahr* 1992;156:142-5.
25. Wu CH, Hsu MM, Chang YL, Hsieh FJ. Vascular pathology of malignant cervical lymphadenopathy: qualitative and quantitative assessment with power Doppler ultrasound. *Cancer* 1998;83:1189-96.
26. Steinkamp HJ, Mäurer J, Cornehl M, Knöbber D, Hettwer H, Felix R. Recurrent cervical lymphadenopathy: differential diagnosis with color-duplex sonography. *Eur Arch Otorhinolaryngol* 1994;251:404-9.
27. Leuwer RM, Westhofen M, Henke RP. Was leistet die farbkodierte Duplex-sonographie in der Diagnostik von Kopf-Hals-Tumoren? *Laryngorhinootologie* 1996;75:95-9.