

Laser lithotripsy of salivary duct stones

Heinrich Iro, Johannes Zenk, W. Benzel

Angaben zur Veröffentlichung / Publication details:

Iro, Heinrich, Johannes Zenk, and W. Benzel. 2015. "Laser lithotripsy of salivary duct stones." In *Lasers in Otorhinolaryngology, and in Head and Neck Surgery: 4th International Symposium, Kiel, January 1994*, edited by H. Rudert and J. A. Werner, 148-52. Basel: Karger. <https://doi.org/10.1159/000424360>.

Nutzungsbedingungen / Terms of use:

licgercopyright

Dieses Dokument wird unter folgenden Bedingungen zur Verfügung gestellt: / This document is made available under the following conditions:

Deutsches Urheberrecht

Weitere Informationen finden Sie unter: / For more information see:

<https://www.uni-augsburg.de/de/organisation/bibliothek/publizieren-zitieren-archivieren/publizieren>



.....

Laser Lithotripsy of Salivary Duct Stones

H. Iro, J. Zenk, W. Benzel

Department of Oto-Rhino-Laryngology, Head and Neck Surgery
(Head: Prof. M. E. Wigand), University of Erlangen-Nuremberg, Germany

Besides piezoelectric extracorporeal lithotripsy of salivary stones [1], there are different possibilities for intracorporeal, endoscopically guided lithotripsy when treating sialolithiasis. Because of the specific anatomy of the peripheral salivary ducts and due to the very often bright color of the salivary stones, several systems are not suitable for clinical management as proved experimentally in *in vitro* and *in vivo* studies.

Because of the severe tissue damage shown in animal experiments, the use of electrohydraulic intracorporeal lithotripsy as well as Excimer laser lithotripsy seems not to be justified for treating human sialolithiasis despite the good stone fragmentation *in vitro* [2, 3]. The Nd:YAG laser and the Alexandrit laser were not suitable in *in vitro* studies due to the insufficient fragmentation of salivary calculi [2]. On the contrary, with the help of a Rhodamine 6-G flashlamp pumped dye laser (Lithognost, Telemit Co., Germany), a sufficient stone fragmentation rate of 75% was achieved *in vitro*. With this dye laser an integrated stone-tissue detection system on the basis of fluorescence spectroscopy is connectable. While activating this stone-tissue detection system in animal experiments no tissue damage was detected in the peripheral salivary ducts of rabbits during shockwave application. Because of these experimental results this dye-laser system seems to be suitable for use in human sialolithiasis [4]. In the following, we report our clinical experiences using the Rhodamine 6-G dye laser in the intracorporeal endoscopically guided treatment of salivary calculi of the submandibular gland.




Fig. 1. Endoscope with the laser fibre inserted.

Material and Methods

Patients

Only patients with symptomatic solitary submandibular stones situated near the hilus were eligible for this prospective study.

All together, 8 women and 12 men aged between 34 and 55 years were included. The sizes of the salivary calculi were seen on ultrasound, and concretions larger than 10 mm were excluded from the study. Patients suffering from salivary calculi of the parotid gland were also excluded, as for sufficient insertion of the endoscope into the salivary duct slitting of the duct about 2 weeks before laser treatment is necessary. Slitting of the parotid salivary duct has a high risk of obstruction due to scarring and stenosis.

Endoscope

We used a flexible endoscope with an outer diameter of 1.6 mm and a working channel of 600 μm both for endoscopic diagnosis as well as for intracorporeal guided laser lithotripsy. This endoscope, which is only available as a prototype, can actively be bent along one level (fig. 1).

Lithotripter

The Rhodamine 6-G dye laser which we used for our studies emits at a wave-length of 595 nm with a maximum pulse energy of 120 mJ.

Energy is transmitted through extremely thin, flexible glass fibres with a diameter of 250 μm . Laser pulses are applied to the stone in a noncontact mode. A connectable automatic feedback cut-out (stone-tissue detection system) regulates the intensity of the laser beam. The preset level of energy is only applied if the beam of light is reflected from the surface of the stone. If the beam makes contact with tissue, the energy level of the laser pulse is automatically reduced to approximately 10% of its original energy by means of fluorescence spectroscopy after about 200 ns.

Application of Intracorporeal Laser Lithotripsy

Two weeks after slitting and marsupialisation of the duct of the submandibular gland intracorporeal endoscopically guided laser lithotripsy was performed. After local anaesthesia, the endoscope was inserted into the duct until the salivary stone was localized. After-

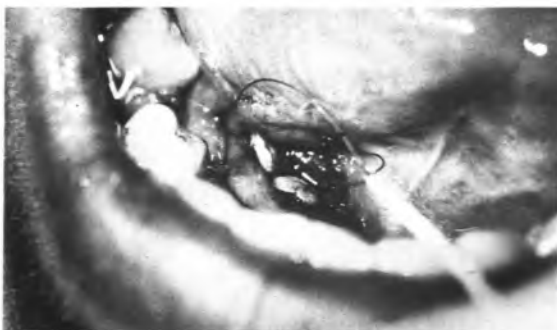

Fig. 2. Removal of fragments by a dormia basket after laser lithotripsy of a submandibular gland stone.

wards, the laser fibre together with the irrigation unit were put into the working channel of the endoscope. The treatment of salivary calculi with laser pulses happened under direct optical control with simultaneous NaCl irrigation.

With the option 'stone tissue detection activated', up to 1,500 pulses were applied to the concrement with maximum energy. In those cases where complete fragmentation of the stone was achieved, treatment was stopped before completing the 1,500 impulses. After laser lithotripsy, fragments had been extracted with the help of dormia baskets (fig. 2). Moreover, patients were asked to enforce saliva secretion (lemon juice, chewing gum) in order to reach an expulsion of the fragments through the salivary duct.

Follow-Up Period

Each patient was controlled sonographically and clinically at least 6 months after laser lithotripsy. Attention was especially directed to the rate of stone-free patients as well as to the rate of patients free of any discomfort.

Results

Only 2 of 20 salivary calculi (10%) were destroyed completely. Among these, patients lacking concrements were evaluated clinically and sonographically 6 months after laser lithotripsy. Eleven stones (55%) were only partly fragmented. In these cases, parts of the concrements were still detectable, but more or less significantly reduced in size. In the follow-up period, 8 of these 11 patients' felt completely free of discomfort. Three of them further reported transient swelling of the salivary gland at meals. In 7 patients (35%), laser lithotripsy was not successful at all, no calculus reaction towards the laser beams was detected. These patients' symptoms of obstructive sialadenitis were un-

changed. Thus, treatment of submandibular gland calculi smaller than 10 mm resulted in a 10% rate concerning complete disappearance of concrements and a 50% rate of no further discomfort caused by sialolithiasis. Stones which showed any reaction to the laser beams were commonly dark in color, whereas concrements which showed no reaction were brightly colored, meaning that a major part of the laser light was reflected.

Discussion

Treatment of ureteral calculi and concrements within the descending ducts of the gallbladder by means of intracorporeal laser lithotripsy has already been established clinically.

Concerning the intracorporeal laser lithotripsy of salivary calculi, until now only clinical experiences made by an Excimer laser system have been published [5, 6]. In the course of in vitro and animal experiment studies, it has been demonstrated that application of laser pulses created by an Excimer laser lead to severe damage of the salivary duct as well as important surrounding structures (vessels, nerves) [2, 5]. Moreover, no results concerning the stone-free rate after Excimer-laser lithotripsy are known.

With regard to in vitro and animal experiment studies, the Rhodamine 6-G dye laser seems to be usable even in the narrow peripheral salivary ducts of humans [4].

For introduction of the endoscope, a slitting of the salivary duct of the afflicted gland is necessary, especially in the area of the orifice, as the most narrow parts of the ducts are localized there. Because of the particular preference concerning stenosis of Stensens duct after slitting it, removal of parotid calculi by intracorporeal laser lithotripsy does not seem to be suitable.

We have not seen such stenosis after slitting of Whartons duct in our clinical experience nor have such events been reported in literature. Therefore, endoscopically guided, intracorporeal laser lithotripsy is well suited to remove concrements of the submandibular gland.

During the follow-up period, our results with intracorporeal, endoscopically guided laser lithotripsy showed a free-of-stone rate of only 10% but a distinctly higher rate of 50% concerning complete loss of discomfort.

As a result of our experiences, intracorporeal, endoscopically guided laser lithotripsy – we therefore used a dye laser system with connectable automatic feedback cut-out – can be recommended only in a restricted manner as an alternative to other already established methods of treatment in human sialolithiasis (extracorporeal piezoelectric shockwave lithotripsy, sialodochoplasty, submandibulectomy).

The clinical use of intracorporeal, endoscopically guided lithotripsy with a dye laser should be reserved for special cases.

Nevertheless, in these singular cases complete loss of salivary calculi can be obtained and loss of any complaints can be achieved in a larger number of patients.

References

- 1 Iro H, Schneider HTh, Födra C, Waitz G, Nitsche N, Heinritz HH, Benninger J, Ell Ch: Shock-wave lithotripsy of salivary duct stones. *Lancet* 1992;339:1333.
- 2 Iro H, Zenk J, Benzel W, Hosemann WG, Hochberger J, Ell Ch: Experimentelle Untersuchungen zur Laser-Lithotripsie von Speichelsteinen. *Lasermedizin* 1992;8:110.
- 3 Zenk J, Benzel W, Hosemann WG, Iro H: Experimental research on electrohydraulic lithotripsy of sialolithiasis. *Eur Arch Otorhinolaryngol* 1992;249:436.
- 4 Benzel W, Hofer M, Hosemann WG, Iro H: Laser-induced shock wave lithotripsy of salivary calculi with automatic feedback cessation in case of tissue contact: in vitro and animal experiments. *Eur Arch Otorhinolaryngol* 1992;249:437.
- 5 Gundlach P, Scherer H, Hopf J, Leege N, Müller G: Die endoskopisch kontrollierte Laserlithotripsie von Speichelsteinen: In-vitro-Untersuchungen und erster klinischer Einsatz. *HNO* 1990; 38:247.
- 6 Königsberger R, Feyh J, Goetz A, Schilling V, Kastenbauer E: Die endoskopisch kontrollierte Laserlithotripsie zur Behandlung der Sialolithiasis. *Laryngol Rhinol Otol* 1990;69:322.

Priv.-Doz. Dr. H. Iro, Department of Oto-Rhino-Laryngology, Head and Neck Surgery,
Waldstrasse 1, D-91054 Erlangen (Germany)