

## Enoral/transoral surgery of malignancies of the oral cavity and the oropharynx

Heinrich Iro, Frank Waldfahrer, K. Gewalt, Johannes Zenk, A. Altendorf-Hofmann

### Angaben zur Veröffentlichung / Publication details:

Iro, Heinrich, Frank Waldfahrer, K. Gewalt, Johannes Zenk, and A. Altendorf-Hofmann. 2015. "Enoral/transoral surgery of malignancies of the oral cavity and the oropharynx." In *Lasers in Otorhinolaryngology, and in Head and Neck Surgery: 4th International Symposium, Kiel, January 1994*, edited by H. Rudert and J. A. Werner, 191–95. Basel: Karger.  
<https://doi.org/10.1159/000424371>.

### Nutzungsbedingungen / Terms of use:

licgercopyright

Dieses Dokument wird unter folgenden Bedingungen zur Verfügung gestellt: / This document is made available under the following conditions:

**Deutsches Urheberrecht**

Weitere Informationen finden Sie unter: / For more information see:

<https://www.uni-augsburg.de/de/organisation/bibliothek/publizieren-zitieren-archivieren/publizieren>



.....

## **Enoral/Transoral Surgery of Malignancies of the Oral Cavity and the Oropharynx<sup>1</sup>**

*H. Iro, F. Waldfahrer, K. Gewalt, J. Zenk, A. Altendorf-Hofmann*

Department of Oto-Rhino-Laryngology, Head and Neck Surgery  
(Head: Prof. *M.E. Wigand*), University of Erlangen-Nuremberg, Germany

Since the end of the last century surgical treatment of malignomas of the oral cavity and the oropharynx has emphasized radical en bloc (segmental) tumor resections. The primary tumor has been removed in continuity with a radical neck dissection. The results of these so-called comando operations, advocated mainly by Martin and Sugarbaker [1] and Conley and von Fränkel [2] can, however, be described as disappointing referring also to the quality of life of the patients afterwards. During the last 15 years enoral and transoral resections of malignomas of the oral cavity and the oropharynx were increasingly favored.

This technique prefers the physiological preformed route to the transcervical approach through the soft tissues of the neck. Necessary neck dissections are performed either in the same operation discontinuously or in a second step 2 or 3 weeks later, depending on the size and location of the primary tumor.

Since the end of the 1970s, the enoral/transoral techniques of tumor resections in the upper aerodigestive tract together with discontinuously performed functional neck dissections have been carried out in the ENT Department of the University of Erlangen-Nuremberg. In a retrospective study, the results of this tumor management will be demonstrated.

<sup>1</sup> This work was supported by the Johannes and Frieda Marohn Foundation and the Sophie Wallner Foundation, Friedrich Alexander Universität, Erlangen-Nürnberg.

## **Patients and Methods**

In our study the history of 205 patients with squamous cell carcinoma of the oropharynx and 186 patients with squamous cell carcinomas of the oral cavity were analyzed. In the cases of the oropharynx carcinomas 47 patients suffered from stage I or II tumors, 55 from stage III tumors and 103 patients from stage IV tumors [3]. Seventy-nine patients with carcinomas of the oral cavity had stage I or II tumors, 67 patients stage III and 40 patients stage IV tumors.

### *Treatment*

In all patients the primary tumor has been removed by enoral/transoral resection – partly by electrosurgery and partly by applying microscope-coupled CO<sub>2</sub> laser. Depending on the size and the location of the primary tumor, functional neck dissection has been performed either in the same operation discontinuously or in a second step 2 or 3 weeks later.

In stage III and IV, a postoperative percutaneous radiotherapy has been carried out.

### *Evaluation*

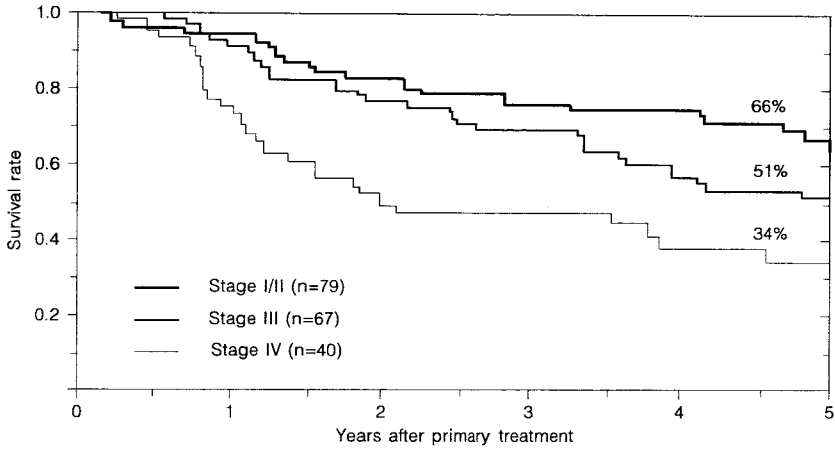
The histories of the patients who were operated until 31.12.1990 were retrospectively analyzed passing an especially developed questionnaire. The follow-up period was at least 3 years.

## **Results**

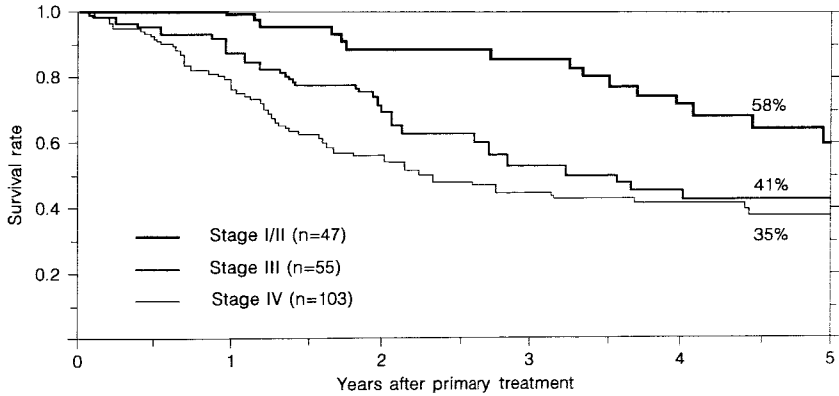
The noncorrected 5-year survival rates of oral cavity carcinomas in tumor stages I and II were 66%, whereas it was 51% in tumor stage III and 34% in stage IV (fig. 1). In the cases of oropharynx carcinomas we reached noncorrected 5-year survival rates of 58% in tumor stages I and II, 41% in stage III and 35% in stage IV with enoral/transoral tumor management (fig. 2).

## **Discussion**

Within the last 15 years, various research groups have published reports on transoral resections which were performed in cases of advanced malignancies in regions of the oral cavity and oropharynx – partly by electrosurgery and partly by applying microscope-coupled CO<sub>2</sub> lasers [4–9]. The oncological results reported are comparable to those achieved by bloc resections and reconstruction of defects by pedicled or microvascular anastomosed flaps [10–12]. Panje et al. [7] and Steiner [13], in particular, have emphasized the substantially lower degree of impairment of the patient caused by transoral resections, thus rendering unnecessary measures to reconstruct defects. By spontaneous epithelialization of the operated sites, extensive functional maintenance can be



*Fig. 1.* Survival rate after enoral surgery of malignancies of the oral cavity, combined with neck dissection and postoperative radiotherapy (in cases of stage III and IV). n = 186.



*Fig. 2.* Survival rate after enoral/transoral surgery of malignancies of the oropharynx, combined with neck dissection and postoperative radiotherapy (in cases of stage III and IV). n = 205.

achieved, with little cosmetic impairment [7]. Strong [9] recommends minimally invasive, conservative transoral resections of carcinomas whenever such an approach is manageable. If tumor margins cannot, however, be clearly outlined or if tumor has penetrated into adjacent soft tissue of the neck, Strong [9] believes that transoral resections are no longer possible. Denecke [14], on the other hand, considers a transoral approach to be essentially feasible, even if the mandible has been infiltrated. Nonetheless, the cancer principles of a defined resection, as documented anew by Looser et al. [15], must be strictly observed from the viewpoint of curative therapy in both enoral and transoral, minimally invasive and function-conserving operative techniques.

Based on our reported results we also emphasize that enoral/transoral management of malignancies of the oral cavity and the oropharynx is a promising oncological concept causing less discomfort and impairment for the patients. In our opinion a decisive precondition for the enoral/transoral approach to the tumor is that it is recognized and seen in its borders, i.e. the tumor must be sufficiently exposed during operation. Tumor expansion into the soft tissues of the neck, reaching the internal jugular vein or the carotid artery is seen as a contraindication for enoral/transoral tumor resection. In these cases or if the malignancies have infiltrated larger parts of bony structures, e.g. the mandible, a modified approach from outside with reconstruction of defects – if necessary – by prediced or microvascular anastomosed flaps is recommended.

## References

- 1 Martin H, Sugerbaker EL: Cancer of the tonsil. *Am J Surg* 1941;52:158–196.
- 2 Conley JJ, von Fraenkel T: Historical aspect of head and neck surgery. *Ann Otol* 1956;65: 643–655.
- 3 UICC: TNM Classification of Malignant Tumours, ed 4. Berlin, Springer, 1987.
- 4 Barrs DM, DeSanto LW, O'Fallon WM: Squamous cell carcinoma of the tonsil and tongue-base region. *Arch Otolaryngol* 1979;105:479–485.
- 5 Frame JW, Morgan D, Rhys Evans PH: Tongue resection with the CO<sub>2</sub> laser: The effects of past radiotherapy on postoperative complications. *Br J Oral Maxillofac Surg* 1988;26:464–471.
- 6 Marks JE, Lee F, Freeman RB, Zivnuska FR: Carcinoma of the oral tongue: A study of patient selection and treatment results. *Laryngoscope* 1981;91:1548–1559.
- 7 Panje WR, Scher N, Karnell M: Transoral carbon dioxide laser ablation for cancer, tumors, and other diseases. *Arch Otolaryngol Head Neck Surg* 1989;115:681–688.
- 8 Rhys Williams S, Carruth JAS: The role of the carbon dioxide laser in treatment of carcinoma of the tongue. *J Laryngol Otol* 1988;102:1122–1123.
- 9 Strong E: Surgical management of oral cancer. *Dent Clin North Am* 1990;34:185–203.
- 10 Jahnke V: Die Chirurgie der Zungen- und Mundbodentumoren. *Arch Ohren-Nasen-Kehlkopfheilkd* 1975;210:275.
- 11 Meyer H-J, Terrahe K, Haug H, Schmidt W: Die freie Dünndarmtransplantation zur plastischen Rekonstruktion von Mundhöhle, Pharynx und zervikalem Ösophagus. *Laryngol Rhinol Otol* 1988;67:1–6.

- 12 Rudert H: Die chirurgische Behandlung der Oropharynx Tumoren. Arch Otorhinolaryngol 1984;241(suppl II):92-102.
- 13 Steiner W: Endoscopic therapy of early laryngeal cancer. Indications and results: Wigand ME, Steiner W, Stell PM (eds): Functional Partial Laryngectomy. Conservation Surgery for Carcinoma of the Larynx. Berlin, Springer, 1984, pp 163-170.
- 14 Denecke HJ: Die oto-rhino-laryngologischen Operationen; in Kirschner M, Guleke ZN, Zenker R (eds): Allgemeine und Spezielle Chirurgische Operationslehre, ed 2. Berlin, Springer, 1953, vol 5, pp 286-294.
- 15 Looser KG, Shah JP, Strong EW: The significance of 'positive' margins in surgically resected epidermoid carcinomas. Head Neck Surg 1978;1:107.

Priv.-Doz. Dr. H. Iro, Department of Oto-Rhino-Laryngology, Head and Neck Surgery,  
Waldstrasse 1, D-91045 Erlangen (Germany)