

Case report

Anterior Impingement After Mobile-Bearing Unicompartmental Knee Arthroplasty—A Neglected Problem. A Clinical Report of 14 Cases

Timon Röttinger, MD ^a, Leonard Lisitano, MD ^a, Andreas Wiedl, MD ^a, Edgar Mayr, MD ^a, Heinz Röttinger, MD ^{b, c, *}^a Department of Trauma Surgery, Orthopedics, Plastic and Hand Surgery, University Hospital of Augsburg, Augsburg, Germany^b Department of Arthroplasty, München Klinik Neuperlach, Munich, Germany^c Faculty of Medical University of Pleven, Pleven, Bulgaria

ARTICLE INFO

Article history:

Received 5 May 2021

Received in revised form

20 June 2022

Accepted 23 June 2022

Available online 19 August 2022

Keywords:

Unicompartmental knee arthroplasty

Mobile-bearing

Outcomes

Oxford knee

Impingement

ABSTRACT

Background: Mobile-bearing unicompartmental knee arthroplasty (MB-UKA) is a proven implant that has reliably delivered excellent results for decades. Based on the constrained implant design in MB-UKA, the occasional occurrence of anterior impingement should be expected. However, surprisingly, there are no clinical reports.

Methods: From 2016 to 2020, 14 patients with anterior medial knee pain were admitted to our arthroplasty center after MB-UKA implantation elsewhere. After taking the medical history and clinical examination, radiological imaging of the implant in at least 2 planes, including a whole-leg anteroposterior view, was performed. The “Knee Society Score (KSS)” and the “Knee Injury and Osteoarthritis Outcome Score (KOOS)” were recorded. Anterior impingement was diagnosed by reviewing the typical findings and specific exclusion of other diagnoses.

Results: The 14 patients showed a KSS of 46.6 and a KOOS of 51.5. The average pain level on the “Visual Analog Scale” was 7.8. The positioning of the implants showed consistently noticeable deviations from the standard recommendations. All 14 patients were treated by removing the MB-UKA and changing to a complete TKA. At the 12-month follow-up, the average Visual Analog Scale score was 1.8, and KOOS and KSS were 86 and 82, respectively.

Conclusions: The potential risk of anterior impingement in MB-UKA can be assumed. Diagnosis requires a detailed collection of medical history and clinical details combined with accurate radiological imaging. The cause of anterior impingement in MB-UKA is multifactorial and refers in our small group to the sum of minor deviations in implant positioning compared to the general recommendations.

© 2022 The Authors. Published by Elsevier Inc. on behalf of The American Association of Hip and Knee Surgeons. This is an open access article under the CC BY-NC-ND license (<http://creativecommons.org/licenses/by-nc-nd/4.0/>).

Introduction

The unicompartmental knee arthroplasty (UKA) has been developed based on 2 design features: the mobile-bearing unicompartmental knee arthroplasty (MB-UKA) and the fixed-bearing unicompartmental knee arthroplasty (FB-UKA). MB-UKA and FB-UKA show comparable results and revision rates [1,2]. The Oxford knee system (Zimmer-Biomet, Warsaw, IN) was the first implant in unicompartmental knee arthroplasty with mobile-bearing properties. The original Oxford knee system has been in

clinical use for more than 40 years [3]. The current implant modification appeared on the market in its third product version (Oxford Phase III) in 2004 [4].

The Oxford knee system's typical product feature is the mobile-bearing polyethylene inlay, guided by the matching congruent femoral component and slides on the flat and polished tibial plate. In contrast, the FB-UKA has the polyethylene component fixed on the tibia implant. In FB-UKA, the femoral condyle moves on a flat surface (“round on flat”). The continued popularity of mobile-bearing products in unicompartmental knee arthroplasty is surprising because, at total knee arthroplasty (TKA), the mobile-bearing variants have lost considerable interest in recent years. Some leading manufacturers no longer offer mobile-bearing derivatives in their TKA product lines.

* Corresponding author. Department of Arthroplasty, München Klinik Neuperlach, Oskar-Maria-Graf-Ring 51, 81737 Munich, Germany. Tel.: +49 151 21083727.

E-mail address: heinz.roettinger@hotmail.com

In addition to good kinematic properties [1,2], the implant has long-term durable outcomes free from revision. Ten-year survival rates of 93%–97% are regularly recorded [3–9].

The main reasons for revision are most often the progression of osteoarthritis on the lateral knee joint, followed by inlay dislocations, loosening, and nonspecific pain [3–6]. These persistently registered nonspecific aches are not further clarified.

In recent years, we diagnosed in our arthroplasty center several cases of anterior knee pain after MB-UKA implantation in the operated medial compartment, which, in our opinion, showed an implant-specific anterior impingement. However, there is no concrete evidence of the occurrence of this anterior impingement throughout the literature. The Oxford Phase III knee surgical instruction points out this potential complication very frankly [10]. In the following sections, we present the history, clinical presentation, and radiological features of our 14 patients with anterior impingement after MB-UKA. This report is the first case series to describe this form of pain and impingement with MB-UKA.

Material and methods

This monocentric retrospective observational study describes our diagnostic and treatment experiences in 14 patients with chronic, acute anteromedial knee pain after MB-UKA implantation in external clinics, coming to our center from 2016 to 2020. Table 1 summarizes the clinical parameters of the patients diagnosed with anterior impingement after MB-UKA. This report includes 10 female and 4 male patients with an average age of approximately 61 years (minimum 47 years, maximum 80 years). The average time from MB-UKA implantation to the diagnosis of anterior impingement was 43.8 months (range 7–86 months). Twelve patients complained of anterior knee pain directly since the prosthesis implantation. In 2 patients, complaints in the anterior medial knee joint changed to an initial painless interval. Differential diagnosis excluded other implant failures such as loosening of the implants, lateral impingement, progressive osteoarthritis in the joint's untreated compartments, severe deviations in the mechanical axis, implant malposition, instability, infection, presence of underlying rheumatic disease, and other conditions in which arthritic irritations appear like tendinitis, Gout arthritis, etc. Every patient's medical record included an extensive medical history, a detailed clinical examination, a standing radiograph in 2 planes, and a whole-leg anteroposterior radiograph. An additional computer tomography helped exclude other diagnoses in individual cases, such as lateral impingement. Final diagnosis other than anterior impingement led to the exclusion from this observational study.

Due to the small number of patients, statistical causal analysis is inappropriate to establish a cause-and-effect correlation. Nevertheless, there are possible correlations regarding the causes of anterior impingement in MB-UKA.

Ethics and potential conflicts of interest

Ethical review and approval were waived for this study due to the study design. According to the national ethical standards, the 1964 Helsinki declaration, and its later amendments, the study considers all ethical requirements necessary. Before beginning the study, we informed the official Ethics Committee of the Bayerischen Landesärztekammer (Chamber of Bavarian Doctors). We received patients' consent to publish case-relevant data, radiographs, and intraoperative pictures. No additional examination or diagnostic burden on the patients was necessary to perform this report. The reliable anonymization of the data before, during, and after the study was guaranteed throughout.

Results

The typical clinical feature of all patients included in this study was medial anterior knee pain after MB-UKA implantation. Eight patients presented a range of motion (ROM) with complete or even slight hyperextension and flexion of at least 110° and, in 2 more cases, even up to 135°. The 4 patients with ROM restrictions had an extension deficit of 5°–10°, whereas the restricted flexion reached a maximum of 85°. In all patients, the leading clinical sign was a medial anterior knee pain that could be intensified directly at the anterior femoral condyle via local pressure. At the same time, all patients experienced increased pain when fully extended or attempting to hyperextend the knee joint. All cases showed a typical pain at the anterior medial femoral condyle. At the time of the first admission to our clinic, according to the Visual Analog Scale, the average pain level was 7.8 (minimum 6, maximum 9). Following our diagnostic pathway, the “Knee Society Score (KSS)” and the “Knee Injury and Osteoarthritis Outcome Score (KOOS)” were measured. The average score in all patients was 46.6 for KSS (minimum 27, maximum 66) and 51.5 for KOOS (minimum 41, maximum 58), which characterized a poor outcome after UKA.

The implants inserted were precisely analyzed about their positioning and sizing. In the surgical technique guide, the manufacturer recommends the femoral implant be placed in flexion at 10° for the central axis under orientation at the central anchor pin. Twelve patients of our series showed a femoral implant flexion of less than 10° (minimum 0°, maximum 15°). The average flexion position of all

Table 1
Clinical parameters of patients with anterior impingement after MB-UKA.

Pat. No.	Gender	Age at revision	Months after primary surgery	VAS	Femur implant flexion degree	Tibia posterior slope degree	Function extension	Function flexion	KOOS	KSS
1	f	64	41	8	0	13	–5	130	45	48
2	f	47	27	9	5	8	0	135	52	63
3	f	56	21	7	10	10	–10	85	49	27
4	f	48	7	10	5	9	–5	95	41	34
5	f	80	62	8	8	8	0	130	49	54
6	m	67	86	6	15	11	0	110	51	51
7	m	63	69	8	8	9	0	130	49	49
8	m	58	12	7	8	15	0	130	54	30
9	f	61	42	8	3	9	0	100	55	62
10	f	60	51	7	11	13	–10	135	58	39
11	f	66	76	6	5	11	0	115	48	61
12	m	61	69	8	7	10	–5	120	57	38
13	f	59	28	8	4	9	0	85	55	48
14	f	60	22	9	5	9	0	115	58	45

f, female; m, male; VAS, Visual Analog Scale.

the femoral implants was 6.8° . The lateral view of the radiographs showed a more or less pronounced indentation at the femur condyle directly anterior to the implant anchorage. This indentation is typical of the implant and results from the specific design and biomechanical characteristics of the Oxford Phase III knee (Fig. 1).

Following the surgical instruction, the regular angle of the tibial implant posterior slope should be 7° . We measured in our 14 patients an average tibial implant posterior slope of 10.2° (minimum 6° , maximum 15°) (Fig. 2). No signs of implant loosening existed in all patients on the femoral and tibial sides.

Intraoperatively in all our cases, we analyzed the individual biomechanical process and noted the movement and interaction of the implant components. At full knee extension, the medial inlay showed a deep impression on the anterior femoral condyle in all our cases. Sometimes it even wholly disappeared with its anterior part in the femoral condyle's indentation mentioned above (Fig. 3a and b). The deformation of the inlay's anterior rim confirms its forceful contact with the bone in these cases (Fig. 4a). In extension and flexion, the inlay was in an accentuated posterior position on the tibial baseplate (Fig. 4b and c). However, during the operation, an increased tibial implant posterior slope or the deviation in the femoral component flexion detected in the preoperative radiograph was not recognizable.

All 14 patients were treated by removing the MB-UKA and changing to a complete TKA. In 4 cases, the extended medial bone defect on the tibial side had to be bridged using modular augments combined with a standard modular revision implant. Patients with increased tibial implant posterior slope needed this medial tibial bone defect bridging (Fig. 5). Thanks to the bone-saving femoral component design of the Oxford Phase III knee, the slight bone defect after removing the femoral implant afforded no additional defect repair or augmentation.

The revision intervention with the change to a complete bicompartamental knee arthroplasty led to a satisfying outcome without complications. All patients were free of complaints after completing full rehabilitation. After 12 months, all 14 patients were

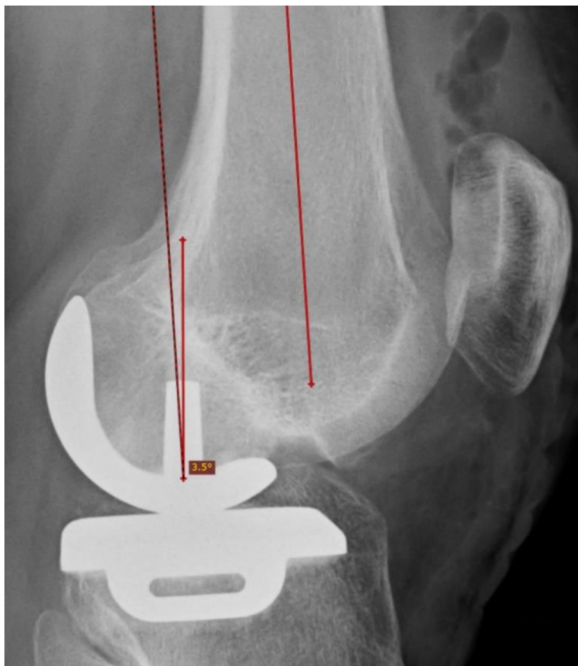

Figure 1. Typical indentation at the femoral condyle in the anterior aspect of the implant. Femoral component in 3.5° flexion for the central axis under orientation at the central anchor pin.

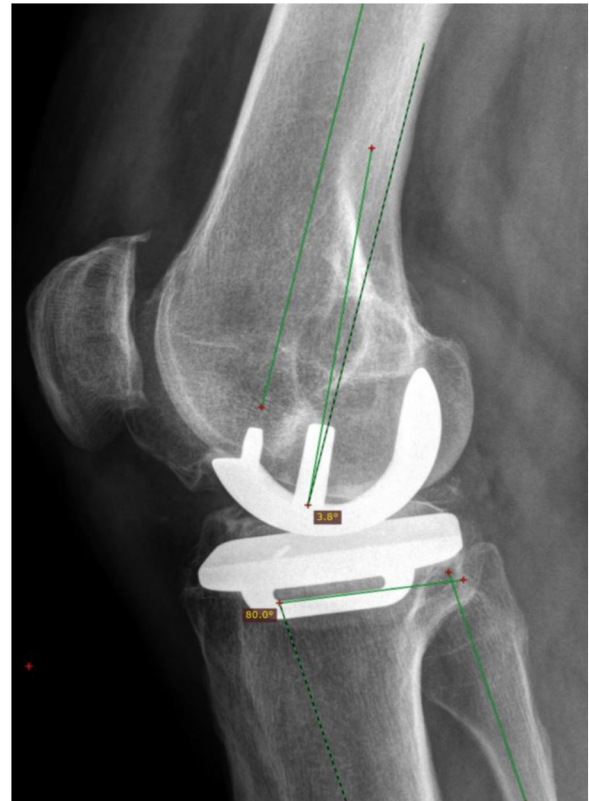


Figure 2. Posterior tibial slope 10° ; femoral component in 3.8° flexion.

satisfied with the regular postoperative follow-up and would have the procedure again. At the 12-month follow-up, the average Visual Analog Scale score was 1.8 (minimum 0, maximum 4), and the average KOOS and KSS scores were 86 (minimum 75, maximum 92) and 82 (minimum 72, maximum 92), respectively. Further revision interventions have not been necessary so far.

Discussion

The present report describes a design-immanent problem of the MB-UKA, which is not represented in the literature.

Due to its unique biomechanical design, the Oxford MB-UKA has always provoked a lively and controversial discussion. Over an observational period of 10 years and more, convincing long-term results with a survival rate of 93%–97% are attributed to the implant [7–9,11,12]. In contrast, some reports show a 10-year survival rate of only 83%–89% [10,13–16].

Throughout all studies, the leading reason for a revision in MB-UKA is not connected with the prosthesis itself but with the arthritic progression on the knee joint's lateral side. In a systematic review evaluating 15 studies with a total of 8658 UKA, 1.42% of the revisions are due to the progression of the osteoarthritis in the lateral joint compartment, followed by implant loosening with an incidence of 1.28%. This study determines a 10-year survival rate of 93% and a 15-year survival rate of 89% for the Oxford Phase III knee [5]. Also, in other studies, osteoarthritis in the lateral joint compartment is the most common reason for the revision in MB-UKA [17]. An important implant-specific reason for revision is the mobile polyethylene inlay, which shows a 0.6%–3.4% dislocation risk [3,6,8,11,18–23].

Another reason for revision with a frequency of 0.6%–2% is classified in numerous studies as “unknown” or “nonspecific pain”

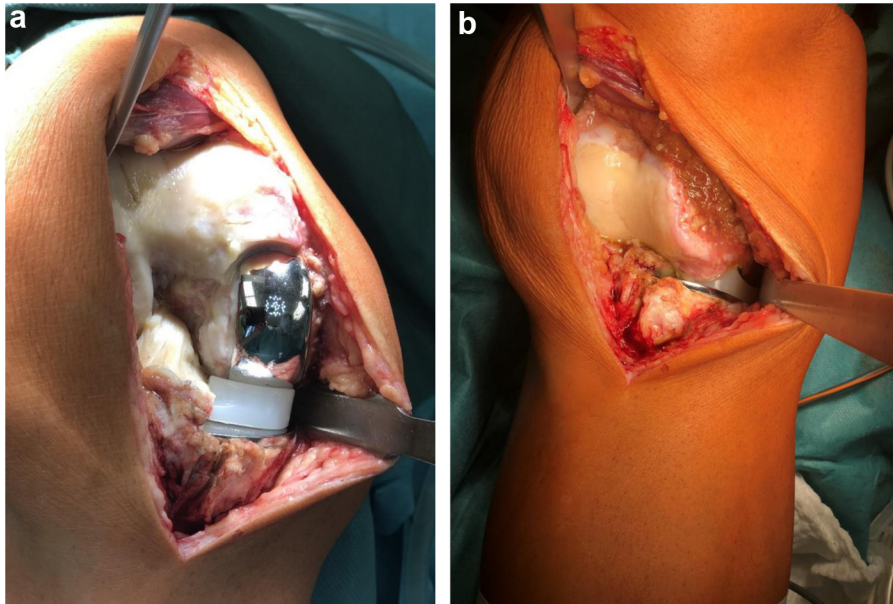


Figure 3. Deep impression of the inlay into the femur condyle anterior to the femoral implant (a). Anterior implant impression in knee extension (b).

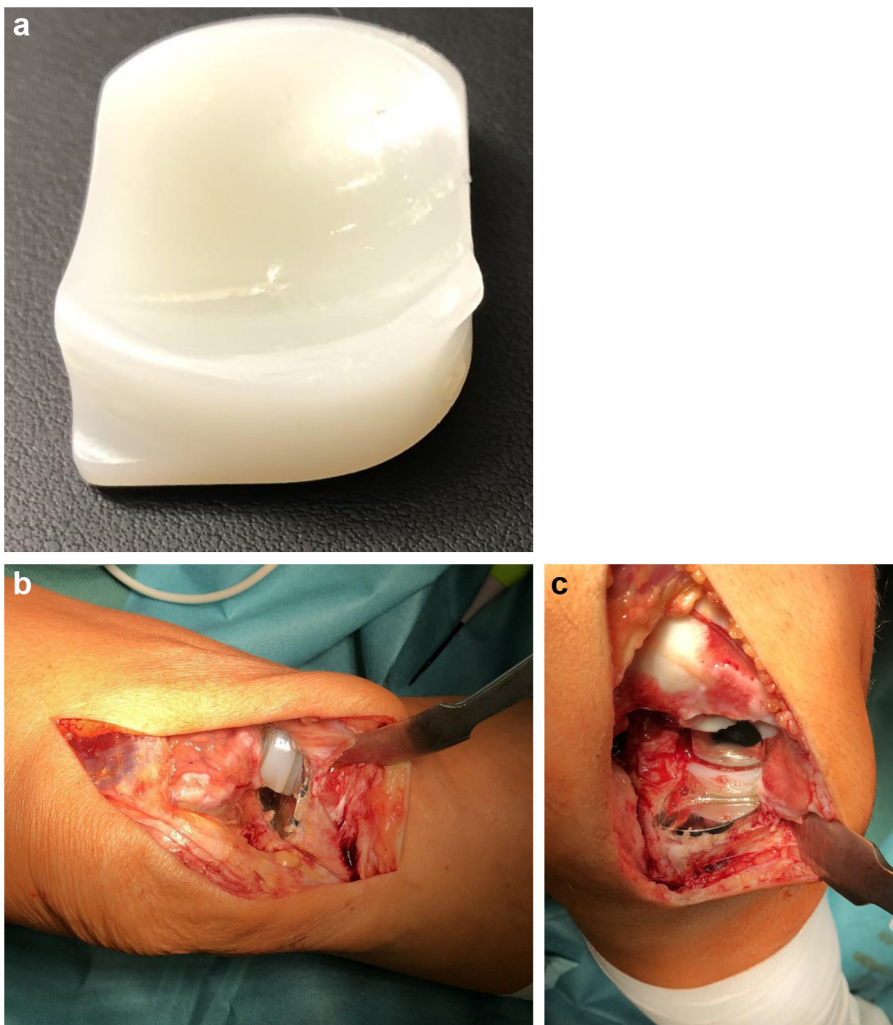

Figure 4. (a) Anterior medial deformation of the inlay. (b and c) Extreme posterior position of the inlay in extension and flexion.

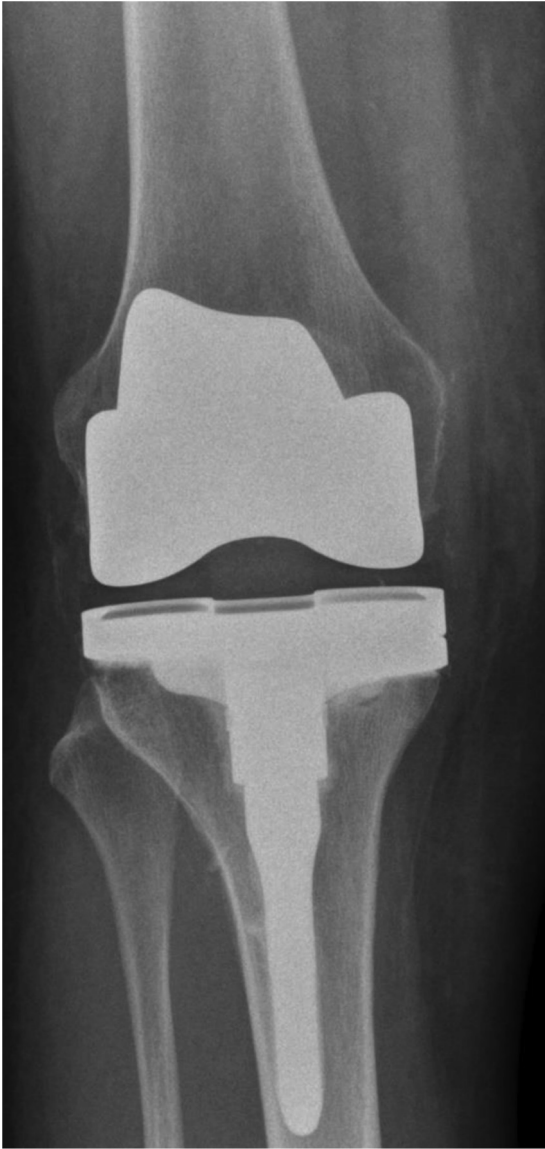

Figure 5. Postoperative radiograph: standard modular tibial revision implant with medial augmentation to bridge the deep bone defect.

[6,11,13,18,24]. What is hidden behind this label “unknown” or “nonspecific pain” stays unclear.

The unique design with the highly constrained contact between the mobile inlay and the femoral component in MB-UKA requires accurate alignment and size selection of the implant. Inaccuracies in surgical execution increase the risk of different complications, including anterior impingement [25]. Interestingly, a few years ago, the manufacturer of the Oxford MB-UKA supplemented the instrument set with a special reamer to insert the anterior notch on the femur in a reliable and standardized manner (Art. No. 32-423,238 and 32-423,239; Zimmer -Biomet, Warsaw, IN). However, there is no evidence of a clinical occurrence of problems or complications caused by the femoral notch in the extensive literature. After implantation of an MB-UKA, 14 patients were admitted with chronic anterior knee pain and symptoms of an anterior impingement to our center during the last 5 years.

The knee joints were systematically examined to exclude the known causes of failure after MB-UKA. An additional computer

tomography gave further information for evaluation in case of difficult differential diagnosis or to clarify lateral impingement [26].

The reasons resulting in an anterior impingement are multifactorial and most likely related to the surgical technique and the implant positioning. The leading symptom in our patients was chronic anterior pain at the medial femoral condyle, which typically increased with full knee extension or when attempting hyperextension. This anterior knee pain is very often attributed to the femoropatellar joint [24,27,28]. However, the patellar contact pressure in the femoropatellar joint is very low during full knee extension or even hyperextension. The femoropatellar joint would instead be assumed to cause anterior knee pain when the knee flexes from 15° and more.

Intraoperatively the relative implant movements were analyzed precisely. During our revision surgery, we could observe 2 conspicuous features: On the one hand, the polyethylene slide disappeared entirely in the anterior femoral notch in full extension, and on the other hand, during the entire movement, the inlay was never in the middle area of the tibia baseplate but exclusively in a posterior position.

The proximal surface of the mobile tibial inlay is constrained connected to the fixed femoral implant. The femoral implant thus clearly determines the mediolateral and the anterior-posterior position of the slide over the entire ROM. The choice of the femoral implant size defines the anterior-posterior position of the tibial inlay in extension. If there is a choice between different femoral sizes intraoperatively, a dorsal position of the tibial inlay in extension is expected with smaller sizes. Larger implants lead to a more central and comparatively more anterior loading of the tibial implant. The surgical instructions do not mention this significant effect of the femoral implant sizing on the position of the tibial inlay in joint extension. Following the “Oxford Partial Knee-Surgical Instructions (Zimmer-Biomet, Warsaw, IN, 2019) page 5, the medium femoral implant size seems a universal application: “If there is doubt between small/medium or medium/large, it is usually best to use the medium” [25]. Even in the abundant literature on the Oxford MB-UK, there is no evidence of the relationship between femoral implant size and biomechanical effects on tibial inlay position.

On the other hand, there is evidence that a posterior inlay position impacts the functional outcome. A consecutive study of 150 patients with Oxford Phase III implants found significantly worse Oxford knee scores in cases with the posterior positioning of the inlay [29]. Another observation is also suspected to be related to the size of the inserted femoral implant: Few studies indicate a gender-specific difference in clinical outcomes after MB-UK. The clinical results seem slightly better in male patients than in female patients [15,30,31].

There are recommendations from the manufacturer that characterize the preferential positions of the femoral and tibial implants. Our small group with an anterior impingement in MB-UKA found an average tibial implant posterior slope of 10.2°. The manufacturer recommends an implant posterior tibial slope of 7° [25]. A study with 246 implantations measured an average angle of 5.5° [20]. Another retrospective study with 228 consecutive MB-UKAs registered an average tibial slope of 1.6°, with the standard deviation of 1.3° [22].

The manufacturer defines the desired flexion position of the femoral component at 10°. Our patient group missed this ideal implant position with an average femur flexion angle of 6.8°. From a biomechanical point of view, a lower flexion angle would require a deeper femoral notch. This correlation is consistent with a study showing a positive influence of a deeper notch on the subsequent clinical outcome [32].

The effects of deviations concerning the recommended implant position have not been comprehensively elaborated in the

literature. The surgical technique brochure only defines a harmless tolerance range for the individual implant positions. There is no information on the effects of multivariate deviation of the implant positions outside the recommended ideal positions and their mutual influence on the tolerance ranges.

Our report's patients showed small but multiple deviations from the standard recommendations regarding implant positioning. The combination of an increased tibial implant posterior slope and a femoral implant in a reduced flexion position, probably also the use of a small femoral implant, looks noticeable.

Our patients with chronic anterior impingement after MB-UKA were treated by revision surgery with a change to TKA. Our experience after revision of anterior impingement in MB-UKA with exchange to a TKA is consistently positive. In some cases, a deepened medial tibial defect needed the bridging with an additional augmentation.

Since its introduction, a sophisticated surgical technique has always been attributed to the Oxford knee, requiring more experience from the surgeon than other implants. The Swedish Knee Arthroplasty Register has highlighted this in its 2004 annual report [33]. The results for the Oxford knee were comparable to those of other UKAs on average but showed a remarkably high confidence interval. This annual report indicates that surgeons with a yearly implantation frequency of over 23 cases reproducibly achieve significantly better results than surgeons with less than 23 knees a year. A meta-analysis evaluating 46 studies with 12,520 knees also shows the relationship between the yearly revision risk of Oxford Phase III knee and the surgeon's experience [14]. The lowest revision rate was observed in patients whose surgeons operate more than 24 MB-UKAs per year, and the surgeons' share of operations with implantation of an MB-UKA accounts for more than 30% of his total annual volume.

This report addresses a potential problem that is most likely specific to the use of MB-UKA. There is much evidence and simplified biomechanical considerations for the occasional occurrence of an anterior impingement with MB-UKA. So far, no reports about anterior impingement in MB-UKA are available, neither in the literature nor from the manufacturer. It can be assumed that anterior impingement in MB-UKA has multifactorial causes. The effects of gross implant positioning outside the recommended tolerance range are known and described. The impact of multiple minor deviations from the manufacturer's recommendations has not been worked out so far. The present small observational study is intended to indicate the existence of this problem. Reliable statements on the possible impact of multivariate variables on the operation outcome are not permissible here. Further studies should address this supposed problem in a clarifying manner.

Summary

The MB-UKA has a design-immanent risk regarding the occurrence of anterior impingement. Previous studies and clinical reports do not describe this problem. We attribute the problems of 14 patients to this anterior impingement after MB-UK. The combination of minor deviations in implant positioning might trigger the problem. When implanting an MB-UKA, the surgeon should be aware of this potential risk.

Conflicts of interest

The authors declare there are no conflicts of interest.

For full disclosure statements refer to <https://doi.org/10.1016/j.artd.2022.06.019>.

Informed patient consent

The author(s) confirm that written informed consent has been obtained from the involved patient(s) or if appropriate from the parent, guardian, power of attorney of the involved patient(s); and, they have given approval for this information to be published in this article.

References

- [1] Heyse TJ, El-Zayat BF, De Corte R, Chevalier Y, Scheys L, Innocenti B, et al. UKA closely preserves natural knee kinematics in vitro. *Knee Surg Sports Traumatol Arthrosc* 2014;22:1902–10.
- [2] Wiik AV, Manning V, Strachan RK, Amis AA, Cobb JP. Unicompartamental knee arthroplasty enables near normal gait at higher speeds, unlike total knee arthroplasty. *J Arthroplasty* 2013;28(9 Suppl):176–8.
- [3] Campi S, Pandit H, Hooper G, Snell D, Jenkins C, Dodd CAF, et al. Ten-year survival and seven-year functional results of cementless Oxford unicompartmental knee replacement: a prospective consecutive series of our first 1000 cases. *Knee* 2018;25:1231–7.
- [4] van der List JP, Zuiderbaan HA, Pearle AD. Why do medial unicompartmental knee arthroplasties fail today? *J Arthroplasty* 2016;31:1016–21.
- [5] Mohammad HR, Strickland L, Hamilton TW, Murray DW. Long-term outcomes of over 8,000 medial Oxford phase 3 unicompartmental knees—a systematic review. *Acta Orthop* 2018;89:101–7.
- [6] Kim KT, Lee S, Lee JI, Kim JW. Analysis and treatment of complications after unicompartmental knee arthroplasty. *Knee Surg Relat Res* 2016;28:46–54.
- [7] Alnachoukati OK, Barrington JW, Berend KR, Kolczun MC, Emerson RH, Lombardi Jr AV, et al. Eight hundred twenty-five medial mobile-bearing unicompartmental knee arthroplasties: the first 10-year US multi-center survival analysis. *J Arthroplasty* 2018;33:677–83.
- [8] Campi S, Pandit HG, Oosthuizen CR. The Oxford medial unicompartmental knee arthroplasty: the South African experience. *J Arthroplasty* 2018;33:1727–31.
- [9] Edmondson M, Atrey A, East D, Ellens N, Miles K, Goddard R, et al. Survival analysis and functional outcome of the Oxford unicompartmental knee replacement up to 11 years follow up at a District General Hospital. *J Orthop* 2015;12(Suppl 1):S105–10.
- [10] Kristensen PW, Holm HA, Varnum C. Up to 10-year follow-up of the Oxford medial tibial knee arthroplasty—695 cases from a single institution. *J Arthroplasty* 2013;28(9 Suppl):195–8.
- [11] Pandit H, Hamilton TW, Jenkins C, Mellon SJ, Dodd CAF, Murray DW. The clinical outcome of minimally invasive Phase 3 Oxford unicompartmental knee arthroplasty. *Bone Joint J* 2015;97-B:1493–9.
- [12] Hamilton TW, Rizkalla JM, Kontochristos L, Marks BE, Mellon SJ, Dodd CAF, et al. The interaction of caseload and usage in determining outcomes of unicompartmental knee arthroplasty: a meta-analysis. *J Arthroplasty* 2017;32:3228–3237.e2.
- [13] Vorlat P, Putzeys G, Cottenie D, Van Isacker T, Pouliart N, Handelberg F, et al. The Oxford unicompartmental knee prosthesis: an independent 10-year survival analysis. *Knee Surg Sports Traumatol Arthrosc* 2006;14:40–5.
- [14] Emerson RHJ, Higgins LL. Unicompartmental knee arthroplasty with the Oxford prosthesis in patients with medial compartment arthritis. *J Bone Joint Surg Am* 2008;90:118–22.
- [15] Liddle AD, Judge A, Pandit H, Murray DW. Determinants of revision and functional outcome following unicompartmental knee replacement. *Osteoarthritis Cartilage* 2014;22:1241–50.
- [16] Schroer WC, Barnes CL, Diesfeld P, LeMarr A, Ingrassia R, Morton DJ, et al. The Oxford unicompartmental knee fails at a high rate in a high-volume knee practice. *Clin Orthop Relat Res* 2013;471:3533–9.
- [17] Clark M, Campbell DG, Kiss G, Dobson PJ, Lewis PL. Reintervention after mobile-bearing Oxford unicompartmental knee arthroplasty. *Clin Orthop Relat Res* 2010;468:576–80.
- [18] Uzun E, Misir A, Kizkapan TB, Ozcamdalli M, Gunay AE, Husrevoglu K. Mid-term functional, clinical, and radiological outcomes with factors affecting revision of mobile-bearing medial unicompartmental knee arthroplasty. *Knee* 2020;27:527–34.
- [19] Epinette JA, Brunschweiler B, Merti P, Mole D, Cazenave A, French Society for Hip and Knee. Unicompartmental knee arthroplasty modes of failure: wear is not the main reason for failure: a multicentre study of 418 failed knees. *Orthop Traumatol Surg Res* 2012;98(6 Suppl):S124–30.
- [20] Ji JH, Park SE, Song IS, Kang H, Ha JY, Jeong JJ. Complications of medial unicompartmental knee arthroplasty. *Clin Orthop Surg* 2014;6:365–72.
- [21] Hutt JRB, Sur A, Sur H, Ringrose A, Rickman MS. Outcomes and early revision rate after medial unicompartmental knee arthroplasty: prospective results from a non-designer single surgeon. *BMC Musculoskelet Disord* 2018;19:172.
- [22] Panzram B, Mandery M, Reiner T, Gotterbarm T, Schiltenswolf M, Merle C. Cementless Oxford medial unicompartmental knee replacement—clinical and radiological results of 228 knees with a minimum 2-year follow-up. *J Clin Med* 2020;9:1476.
- [23] Robertsson O, Lidgren L, Sundberg M, W-Dahl A. The Swedish knee arthroplasty register - annual report 2019. Lund: Media-Tryck; 2020.

- [24] Anagnostakos K, Lorbach O, Kohn D. Patella baja after unicompartmental knee arthroplasty. *Knee Surg Sports Traumatol Arthrosc* 2012;20:1456–62.
- [25] Biomet Z. Oxford partial knee. Microplasty instrumentation and surgical technique. Warsaw, IN: Zimmer-Biomet; 2019.
- [26] Kamenaga T, Hiranaka T, Takayama K, Tsubosaka M, Kuroda R, Matsumoto T. Adequate positioning of the tibial component is key to avoiding bearing impingement in Oxford unicompartmental knee arthroplasty. *J Arthroplasty* 2019;34:2606–13.
- [27] Liddle AD, Pandit H, Jenkins C, Price AJ, Dodd CAF, Gill HS, et al. Preoperative pain location is a poor predictor of outcome after Oxford unicompartmental knee arthroplasty at 1 and 5 years. *Knee Surg Sports Traumatol Arthrosc* 2013;21:2421–6.
- [28] Neogi DS, Bae JH, Seok CW, Lim HC. Impact of patellar height on unicompartment knee arthroplasty: does patella baja lead to an inferior outcome? *J Orthop Trauma* 2014;15:47–54.
- [29] Wahal N, Gaba S, Malhotra R, Kumar V, Pegg EC, Pandit H. Reduced bearing excursion after mobile-bearing unicompartmental knee arthroplasty is associated with poor functional outcomes. *J Arthroplasty* 2018;33:366–71.
- [30] White SH, Roberts S, Jones PW. The Twin Peg Oxford partial knee replacement: the first 100 cases. *Knee* 2012;19:36–40.
- [31] Burnett RS, Nair R, Hall CA, Jacks DA, Pugh L, McAllister MM. Results of the Oxford Phase 3 mobile bearing medial unicompartmental knee arthroplasty from an independent center: 467 knees at a mean 6-year follow-up: analysis of predictors of failure. *J Arthroplasty* 2014;29(9 Suppl):193–200.
- [32] Dammerer D, Liebensteiner M, Rochau H, Uprimny C, Smekal V, Rosenberger R, et al. Influence of the anterior notch in mobile-bearing UKA on patellofemoral radiotracer uptake and clinical outcome. *BMC Musculoskelet Disord* 2017;18:532.
- [33] Lindgren L, Knutson K, Robertsson O. Swedisch knee arthroplasty register annual report 2004. 2004. p. 6. www.ort.lu.se/knee/.